

## MEDICAL REVIEW

**JOURNAL OF THE SOCIETY OF PHYSICIANS OF VOJVODINA OF THE  
MEDICAL SOCIETY OF SERBIA**  
*THE FIRST ISSUE WAS PUBLISHED IN 1948*

Editor-in-Chief

LJILJA MIJATOV UKROPINA

Assistant to the Editor-in-Chief for Clinical Branches: PETAR SLANKAMENAC

Assistant to the Editor-in-Chief for Imaging Methods: VIKTOR TILL

Assistants to the Editor-in-Chief

SONJA LUKAČ

ŽELJKO ŽIVANOVIĆ

### EDITORIAL BOARD

OKAN AKHAN, Ankara  
ANDREJ ALEKSANDROV, Birmingham  
STOJANKA ALEKSIĆ, Hamburg  
VLADO ANTONIĆ, Baltimor  
ITZHAK AVITAL, Bethesda  
KAREN BELKIĆ, Stockholm  
JEAN-PAUL BEREGI, Lille Cedex  
HELENA BERGER, Ljubljana  
KSENIJA BOŠKOVIĆ, Novi Sad  
VLADIMIR ČANADANOVIĆ, Novi Sad  
IVAN DAMJANOV, Kansas City  
JADRANKA DEJANOVIĆ, Novi Sad  
OMER DEVAJA, Meidstone  
RADOSLAVA DODER, Novi Sad  
PETAR DRVIŠ, Split  
ALEKSANDRA FEJSA LEVAKOV, Novi Sad  
ZORAN GOJKOVIĆ, Novi Sad  
IRENA HOČEVAR BOLTEŽAR, Ljubljana  
DEJAN IVANOV, Novi Sad  
MARIJA JEVTIĆ, Novi Sad  
MARINA JOVANOVIĆ, Novi Sad  
ZORAN KOMAZEC, Novi Sad  
DUŠAN LALOŠEVIĆ, Novi Sad  
JORGE MANUEL COSTA LAINS, Coimbra  
VELJKO MARIĆ, Foča  
VLADIMIR MARTINEK, Bad Aibling  
SINIŠA MASLOVARA, Osijek

LJILJA MIJATOV UKROPINA, Novi Sad  
MIROSLAV MILANKOV, Novi Sad  
OLGICA MILANKOV, Novi Sad  
IGOR MITIĆ, Novi Sad  
NADA NAUMOVIĆ, Novi Sad  
AVIRAM NISSAN, Ein Karem  
JANKO PASTERNAK, Novi Sad  
ĐORĐE PETROVIĆ, Novi Sad  
LJUBOMIR PETROVIĆ, Novi Sad  
TOMISLAV PETROVIĆ, Novi Sad  
MIHAEL PODVINEC, Basel  
JOVAN RAJS, Danderyd  
TATJANA REDŽEK MUDRINIĆ, Novi Sad  
PETAR E. SCHWARTZ, New Haven  
MILAN SIMATOVIĆ, Banja Luka  
TOMAŠ SKRIČKA, Brno  
PETAR SLANKAMENAC, Novi Sad  
EDITA STOKIĆ, Novi Sad  
ALEXANDER STOJADINOVIĆ, Glen Alen  
MILANKA TATIĆ, Novi Sad  
VIKTOR TILL, Novi Sad  
TIBOR TOT, Falun  
TAKASHI TOYONAGA, Kobe  
KONSTANTIN VIKTOROVIĆ SUDAKOV, Moskva  
VIKTORIJA VUČAJ ĆIRILOVIĆ, Novi Sad  
ZORAN VUJKOVIĆ, Banja Luka  
PETAR VULEKOVIĆ, Novi Sad

Proof-reading for English Language: Marija Vučenović

Proof-reading for Serbian Language: Dragica Pantić

Technical Secretary: Vesna Šaranović

Technical Support: "Grafit" Novi Sad

UDC and descriptors prepared by: the Library of the Faculty of Medicine, Novi Sad

---

MEDICAL REVIEW is published bimonthly (six issues per year) with a circulation of 1.000 copies. The annual payment fee in 2022, for individuals from the territory of Serbia, is 3,000.00 dinars (the value-added tax included), 4,000.00 dinars for individuals from Serbia who are not members of the Society of Physicians of Vojvodina of the Medical Society of Serbia, 60 Euros for members outside the territory of Serbia, and 8,000.00 dinars (+ VAT) for institutions. The payment account is: 340-1861-70 or 115-13858-06, "Annual membership fee for Medical Review".

Copyright © Društvo lekara Vojvodine Srpskog lekarskog društva Novi Sad 1998

**The manuscripts are submitted at: [asestant.ceon.rs/index.php/medpreg/](http://asestant.ceon.rs/index.php/medpreg/). Editorial Office Address:  
Društvo lekara Vojvodine Srpskog lekarskog društva, 21000 Novi Sad, Vase Stajica 9,  
Tel. 021/521-096; 063/81 33 875, E-mail: [dlvsldnovisad@gmail.com](mailto:dlvsldnovisad@gmail.com); Website: [www.dlv.org.rs](http://www.dlv.org.rs)**

## MEDICINSKI PREGLED

ČASOPIS DRUŠTVA LEKARA VOJVODINE SRPSKOG LEKARSKOG DRUŠTVA  
PRVI BROJ JE ŠTAMPAN 1948. GODINE.

Glavni i odgovorni urednik  
LJILJA MIJATOV UKROPINA

Pomoćnik urednika za kliničke grane: PETAR SLANKAMENAC  
Pomoćnik urednika za imidžing metode: VIKTOR TILL

Pomoćnici urednika:  
SONJA LUKAČ  
ŽELJKO ŽIVANOVIĆ

### REDAKCIJSKI ODBOR

OKAN AKHAN, Ankara  
ANDREJ ALEKSANDROV, Birmingham  
STOJANKA ALEKSIĆ, Hamburg  
VLADO ANTONIĆ, Baltimor  
ITZHAK AVITAL, Bethesda  
KAREN BELKIĆ, Stockholm  
JEAN-PAUL BEREĞI, Lille Cedex  
HELENA BERGER, Ljubljana  
KSENIJA BOŠKOVIĆ, Novi Sad  
VLADIMIR ČANADANOVIĆ, Novi Sad  
IVAN DAMJANOV, Kansas City  
JADRANKA DEJANOVIĆ, Novi Sad  
OMER DEVAJA, Meidstone  
RADOSLAVA DODER, Novi Sad  
PETAR DRVIŠ, Split  
ALEKSANDRA FEJSA LEVAKOV, Novi Sad  
ZORAN GOJKOVIĆ, Novi Sad  
IRENA HOČEVAR BOLTEŽAR, Ljubljana  
DEJAN IVANOV, Novi Sad  
MARIJA JEVTIĆ, Novi Sad  
MARINA JOVANOVIĆ, Novi Sad  
ZORAN KOMAZEC, Novi Sad  
DUŠAN LALOŠEVIĆ, Novi Sad  
JORGE MANUEL COSTA LAINS, Coimbra  
VELJKO MARIĆ, Foča  
VLADIMIR MARTINEK, Bad Aibling  
SINIŠA MASLOVARA, Osijek

LJILJA MIJATOV UKROPINA, Novi Sad  
MIROSLAV MILANKOV, Novi Sad  
OLGICA MILANKOV, Novi Sad  
IGOR MITIĆ, Novi Sad  
NADA NAUMOVIĆ, Novi Sad  
AVIRAM NISSAN, Ein Karem  
JANKO PASTERNAK, Novi Sad  
ĐORĐE PETROVIĆ, Novi Sad  
LJUBOMIR PETROVIĆ, Novi Sad  
TOMISLAV PETROVIĆ, Novi Sad  
MIHAEL PODVINEC, Basel  
JOVAN RAJS, Danderyd  
TATJANA REDŽEK MUDRINIĆ, Novi Sad  
PETAR E. SCHWARTZ, New Haven  
MILAN SIMATOVIĆ, Banja Luka  
TOMAŠ SKRIČKA, Brno  
PETAR SLANKAMENAC, Novi Sad  
EDITA STOKIĆ, Novi Sad  
ALEXANDER STOJADINOVIĆ, Glen Alen  
MILANKA TATIĆ, Novi Sad  
VIKTOR TILL, Novi Sad  
TIBOR TOT, Falun  
TAKASHI TOYONAGA, Kobe  
KONSTANTIN VIKTOROVIĆ SUDAKOV, Moskva  
VIKTORIJA VUČAJ ČIRILOVIĆ, Novi Sad  
ZORAN VUJKOVIĆ, Banja Luka  
PETAR VULEKOVIĆ, Novi Sad

Lektor za engleski jezik: Marija Vučenović

Lektor za srpski jezik: Dragica Pantić

Tehnički sekretar: Vesna Šaranović

Tehnička podrška: „Grafit“, Novi Sad

Izrada UDK i deskriptora: Biblioteka Medicinskog fakulteta, Novi Sad

---

MEDICINSKI PREGLED izlazi dvomesečno (šest dvobroja godišnje), u tiražu od 1000 primeraka. Pretplata za pojedince sa teritorije Srbije za 2022. godinu iznosi 3.000,00 dinara (sa uračunatim PDV-om), a 4.000,00 dinara za pojedince iz Srbije koji nisu članovi DLV-SLD, 60 eura za članove van Srbije, a za ustanove 8.000,00 dinara (uz dodavanje PDV-a). Uplate se vrše na račun broj 340-1861-70 ili 115-13858-06, s naznakom „Dodatna članarina za Medicinski pregled“.

Copyright © Društvo lekara Vojvodine Srpskog lekarskog društva Novi Sad 1998.

**Prijem rukopisa vrši se u elektronskoj formi na stranici: [aseestant.ceon.rs/index.php/medpreg/](http://aseestant.ceon.rs/index.php/medpreg/).**

**Adresa redakcije: Društvo lekara Vojvodine Srpskog lekarskog društva,**

**21000 Novi Sad, Vase Stajića 9, Tel. 021/521-096; 063/81 33 875**

**E-mail: [dlvslidnovisad@gmail.com](mailto:dlvslidnovisad@gmail.com); Web: [www.dlv.org.rs](http://www.dlv.org.rs)**

---



SADRŽAJ

**ORIGINALNI NAUČNI RADOVI**

- Slavica Đorđević, Snežana Knežević i Nikola Savić  
UTICAJ PANDEMIJE COVID-19 NA VELNES I ZDRAV ŽIVOTNI STIL..... 211-216
- Bojana Markić, Milka Mavija, Saša Smoljanović Skočić i Sanela-Sanja Burgić  
UTICAJ OPERACIJE KATARAKTE NA KRATKOTRAJNE FLUKTUACIJE INTRAOKULARNOG PRITISKA KOD PACIJENATA SA PRIMARNIM ZATVARANJEM UGLA I PRIMARNIM GLAUKOMOM ZATVORENOG UGLA..... 217-223
- Milijana Rakin, Nataša Aničić, Olivera Ivanov, Sanja Jarić, Nemanja Novaković i Ivan Koprivica  
UTICAJ PRIMENE VOLUMETRIJSKI MODULISANE LUČNE RADIOTERAPIJE NA KLINIČKI ISHOD KOD PACIJENTKINJA LEČENIH OD GINEKOLOŠKIH KARCINOMA..... 224-229
- Jovana Marinković i Olivera Tarabar  
MULTIPLI MIJELOMOM I DUBOKA VENSKA TROMBOZA/PLUĆNA TROMBOEMBOLIJA – UČESTALOST I FAKTORI RIZIKA 230-236

**STRUČNI ČLANCI**

- Maša Sladojević, Tanja Šašić Ostojić, Stanislava Nikolić, Željko Živanović, Branislava Ilinčić i Velibor Čabarkapa  
INDEKS TRIGLICERIDA I GLUKOZE KOD PACIJENATA SA MULTIPLIOM SKLEROZOM..... 237-241

**PRIKAZI SLUČAJEVA**

- Vladimir Ivanović, Dragana Dabović, Maja Stefanović, Marija Bjelobrk, Golub Samardžija i Branislav Crnomarković  
REDAK UZROK INFARKTA MIOKARDA – EMBOLIZACIJA KORONARNE ARTERIJE FRAGMENTIMA MIKSOMA..... 243-246
- Daniela Donat, Sonja Lukač, Ivana Bajkin, Ivana Vorgučin, Viktor Till i Slađana Zagorac  
ULTRAZVUK TESTISA KOD KALMANOVOG SINDROMA – PRIKAZ SLUČAJA..... 247-249
- Ana Milenković, Jovan Javorac, Dejan Živanović, Svetlana Kašiković Lečić, Vanja Tovilović i Miroslav Ilić  
TUMOR ILI TUBERKULOZA KIČME – PRIKAZ SLUČAJA I KRATAK PREGLED LITERATURE..... 250-253
- Tijana Koković, Nikola Batinić, Željko Živanović i Viktor Till  
SISTEMSKI EMBOLIJSKI DOGAĐAJI POVEZANI SA PERZISTENTNIM FORAMENOM OVALE – PRIKAZ SLUČAJA..... 254-258
- Jelena Ilić Sabo, Stefan Ivić, Ana Milenković, Milica Trkulja, Vanja Tovilović i Borislav Golijan  
METASTAZA SEMINOMA U KOŠTANU SRŽ PACIJENTA SA KONKOMITANTNIM FOLIKULARNIM NON-HOČKIN LIMFOMOM – PRIKAZ SLUČAJA..... 259-262
- Maja Drljača, Maja Ružić, Daniela Marić, Natalija Rajić, Jelena Đurica i Svetlana Ilić  
PRVI PRIJAVLJENI SLUČAJEVI VIRUSA HEPATITISA A I VIRUSA HUMANE DEFICIJANCIJE U AUTONOMNOJ POKRAJINI VOJVODINI, SRBIJA – PRIKAZ SLUČAJA..... 263-267

- IN MEMORIAM** ..... 269-270



## ORIGINAL STUDIES

### ORIGINALNI NAUČNI RADOVI

University of Kragujevac, Kragujevac  
Faculty of Medical Sciences

Original study  
*Originalni naučni rad*  
UDK 616-036.21:304.35  
UDK 616.98:578.834  
<https://doi.org/10.2298/MPNS2208211D>

## THE IMPACT OF THE CORONAVIRUS DISEASE 2019 PANDEMIC ON WELLNESS AND HEALTHY LIFESTYLE

*UTICAJ PANDEMIJE COVID-19 NA VELNES I ZDRAV ŽIVOTNI STIL*

Slavica ĐORĐEVIĆ, Snežana KNEŽEVIĆ and Nikola SAVIĆ

### Summary

**Introduction.** The main goal of wellness is to promote proactive and preventive behavior that improves mental health and lifestyle. This study examined how the lifestyle of respondents was affected by the inability to visit spas and wellness centers during the coronavirus disease 2019 pandemic. **Material and Methods.** This cross-sectional study included a total of 186 participants with an average age of  $41.31 \pm 10.475$  years, 137 female and 49 male. We specifically designed a questionnaire to analyze the impact of the lack of wellness services during the coronavirus disease 2019 pandemic. **Results.** There was no statistically significant association between gender, age, education, and marital status and visiting wellness destinations. Monthly income, however, showed a statistically significant association with visiting wellness facilities ( $p = 0.002$ ). There was a significant decrease in the use of wellness centers during the coronavirus disease 2019 pandemic. A small number of the respondents believed the coronavirus disease 2019 pandemic has changed their lifestyle. **Conclusion.** The lack of wellness services has affected the respondents' inability to relax and get away from daily life, but the coronavirus disease 2019 pandemic has not negatively changed their lifestyle ( $p = 0.001$ ).

**Key words:** COVID-19; Pandemics; Mental Health; Life Style; Health

### Introduction

Over the past decades, people are more engaged in health and environmental awareness as a result of shifting social perspectives towards health and well-being [1]. Well-being is a multi-dimensional concept that includes ideas of conveniences, personal liberties, choices, state of mind, and abilities [2]. The goal of wellness is to balance and improve significant spheres of humankind, including physical, cognitive, emotional, intellectual, professional, and spiritual. Wellness means a healthy balance

### Sažetak

**Uvod.** Glavni ciljevi velnesa su proaktivno i preventivno ponašanje koje poboljšava mentalno zdravlje i stil života. Ova studija je ispitala kako je na stil života ispitanika uticala nemogućnost posećivanja spa i velnes centara tokom pandemije COVID-19. **Materijal i metode.** Studija je sprovedena kao studija preseka koja je uključila ukupno 186 ispitanika, prosečne starosti  $41,31 \pm 10,475$  godina, 137 žena i 49 muškaraca. Upitnik je posebno osmišljen da bi analizirao Uticaj nedostatka velnes usluga tokom COVID-19 pandemije. **Rezultati.** Nije bilo statistički značajne povezanosti između pola, starosti, obrazovanja i bračnog statusa sa posetama velnesu. Mesečni prihodi su pokazali značajnu razliku ( $p = 0,002$ ). Tokom pandemije COVID-19 došlo je do značajnog smanjenja korišćenja velnesa. Nije bilo značajnog broja ispitanika koji smatraju da im je pandemija COVID-19 promenila stil života. **Zaključak.** Nedostatak velnes usluga uticao je na nemogućnost ispitanika da se relaksiraju i distanciraju od svakodnevnog života, ali pandemija COVID-19 nije negativno promenila njihov stil života ( $p = 0,001$ ).

**Ključne reči:** COVID-19; pandemija; mentalno zdravlje; životni stil; zdravlje

between mind and body that leads to overall well-being [3, 4]. The main goal of wellness customers is to pursue proactive and preventive measures to enhance well-being [5]. Tourist satisfaction is positively associated with their intentions to revisit the wellness destination. Beyond the unique attributes of geothermal water, the wellness features, including landscaping, pool design, the surrounding environment, as well as local plants and biodiversity, are significant drivers [1]. A healthy lifestyle is progressively becoming more integrated into various dimensions of wellness services [6].

**Abbreviations**

COVID-19 - coronavirus disease 2019

The World Health Organization declared a coronavirus disease 2019 (COVID-19) pandemic on March 11, 2020 [7, 8]. In Serbia, the first case of COVID-19 infection was registered on March 6, 2020 [9]. The pandemic arose suddenly and spread quickly and wellness tourists have been disturbed due to the threat to their health. It was also necessary to abruptly adapt to the recommended measures including hand hygiene, mask wearing, and maintaining social distancing. Travel fear, anxiety and decreased travel readiness followed, in order to avoid the possibility of contracting the new coronavirus [10].

The aim of this research was to examine how the lifestyle of respondents was affected by the inability

to visit spas and wellness centers during the COVID-19 pandemic.

**Material and Methods**

The study was conducted as a quantitative study. The instrument was an online questionnaire consisting of two parts. The concept of the questionnaire was based on the researches of Mak et al. (2009), Clark-Kennedy et al. (2017), and Chen et al. (2014) [1, 2, 11]. The first part of the questionnaire included information on sociodemographic characteristics of the respondents, while those who do not visit wellness destinations were excluded from the study. The second part included questions/answers on the attitudes to lifestyle changes due to the COVID-19 pandemic.

**Table 1.** Sociodemographic characteristics of the respondents**Tabela 1.** Sociodemografski parametri ispitanika

Sociodemographic characteristics/Sociodemografske karakteristike (N/Br=186)	f	%
<b>Gender/Pol</b>		
Female/Ženski	137	73.7
Male/Muški	49	26.3
<b>Age/Starost*</b>		
</= 24	6	3.2
25 - 30	30	16.1
31 - 36	25	13.4
37 - 42	37	19.9
43 - 48	27	14.5
49 - 54	42	22.6
55 - 60	16	8.6
61+	3	1.6
<b>Education/Obrazovanje</b>		
Primary school/Osnovna škola	1	0.5
High school/Srednja škola	55	29.6
Faculty/Fakultet	108	58.1
Graduate studies/Postdiplomske studije	22	11.8
<b>Monthly income/Mesečni prihodi</b>		
Under 30.000 dinars/Ispod 30.000 dinara	17	9.1
30.000 - 50.000 dinars/dinara	33	17.7
50.000 - 100.000 dinars/dinara	83	44.6
More than 100.000 dinars/Više od 100.000 dinara	23	12.4
I do not want to answer/Ne želim da se izjasnim	30	16.1
<b>Marital status/Bračni status</b>		
Unmarried/Neoženjen/neudata	84	45.2
Married/Oženjen/udata	102	54.8
<b>Do you visit wellness resorts/Da li posećujete velnes destinacije?</b>		
Yes/Da	109	58.6
No/Ne	77	41.4
*AS ± SD (Min-Max)		

Continuous variables were expressed as p-values and medians, as a measure of central tendency. Categorical variables were expressed as absolute numbers and percentages. The Pearson  $\chi^2$  (chi-square) test was used to examine the correlation between two variables. To examine the differences in the frequency of visiting wellness centers before and during the pandemic, the marginal homogeneity test was used for polytomous variables. For certain answers, a five-point Likert scale was used ranging from: 1 – strongly disagree; 2 – partially disagree; 3 – neither agree nor disagree; 4 – partially agree; 5 – completely agree. The software package SPSS was used for statistical analysis and calculation. The questionnaire was distributed in the period from 25 to 31 December 2021. The survey was conducted in Serbian language in Serbia.

## Results

The sociodemographic characteristics of the respondents are shown in **Table 1**.

We analyzed the differences in the popularity of wellness centers in regard to sociodemographic characteristics of the respondents (**Table 2**).

The results of testing the frequency of wellness visits in regard to sociodemographic characteristics showed a statistically significant difference only in monthly income of respondents ( $p = 0.002$ ).

The **Table 3** shows that the lack of wellness services had the greatest impact on stress and escape from everyday life, and the least impact on fun and socializing ( $p = 0.001$ ).

Most of the respondents (34 - 31.2%) completely agreed that the COVID-19 pandemic significantly

**Table 2.** The difference in popularity of wellness centers  
*Tabela 2. Razlika u popularnosti velnes centra*

Do you visit wellness resorts? <i>Da li posećujete velnes turističke destinacije?</i>		Yes/Da	No/Ne	$\chi^2$	df	p/p
Gender <i>Pol</i>	Female/Ženski	84 (61.3%)	53 (38.7%)	1.576	1	0.209
	Male/Muški	25 (51%)	24 (49%)			
Age <i>Starost</i>	Millennials/Milenijalci	45 (60%)	30 (40%)	0.10 1	1	0.750
	Others/Ostali	64 (57.7%)	47 (42.3%)			
Education <i>Obrazovanje</i>	Primary school/Osnovna škola	28 (50%)	28 (50%)	2.55 7	2	0.278
	High school/Srednja škola	68 (63%)	40 (37%)			
	Graduate studies Postdiplomske studije	13 (59.1%)	9 (40.9%)			
Monthly income <i>Mesečni prihodi</i>	To the 30.000 dinars/Ispod 30.000 dinara	10 (58.8%)	7 (41.2%)	15.1 57**	3	0.002
	30.000 - 50.000 dinars/dinara	10 (30.3%)	23 (69.7%)			
	50.000 - 100.000 dinars/dinara	55 (66.3%)	28 (33.7%)			
	More than 100.000 dinars Više od 100.000 dinara	17 73.9%	6 26.1%			
Marital status <i>Bračni status</i>	Unmarried/Neoženjen/neudata	50 (59.5%)	34 (40.5%)	0.054	1	0.817
	Married/Oženjen/udata	59 (57.8%)	43 (42.2%)			

**Table 3.** Lack of wellness services due to the COVID-19 pandemic  
*Tabela 3. Izostanak wellness usluga zbog pandemije COVID-19*

Lack of wellness has affected: <i>Izostanak velnes usluga je uticao na:</i>	N <i>Br.</i>	Mean <i>Prosek</i>	Std. Deviation <i>Standardna devijacija</i>	Mean Rank <i>Prosečan rang</i>	$\chi^2$	df	p/p
Fun and socializing/Zabavu i druženje	109	2.98	1.394	2.70	18.003 <sup>a</sup>	4	0.001
Hedonism and a luxurious experience <i>Hedonizam i doživljaj luksuznog iskustva</i>	109	3.02	1.381	2.88			
I don't feel healthier or happier <i>Da se ne osećam zdravije i srećnije</i>	109	3.17	1.261	2.96			
I can't get rid of stress and get away from everyday life/Da ne mogu da se oslobodim stresa i da pobegnem od svakodnevice	109	3.35	1.279	3.27			
My overall physical and mental health <i>Moje opšte fizičko i mentalno zdravlje</i>	109	3.33	1.195	3.20			

a. Friedman Test



**Table 4.** Opinions on the COVID-19 pandemic and lifestyle changes  
**Tabela 4.** Stav o pandemiji COVID-19 i promeni načina života

The pandemic has significantly changed my lifestyle/ <i>Pandemija je značajno promenila moj životni stil</i>	f	%
I completely agree/ <i>Slažem se u potpunosti</i>	34	31.2
I partially agree/ <i>Delimično se slažem</i>	19	17.4
I neither agree nor disagree/ <i>Nemam stav</i>	15	13.8
I partially disagree/ <i>Delimično se ne slažem</i>	24	22.0
I do not agree at all/ <i>Uopšte se ne slažem</i>	17	15.6
In total/ <i>Ukupno</i>	109	100.0

**Table 5.** Wellness travel before and during the COVID-19 pandemic  
**Tabela 5.** Velnes putovanja pre i tokom pandemije COVID-19

How often have you visited wellness resorts?/ <i>Koliko redovno ste koristili usluge velnes turizma</i>	Before the pandemic		During the pandemic		Marginal homogeneity test <i>Test marginalne homogenosti</i>
	<i>Pre pandemije</i>		<i>Tokom pandemije</i>		
	f	%	f	%	
Once a week/ <i>Jednom nedeljno</i>	2	1.8	2	1.8	Std. MH Statistic/ <i>MH stand. statistika</i>
Once a month/ <i>Jednom mesečno</i>	10	9.2	3	2.8	
Several times a year <i>Nekoliko puta godišnje</i>	69	63.3	15	13.8	-8.356
Once a year/ <i>Jednom godišnje</i>	28	25.7	22	20.2	p/p (2-tailed)/( <i>dvostrana</i> )
Never/ <i>Nijednom</i>	0	0.0	67	61.5	0.000
In total/ <i>Ukupno</i>	109	100.0	109	100.0	

changed their lifestyle (Table 4), but the Chi-square test showed no statistically significant difference.

We analyzed whether there were differences in wellness travel before and during the COVID-19 pandemic (Table 5).

The above-mentioned results showed a significant reduction in wellness visits during the COVID-19 pandemic.

## Discussion

The results of testing the popularity of wellness centers in regard to sociodemographic characteristics showed a statistically significant difference only in monthly income of the respondents. Age, gender, marital status, and education did not show a statistically significant difference in regard to the frequency of visiting wellness centers. These results indicate that there was a significant reduction in the use of wellness services during the COVID-19 pandemic. Lack of wellness services had the greatest impact on the respondents' inability to get rid of stress and escape from everyday life, and the least impact on fun and socializing. The COVID-19 pandemic did not change the participants' lifestyle.

The coronavirus outbreak has increased people's physical vulnerability, disturbing the socially accepted paradigm of modern life [12]. According to Wenn, the COVID-19 pandemic had an impact on the rising popularity of independent and free travel, including health and wellness tourism [13]. Fresh air was considered to be a preventive

measure aimed to improve health and reduce the mortality rate.

Our results are in agreement with the results of several published studies. Clark-Kennedy et al. (2017), indicated that the majority of wellness visitors were motivated by relaxation (99%), feeling absolute peace (95%), joy (88%), escapism (86%), overall health advantages (77%) and a connection with nature (74%) [1]. In a Hong Kong study, the most significant motivating factors were leisure, relaxation, escapism, self-reward, hedonism, and esthetics [1, 11]. The impact of wellness on the quality of life and well-being is one of the key aspects [14]. The experience of wellness affects the visitor's satisfaction during free time, and beyond that time, contributes the perception of the overall quality of life [15]. In a study by Voigt et al., 61% of respondents were university educated [16]. Our results are in line with the mentioned study (58.1%). Wellness-related lifestyle includes physical, psychological, social, and spiritual dimensions of health [17]. Iso-Ahola et al. (1982) stated that tourists search for personal escape, interpersonal escape, and interpersonal seeking, and we agree [18]. The concept of well-being in tourist destinations is focused on the psychological, spiritual, and social effects [19]. Crompton (1979) places the concept of travel motives in a socio-psychological-cultural continuum [20]. Individuals visiting wellness centers have a proactive intention to improve their health by acting preventively [21]. Wellness users feel responsible for their health, so their lifestyle includes

physical activity, healthy diet, relaxation, mindfulness, cosmetic care, enhanced mental activity, and social interaction [22]. Terme Olimia offers a program called selfness. This innovative concept is based on establishing the harmony of body and mind. Selfness therapy improves the quality of life and relaxation [23, 24]. Paying more attention to psychological factors in the assessment of medical conditions can improve the healthcare [25].

Findings demonstrated that well-being can boost the body's immunological response [26]. When the immune system operates in harmony and balance, it is protected from outside threats, and supported by healthy lifestyle decisions it promotes holistic immunity [24]. Immunity is a key factor against viral diseases, so we can conclude that the paradoxical measures applied due to the coronavirus pandemic, led to avoiding wellness and inadequate immune response.

There are some limitations in our study. Given the sample, it should be emphasized that the study was conducted by random sampling and therefore our conclusions do not apply to the entire Serbian population. It is possible that participants were more interested than the typical person in improv-

ing their health and spending more on various spa and wellness activities, given the way the data were gathered and the present epidemiological crisis caused by the pandemic. Only those who could afford a wellness retreat were evaluated in the study, and as a result, only their opinions were considered. The questionnaire was made to prevent the respondents to voice their personal views through open questions, so they were not included in the questionnaire. Finally, the results should be interpreted cautiously due to the study sample size and the fact that there were more female than male respondents [24–26].

### Conclusion

The findings of our study revealed there was a significant decrease in the use of wellness services during the coronavirus disease 2019 pandemic. The coronavirus disease 2019 pandemic significantly affected the overall sense of well-being. The lack of wellness services had the greatest impact on the respondents' inability to relax and get away from everyday life, but the coronavirus disease 2019 pandemic has not negatively changed their lifestyle.

### References

1. Clark-Kennedy J, Cohen M. Indulgence or therapy? Exploring the characteristics, motivations and experiences of hot springs bathers in Victoria, Australia. *Asia Pacific Journal of Tourism Research*. 2017;22(5):501-11.
2. Chen KH, Chang FH, Tung KX. Measuring wellness-related lifestyles for local tourists in Taiwan. *Tourism Analysis*. 2014;19(3):369-76.
3. Mueller H, Kaufmann EL. Wellness tourism: market analysis of a special health tourism segment and implications for the hotel industry. *Journal of Vacation Marketing*. 2001;7(1):5-17.
4. Smith M, Kelly C. Wellness tourism. *Tourism Recreation Research*. 2006;31(1):1-4.
5. Global Wellness Summit. Past Global Wellness Summits [Internet]. 2010 [cited 2021 Jun 15]. Available from: <https://www.globalwellnesssummit.com/about-us/past-summits/>
6. Senić V, Manojlović N. Contemporary tendencies in tourism. *Hotel and Tourism Management*. 2017;5(1):18-27.
7. WHO. Coronavirus disease (COVID-19) pandemic [Internet]. 2020 [cited 2022 Nov 3]. Available from: <https://www.who.int/europe/emergencies/situations/covid-19>
8. Mikić D, Zvekić Svorcan J, Jovanović L, Vučićević VR. Mental health of patients with chronic diseases during the Coronavirus disease 2019 pandemic in Serbia: a cross-sectional study. *Med Pregl*. 2020;73(7-8):212-20.
9. Bošković K, Gojković Z, Jović M, Jovičević P, Janković T, Zvekić-Svorcan J. Health concerns of patients with rheumatoid arthritis during the coronavirus disease 2019 pandemic. *Med Pregl*. 2021;74(9-10):291-7.
10. Zhang K, Hou Y, Li G. Threat of infectious disease during an outbreak: influence on tourists' emotional responses to disadvantaged price inequality. *Ann Tour Res*. 2020;84:102993.
11. Mak AHN, Wong KKF, Chang RCY. Health or self-indulgence? The motivations and characteristics of spa-goers. *International Journal of Tourism Research*. 2009;11(2):185-99.
12. Kock F, Nørfelt A, Josiassen A, Assaf AG, Tsionas MG. Understanding the COVID-19 tourist psyche: the Evolutionary Tourism Paradigm. *Ann Tour Res*. 2020;85:103053.
13. Wen J, Kozak M, Yang S, Liu F. COVID-19: potential effects on Chinese citizens' lifestyle and travel. *Tourism Review*. 2020;76(1):74-87.
14. Kim HL, Woo E, Uysal M, Kwon N. The effects of corporate social responsibility (CSR) on employee well-being in the hospitality industry. *International Journal of Contemporary Hospitality Management*. 2018;30(3):1584-600.
15. Luo Y, Lanlung C, Kim E, Tang LR, Song SM. Towards quality of life: the effects of the wellness tourism experience. *Journal of Travel and Tourism Marketing*. 2018;35(4):410-24.
16. Voigt C, Brown G, Howat G. Wellness tourists: in search of transformation. *Tourism Review*. 2011;66(1/2):16-30.
17. Chen CC, Petrick JF. Health and wellness benefits of travel experiences: a literature review. *J Travel Res*. 2013;52(6):709-19.
18. Iso-Ahola SE. Toward a social psychological theory of tourism motivation: a rejoinder. *Ann Tour Res*. 1982;9(2):256-62.
19. Gao J, Kerstetter DL, Mowen AJ, Hickerson B. Changes in tourists' perception of well-being based on their use of emotion regulation strategies during vacation. *Journal of Travel and Tourism Marketing*. 2018;35(5):567-82.
20. Crompton JL. Motivations for pleasure vacation. *Ann Tour Res*. 1979;6(4):408-24.
21. Živanović S, Manojlović N. Definition of wellness and its concepts. *Hotel and Tourism Management*. 2016;4(1):74-82.
22. Živanović S. Oblici i trendovi zdravstvenog turizma. 2nd ed. Vrnjačka Banja: Fakultet za hotelijerstvo i turizam; 2020.
23. Terme Olimia. Selfness [Internet]. [cited 2022 Nov 3]. Available from: <https://www.terme-olimia.com/en/adventures/selfness>
24. Koščak M, Mišković I, Romanov R, Holodkov V. Education for work in wellness tourism: case study. *TIMS Acta*. 2018;12(2):89-96.

25. Knežević VA, Ratković D, Knežević J, Ivanović-Kovačević S, Okanović M, Pavlović S. Psychological medicine. *Med Pregl.* 2019;72(9-10):321-5.

Rad je primljen 14. XI 2022.

Recenziran 23. XI 2022.

Prihvaćen za štampu 24. XI 2022.

BIBLID.0025-8105:(2022):LXXV:7-8:211-216.

26. Abdurachman, Herawati N. The role of psychological well-being in boosting immune response: an optimal effort for tackling infection. *Afr J Infect Dis.* 2018;12(1 Suppl):54-61.

University of Banja Luka, Republic of Srpska  
Faculty of Medicine, Banja Luka<sup>1</sup>  
University Clinical Centre of the Republic of Srpska  
Eye Clinic, Banja Luka, Republic of Srpska<sup>2</sup>

Original study  
*Originalni naučni rad*  
UDK 617.741-004.1-089-036.8:612.842  
UDK617.7-007.681  
<https://doi.org/10.2298/MPNS2208217M>

## EFFECTS OF CATARACT SURGERY ON SHORT-TERM INTRAOCULAR PRESSURE FLUCTUATIONS IN PATIENTS WITH PRIMARY ANGLE-CLOSURE AND PRIMARY ANGLE-CLOSURE GLAUCOMA

*UTICAJ OPERACIJE KATARAKTE NA KRATKOTRAJNE FLUKTUACIJE INTRAOKULARNOG PRITISKA KOD PACIJENATA SA PRIMARNIM ZATVARANJEM UGLA I PRIMARNIM GLAUKOMOM ZATVORENOG UGLA*

Bojana MARKIĆ<sup>1,2</sup>, Milka MAVIJA<sup>1,2</sup>, Saša SMOLJANOVIĆ SKOČIĆ<sup>1,2</sup> and Sanela-Sanja BURGIĆ<sup>1,2</sup>

### Summary

**Introduction.** Cataract surgery results in a reduction of intraocular pressure, but it has not been sufficiently investigated how it affects short-term intraocular pressure fluctuations. The aim of this study was to evaluate the effects of cataract surgery on short-term intraocular pressure fluctuations in patients with primary angle-closure, with or without glaucoma. **Material and Methods.** A prospective interventional clinical study included 31 patients (eyes) with primary angle-closure/primary angle-closure glaucoma (study group) and 31 patients (eyes) with cataract only (control group). All subjects underwent cataract surgery. Preoperatively, and at the first, third and sixth postoperative months, diurnal tension curves for the assessment of intraocular pressure was performed and the mean intraocular pressure and short-term intraocular pressure fluctuations were evaluated. **Results.** Postoperatively, the mean intraocular pressure and short-term intraocular pressure fluctuations were significantly reduced in both groups. In the study group, the highest mean intraocular pressure reduction was  $-4.14 \pm 2.50$  mmHg, and in the control group it was  $-2.44 \pm 1.76$  mmHg. The highest reduction of short-term fluctuations was  $-1.61 \pm 3.55$  mmHg in the study group, and  $-0.55 \pm 1.72$  mmHg in the control group. In both groups, a significant negative correlation was found between the preoperative and postoperative mean intraocular pressure and short-term intraocular pressure fluctuations. At the end of the research, the number of medications was reduced by 18.4% compared to the preoperative period. **Conclusion.** Cataract surgery in patients with primary angle-closure/primary angle-closure glaucoma results in a significant reduction of intraocular pressure, short-term intraocular pressure fluctuations, and a reduction in the number of medications. **Key words:** Glaucoma, Angle-Closure; Glaucoma; Intraocular Pressure; Cataract Extraction; Ophthalmologic Surgical Procedures; Treatment Outcome

### Introduction

Globally, cataract and glaucoma are the two leading causes of blindness [1] and often, at a certain point, they may occur together in the same person.

### Sažetak

**Uvod.** Operacija katarakte rezultira sniženjem intraokularnog pritiska ali je nedovoljno ispitano kako utiče na njegove kratkoročne fluktuacije. Cilj ove studije je bio da ispitamo uticaj operacije katarakte na kratkoročne fluktuacije intraokularnog pritiska kod osoba sa primarnim zatvaranjem komornog ugla, sa glaukomom ili bez njega. **Materijal i metode.** U prospektivnu intervencijsku kliničku studiju je uključen 31 pacijent (oko) sa primarnim zatvaranjem ugla/primarnim glaukomom zatvorenog ugla (eksperimentalna grupa) i 31 pacijent (oko) samo sa kataraktom (kontrolna grupa). Svim ispitanicima je urađena operacija katarakte. Preoperativno, prvi, treći i šesti mesec postoperativno, sproveden je test dnevne krive intraokularnog pritiska i ispitanici su prosečni intraokularni pritisak i njegove kratkoročne fluktuacije. **Rezultati.** Postoperativno, prosečni intraokularni pritisak i njegove kratkoročne fluktuacije su, u obe grupe, značajno redukovani. Najveća redukcija prosečnog intraokularnog pritiska u eksperimentalnoj grupi iznosila je  $-4.14 \pm 2.50$  mmHg, a u kontrolnoj grupi  $-2.44 \pm 1.76$  mmHg. Najveća redukcija kratkotrajnih fluktuacija za eksperimentalnu grupu iznosila je  $-1.61 \pm 3.55$  mmHg, a za kontrolnu grupu,  $-0.55 \pm 1.72$  mmHg. U obe grupe utvrđena je značajna negativna korelacija između preoperativnog prosečnog intraokularnog pritiska i njegovih kratkotrajnih fluktuacija sa njihovom postoperativnom promenom. Na kraju istraživanja, broj medikamenata je redukovano za 18,4% u odnosu na preoperativni broj. **Zaključak.** Operacija katarakte kod pacijenata sa primarnim zatvaranjem ugla/primarnim glaukomom zatvorenog ugla rezultira značajnom redukcijom intraokularnog pritiska, njegovih kratkotrajnih fluktuacija i broja lekova.

**Cljučne reči:** glaukom zatvorenog ugla; glaukom; intraokularni pritisak; ekstrakcija katarakte; oftalmološke hirurške procedure; ishod lečenja

Increased intraocular pressure (IOP) is the most significant risk factor for the occurrence and progression of glaucoma and, for now, the only one that can be modified [2, 3]. Some studies identify large diurnal fluctuations in IOP as an independent risk factor

### Abbreviations

IOP	– intraocular pressure
PACG	– primary angle-closure glaucoma
PAC	– primary angle-closure
BCVA	– best-corrected visual acuity
ICA	– iridocorneal angle
DTC	– diurnal tension curves
IOPav	– average IOP
IOPst	– short-term daily fluctuation of IOP
PHACO	– phacoemulsification method
CAI	– carbonic anhydrase inhibitors
GAT	– Goldmann applanation tonometer

for the development and progression of glaucoma [4]. The traditional treatment of glaucoma includes ocular hypotension drugs applied locally or systemically, laser systems or filtration surgeries. It is well known that cataract surgery leads to IOP reduction, both in glaucoma, and in nonglaucoma patients, although with different clinical significance depending on the type of glaucoma [5–9]. Primary angle-closure glaucoma (PACG), compared to other types of glaucoma, carries a much higher risk of bilateral blindness due to a specific pathomechanisms [10]. The PACG is preceded by primary angle-closure (PAC). Results of previous research on the effects of cataract surgery on the lowering of IOP in patients with PAC/PACG, point to cataract surgery as part of the treatment, and for some patients, as the first and the only therapeutic approach [11]. Due to challenges in data collection, there are only a few studies that have investigated the effects of cataract surgery on short-term IOP fluctuations in patients with PAC/PACG and the aim of this study was to examine this relationship, believing that our results will contribute to a better understanding of the disease and help physicians make the most favorable decision about the therapeutic approach.

### Material and Methods

The study was conducted at the University Clinical Center of the Republic of Srpska, Bosnia and Herzegovina, from December 2019 to December 2020. The research was done in accordance with the Helsinki Declaration and all the subjects signed an informed consent which had been approved by the Ethics Committee of the Institution.

The prospective intervention clinical study included 31 patients (31 eyes) with the diagnosis of PAC/PACG (PAC/PACG group) and 31 patients (31 eyes) with senile/presenile cataract (control group, Cataract).

Inclusion criteria for PAC/PACG group were: bilateral presence of iridotrabecular contact of  $\geq 180^\circ$  on gonioscopy; gonioscopy findings of grade 2, 1 or 0 using the Shaffer grading system [12]; IOP  $> 21$  mmHg in the period when the diagnosis was established or findings of peripheral anterior synechiae (PAS); absence of glaucomatous optic neuropathy in patients with PAC and its presence in patients with PACG; visual field defects in patients with PACG; presence of clinically significant cataract or absence of clinically

significant cataract if clinical examination indicated benefits from clear lens extraction.

Inclusion criteria for the Cataract group were: clinically significant cataract with best-corrected visual acuity (BCVA)  $\leq 0.5$  optotype according to a Snellen chart; bilateral gonioscopic findings of grade 4 or 3 according to Shaffer; bilateral IOP  $\leq 21$  mmHg.

Exclusion criteria for both groups were: previous eye injury, inflammatory and/or degenerative disease of ocular adnexa, as well as of the anterior or posterior eye segment, retinal disease, non-glaucomatous optic neuropathy, long-term use of corticosteroids (systemic and topical) or intraocular surgical or laser intervention except neodymium-doped yttrium aluminium garnet iridotomy in patients with PAC/PACG; operative and postoperative periods with complications.

Before the surgery, basic demographic data were collected, BCVA was established, slit-lamp examination was done, one measurement of IOP was obtained using Goldmann applanation tonometry, grading of the iridocorneal angle (ICA) was done and “gonioscopy score” was calculated [13]. Biometric measurements were performed by non-contact method using IOLMaster 500 biometer (Carl Zeiss Meditec, Inc., Dublin, CA) and contact applanation A-scan ultrasound biometry (Tomey, AL-100 Biometer, Japan). The number and types of glaucoma medications were registered. Diurnal tension curves (DTC) test of intraocular pressure was done with measurements at 07:30, 13:30 and 19:30 and the average IOP (IOPav) was calculated using the formula: IOPav 3.

Short-term (st) daily fluctuation of IOP was calculated using the formula: IOPst = IOP maximum – IOP minimum.

The criteria for the selection of an eye for surgery in the Cataract group was the eye with worse BCVA, and in the PAC/PACG, it was the eye with higher IOP.

The surgery was performed under topical anesthesia with phacoemulsification (PHACO), “in-the-bag” “phaco-chop” technique with intraocular lens implantation (Akreos Adapt AO, Bausch&Lomb) through 2.75 mm incision, using Stellaris Vision Enhancement System (Bausch&Lomb) device.

For the purpose of the study, a routine four-week treatment protocol was modified to prevent the potential effect of corticosteroids on the intraocular lens level, and all subjects stopped receiving corticosteroid drops after the second week, and continued with non-steroidal anti-inflammatory eye drops until the end of the first month. In the PAC/PACG group, already on the first postoperative day, all the subjects stopped receiving miotics and systemic carbonic anhydrase inhibitors (CAI). Some subjects stopped receiving prostaglandin analogues for one month or permanently if the monitoring showed that IOP was lowered, reaching the target value. Those patients received beta blocker drops or topical CAI if they had not been used preoperatively or the daily dosage of topical CAI was increased from 2 to 3 times a day. The criterion for adjusting the therapy was the postoperative level of IOP  $\leq 21$  mmHg.

Controls were performed on the 1st and 7th postoperative days, as well as after 1, 3 and 6 months. Controls after 1, 3 and 6 months included DTC. All clinical examinations and surgeries were performed by the same surgeon (B. M.).

Statistical analysis was performed using IBM SPSS Statistics 21.0 software. The Pearson's chi-square test, Mann-Whitney U test, Student's t-test, Kruskal-Wallis H test, Bonferroni test, Wilcoxon signed-rank test and Spearman's rank correlation test were used. Data were statistically processed and  $p < 0.01$  and  $p < 0.05$  were considered statistically significant.

### Results

The PAC/PACG group included 19 women (61.3%) and 12 men (38.7%), and in the Cataract group there were 16 women (51.6%) and 15 men (48.4%). The average age in the PAC/PACG group was  $72 \pm 8$  (range 55 - 89) and somewhat younger in the Cataract

group,  $71 \pm 7$  (range 53 - 82). There was no statistically significant difference in the gender ( $\chi^2 (1, 62) = 0.59$ ;  $p = 0.442$ ) or age distribution (Mann-Whitney U test;  $p = 0.059$ ) between the two groups.

The average preoperative BCVA in the PAC/PACG group was  $0.33 \pm 0.23$  (range 0.03 - 1), and in the Cataract group  $0.16 \pm 0.15$  (range 0 - 0.6). Already on the first postoperative day, and at each time point of the follow-up, both groups presented with a statistically significant improvement of BCVA compared to the preoperative value (Wilcoxon signed-rank test;  $p < 0.01$ ). After 6 months, in the PAC/PACG group the BCVA was  $0.81 \pm 0.28$  (range 0.2 - 1), and in the Cataract group  $0.97 \pm 0.06$  (range 0.8 - 1). Bonferroni test showed that the PAC/PACG group had a statistically significantly higher preoperative BCVA ( $p < 0.01$ ), and postoperatively, on each control visit, significantly lower BCVA compared to the control group ( $p < 0.01$ ).

Preoperative and postoperative values of IOPav and IOPst in both groups are shown in **Table 1**.

**Table 1.** Descriptive data for the mean intraocular pressure and the short-term intraocular pressure fluctuations per group and time points

**Tabela 1.** Deskriptivni podaci za varijable prosečni intraokularni pritisak (IOPav) i kratkoročne fluktuacije intraokularnog pritiska (IOPst) po grupama i vremenskim odrednicama

	PAC/PACG/PAC/PACG (N/Br. = 31) M ± SD (range/opseg)	Cataract/Katarakta (N/Br. = 31) M ± SD (range/opseg)
<i>Preoperatively/Preoperativno</i>		
IOPav (mmHg)	17.98 ± 3.03 (13.03 - 26.53)	14.53 ± 2.04 (10.67 - 19.7)
IOPst (mmHg)	4.24 ± 3.67 (0.9 - 19)	2.79 ± 1.46 (0 - 5.4)
<i>1 month/1. mesec</i>		
IOPav (mmHg)	14.74 ± 3.09 (5.53 - 21)	13.53 ± 2.22 (9.57 - 17.63)
IOPst (mmHg)	2.9 ± 1.66 (0.7 - 8.8)	2.4 ± 1.34 (0.3 - 4.7)
<i>3 month/3. mesec</i>		
IOPav (mmHg)	14.13 ± 2.48 (9.13 - 20.47)	12.09 ± 2.03 (7.67 - 15.6)
IOPst (mmHg)	2.63 ± 1.63 (0.7 - 7.9)	2.37 ± 1.06 (0.9 - 4.8)
<i>6 month/6. mesec</i>		
IOPav (mmHg)	13.84 ± 2.32 (9.3 - 18.43)	12.27 ± 1.89 (9.37 - 15.77)
IOPst (mmHg)	2.87 ± 1.47 (0.4 - 7.6)	2.24 ± 1.17 (0.3 - 4.9)

Legend: PAC/PACG – primary angle closure/primary angle-closure glaucoma; IOPav – average intraocular pressure; IOPst – short-term intraocular pressure; M – mean; SD – standard deviation

Legenda: PAC/PACG – primarno zatvarajući ugao/primarni glaukom zatvarajućeg ugla; IOPav – prosečni intraokularni pritisak; IOPst – kratkoročne fluktuacije intraokularnog pritiska; M – prosek; SD – standardna devijacija

**Table 2.** Descriptive data for the absolute and relative postoperative changes in the mean intraocular pressure

**Tabela 2.** Deskriptivni podaci za apsolutnu i relativnu postoperativnu promenu prosečnog intraokularnog pritiska

	$\Delta$ IOPav 1 month/ $\Delta$ IOPav 1. mesec M ± SD (mmHg) (%)	$\Delta$ IOPav 3 month/ $\Delta$ IOPav 3. mesec M ± SD (mmHg) (%)	$\Delta$ IOPav 6 month/ $\Delta$ IOPav 6. mesec M ± SD (mmHg) (%)
PAC/PACG N/Br. = 31	- 3.24 ± 2.91 (- 17.28)	- 3.85 ± 2.25 (- 20.72)	- 4.14 ± 2.50 (- 22.18)
Cataract Katarakta N/Br. = 31	- 1.00 ± 1.73 (- 6.54)	- 2.44 ± 1.76 (- 16.40)	- 2.26 ± 1.71 (- 15.06)

Legend: PAC/PACG – primary angle closure/primary angle-closure glaucoma;  $\Delta$  IOPav - postoperative change in the mean intraocular pressure; M - mean; SD - standard deviation

Legenda: PAC/PACG – primarno zatvarajući ugao/primarni glaukom zatvarajućeg ugla;  $\Delta$  IOPav – postoperativna promena prosečnog intraokularnog pritiska; M – prosek; SD – standardna devijacija

Wilcoxon test established that in both groups postoperative values of IOPav at any time of measurement were significantly lower ( $p < 0.01$ ) compared to the preoperative IOPav. A significant difference between the postoperative IOPst and its preoperative value was established only in the PAC/PACG group in the first ( $p < 0.05$ ) and the third postoperative month ( $p < 0.01$ ).

Preoperatively, the Bonferroni test registered a significantly lower value of IOPav in the Cataract group compared to the PAC/PACG group (- 3.441;  $p < 0.01$ ) and postoperatively in the 3rd (- 2.036;  $p < 0.01$ ) and the 6th month (- 1.561;  $p < 0.05$ ). At each time point of the check-up, no statistically significant difference between the observed groups was registered for IOPst.

The postoperative change of IOPav and IOPst compared to their preoperative values was ex-

pressed through their absolute and relative change and it is shown in **Table 2** and **Table 3**.

The biggest change of IOPav in the PAC/PAC group was in the 6th month, while in the control group, that was the case in the 3rd month.

Bonferroni test established a statistically significant difference in the postoperative change of IOPav. The reduction of IOPav was lesser in the Cataract group compared to the PAC/PACG group in the 1st ( $p < 0.01$ ) and the 6th month ( $p < 0.05$ ).

With regard to IOPst, the data from **Table 3** show that its biggest absolute and relative reduction compared to the preoperative value in the PAC/PACG group was in the 3rd month. In the Cataract group, the biggest absolute reduction was in the 6th month. The data on the relative change of IOPst, which were positive values, show its increase compared to the preoperative value which, at first glance, seems incorrect,

**Table 3.** Descriptive data for the absolute and relative postoperative changes of IOPst

**Tabela 3.** Deskriptivni podaci za apsolutnu i relativnu postoperativnu promenu kratkoročnih fluktuacija intraokularnog pritiska

	$\Delta$ IOPst 1 mth/ $\Delta$ IOPst 1. mesec M $\pm$ SD (mmHg) (%)	$\Delta$ IOPst 3 mth/ $\Delta$ IOPst 3. mesec M $\pm$ SD (mmHg) (%)	$\Delta$ IOPst 6 mth/ $\Delta$ IOPst 6. mesec M $\pm$ SD (mmHg) (%)
PAC/PACG N/Br. = 31	-1.34 $\pm$ 3.46 (6.82)	-1.61 $\pm$ 3.55 (-6.31)	-1.37 $\pm$ 4.04 (25.84)
Cataract/Katarakta N/Br. = 31	-0.38 $\pm$ 1.67 (4.98)	-0.42 $\pm$ 1.65 (14.85)	-0.55 $\pm$ 1.72 (2.00)

Legend: PAC/PACG – primary angle closure/primary angle-closure glaucoma;  $\Delta$  IOPst - postoperative changes of the short-term intraocular pressure fluctuations; M - mean; SD - standard deviation

Legenda: PAC/PACG – primarno zatvarajući ugao/primarni glaukom zatvarajućeg ugla;  $\Delta$  IOPst – postoperativna promena kratkoročnih fluktuacija intraokularnog pritiska; M – prosek; SD – standardna devijacija

**Table 4.** Correlation between the preoperative and postoperative mean intraocular pressure and short-term intraocular pressure fluctuations

**Tabela 4.** Korelacija preoperativnog prosečnog intraokularnog pritiska i kratkoročnih fluktacija intraokularnog pritiska sa njihovom postoperativnom promenom

PAC/PACG (N/Br. = 31)				
		$\Delta$ IOPav 1 mth/ $\Delta$ IOPav 1. mesec	$\Delta$ IOPav 3 mth/ $\Delta$ IOPav 3. mesec	$\Delta$ IOPav 6 mth/ $\Delta$ IOPav 6. mesec
IOPav preop.	$r_s$	-0.479**	-0.576**	-0.557**
IOPav preop.	p	0.006	0.001	0.001
		$\Delta$ IOPst 1 mth/ $\Delta$ IOPst 1. mesec	$\Delta$ IOPst 3 mth/ $\Delta$ IOPst 3. mesec	$\Delta$ IOPst 6 mth/ $\Delta$ IOPst 6. mesec
IOPst preop.	$r_s$	-0.825**	-0.790**	-0.875**
IOPst preop.	p	0.000	0.000	0.000
Cataract/Katarakta (N/Br. = 31)				
		$\Delta$ IOPav 1 mth/ $\Delta$ IOPav 1. mesec	$\Delta$ IOPav 3 mth/ $\Delta$ IOPav 3. mesec	$\Delta$ IOPav 6 mth/ $\Delta$ IOPav 6. mesec
IOPav preop.	$r_s$	-0.321	-0.394*	-0.378*
IOPav preop.	p	0.078	0.028	0.036
		$\Delta$ IOPst 1 mth/ $\Delta$ IOPst 1. mesec	$\Delta$ IOPst 3 mth/ $\Delta$ IOPst 3. mesec	$\Delta$ IOPst 6 mth/ $\Delta$ IOPst 6. mesec
IOPst preop.	$r_s$	-0.600**	-0.674**	-0.707**
IOPst preop.	p	0.000	0.000	0.000

Legend: PAC/PACG – primary angle closure/primary angle-closure glaucoma;  $\Delta$  IOPav - postoperative changes of the mean intraocular pressure;  $\Delta$  IOPst - postoperative changes of the short-term intraocular pressure fluctuations;  $r_s$  - Spearman correlation coefficient; p - statistically significant value; \* $p < 0.05$ ; \*\* $p < 0.01$

Legenda: PAC/PACG – primarno zatvarajući ugao/primarni glaukom zatvarajućeg ugla;  $\Delta$  IOPav – postoperativna promena prosečnog intraokularnog pritiska;  $\Delta$  IOPst – postoperativna promena kratkoročnih fluktuacija intraokularnog pritiska;  $r_s$  – Spirmanov koeficijent korelacije; p – statistička značajnost; \* $p < 0,05$ ; \*\* $p < 0,01$

since IOPst has reduced postoperatively. This phenomenon is explained by the deviated values of IOPst registered in some patients.

Kruskal-Wallis and Bonferroni's tests established that there were no statistically significant differences between the research groups for the absolute change of IOPst.

Spearman's correlation test in both groups established a negative correlation between the preoperative and postoperative IOPav and IOPst (**Table 4**). In the PAC/PACG group, there was a moderately strong correlation for the IOPav and distinctly strong for the IOPst. In the Cataract group, there was a weak correlation for the IOPav and a strong for the IOPst.

The postoperative antiglaucoma therapy was changed compared to the preoperative period in terms of the number and the types of medications. At the end of the research, there was a reduction of 18.4% in the number of medications compared to the preoperative period, from average number of 2.45 medication preoperatively to average number of 2.0 medication at the 6th month.

## Discussion

In our research, there was no significant difference between the groups in regard to gender and age distribution, but there were slightly more female patients. Postoperatively, in both groups, there was a statistically and clinically significant improvement in the BCVA.

In order to get a proper insight into the effects of cataract surgery on the level of IOP and in order to avoid a "carryover" effect, it would have been ideal if there had been a preoperative "washout" period for antiglaucoma medications. Another option would be to keep the patients on preoperative therapy by type, number and treatment regimen after surgery. Guided by the ethical principles of clinical studies and postulates, primarily the postulate "Primum non nocere!", none of the above options could have been applied in our research and the postoperative antiglaucoma therapy was altered in the way described above.

As a biological phenomenon, the intraocular pressure is not fixed, but it changes during the 24-hour cycle and from one visit to another [14] and it is clear that one measurement of IOP within the regular working hours is a poor replacement for a circadian IOP profile of glaucoma patients [15]. The significance of IOP fluctuations is an important, but still an insufficiently studied risk factor for the occurrence and/or progression of glaucoma. This is evident from a growing number of studies in recent years dealing with these issues. With an objective to collect the most accurate data on IOP fluctuations, thanks to the development of new technologies, various extraocular and intraocular devices have been designed with integrated pressure sensors. Due to a number of shortcomings such as inconvenience, discomfort they cause, data presentation and a high price, these devices are not applicable in daily clinical practice and for now, they remain reserved only for research projects.

Recent studies on these issues come from highly developed countries and centres with access to new technologies such as Triggerfish contact-lens sensor, contact or non-contact tonometers for personal use (Icare HOME tonometer, Tono-Pen, Corvis ST, Ocular Response Analyzer, etc.) and less often, tonometers for intraocular application (EYEMATE) [16–18]. However, in the current clinical practice, Goldmann applanation tonometer (GAT) is considered a gold standard, due to its application in the majority of clinical studies since the 70s, and because of extensive publications about its accuracy, reliability and repeatability.

The DTC test of IOP is relatively inexpensive, but impractical both for the examiner and the patient (the patients come several times a day or they are hospitalized) and as such is rarely used in everyday clinical practice [19]. Despite the impracticality to perform, for the needs of our research, DTC test included three measurements per day at 07:30, 13:30 and 19:30 using GAT, and from the obtained data, IOPav and IOPst were determined. We compared our results with previous studies that analyzed the effect of cataract surgery on IOP fluctuation, which used GAT. However, a limiting factor is that there are few published studies that can be used for comparison.

Our results show that a statistically significant change of IOPst in the PAC/PACG group was in the 1st and 3rd postoperative month, whereas the most pronounced absolute ( $-1.61 \pm 3.55$  mmHg) and relative ( $-6.31\%$ ) reduction was in the 3rd month (**Table 3**). From preoperative  $4.24 \pm 3.67$  mmHg, IOPst in the 3rd month was reduced to  $2.63 \pm 1.63$  mmHg (**Table 1**), which is very similar to the results of Özyol et al. [20] who prospectively studied the effect of PHACO on diurnal fluctuation of IOP in 24 medically treated patients (39 eyes) with PACG and with a previously done laser iridotomy. The IOP was measured using GAT three times a day, at 08:00, 12:00 and 14:00, preoperatively and after 3 months postoperatively. The authors found a significant reduction of IOP fluctuation from preoperative  $4.6 \pm 2.1$  mmHg to  $2.8 \pm 1.5$  mmHg, 3 months after surgery.

Liu et al. [21] also used DTC test preoperatively and 3 months after the cataract surgery in 29 patients with PACG and previously done laser iridotomy. The IOP was measured at 08:00, 12:00 and 16:00 using GAT. In the 3rd postoperative month, they found that there was a significant reduction in IOP fluctuation by  $-1.3 \pm 2.3$  mmHg compared to the preoperative fluctuation of  $3.3 \pm 2.5$  mmHg. The methodology of the study by Liu et al. describes postoperative modification in medications almost in the same way as it was done in our research (excluding pilocarpine, pausing the prostaglandin analogues and introducing a replacement therapy with CAI, or similar). They reported a significant reduction in the number of medications from  $1.93 \pm 1.13$  preoperatively to  $0.83 \pm 0.89$  postoperatively. Correlation analysis in both groups established a negative correlation between preoperative and postoperative IOPav and IOPst (**Table 4**). This means that preoperatively higher IOPav can be expected to have a larger reduction postoperatively. In accordance with the above-men-



tioned, short-term fluctuations are postoperatively “narrower” if the preoperative range is wider.

After an extensive search of literature on Medline and PubMed, we did not find data on correlation analysis of preoperative and postoperative short-term fluctuations of IOP in patients with PAC/PACG who had a cataract surgery, which additionally contributes to the relevance of our data.

Although the main goal of our research was to analyze the IOPst, it is also necessary to report about the postoperative reduction of the IOPav. In both groups, the postoperative IOPav was significantly lower than preoperative IOPav (**Table 1**). The biggest change of IOPav in the PAC/PACG group was in the 6th month when it was  $-4.14 \pm 2.50$  mmHg, i.e.  $-22.18\%$  (**Table 2**). In the control group, that was the case in the 3rd month and the reduction of IOPav was  $-2.44 \pm 1.76$  mmHg, i.e.  $-16.40\%$  (**Table 2**).

Our results are in agreement with other researchers who analyzed the effects of PHACO on the intraocular pressure in patients with PAC/PACG. Shams and Foster [22] reported a significant reduction of IOP from preoperative  $18.7 \pm 7.3$  mmHg to postoperative  $14.1 \pm 4$  mmHg (reduction of  $-4.5 \pm 5.4$  mmHg;  $-24\%$ ). The results of

their retrospective study point out that the reduction was more noticeable in patients with preoperatively higher IOP and the finding of PAS to over  $180^\circ$  of ICA.

According to the study by Pandav et al., the reduction of IOP in the 6th month in PAC group was  $-2.08$  mmHg ( $-13.5\%$ ), and in PACG group  $-2.55$  mmHg ( $-14.5\%$ ) [23].

A study by Traverso and Cutolo included a sample of 37 patients with PACG and 17 patients with PAC. In the PACG group, a preoperative average IOP of  $22.29 \pm 8.83$  mmHg decreased by  $-8.45 \pm 8.03$  mmHg ( $-37.9\%$ ) in the 6th month. In the PAC group, there was a reduction of IOP of  $-3.1 \pm 4.8$  mmHg ( $-20\%$ ) in the 6th month compared to the preoperative IOP of  $15.50 \pm 4.85$  mmHg [24].

## Conclusion

The results of our research show that cataract surgery in patients with primary angle closure/primary angle-closure glaucoma resulted in a significant reduction of the average intraocular pressure, short-term intraocular pressure fluctuations, and a reduction in the number of medications.

## References

1. Pascolini D, Mariotti SP. Global estimates of visual impairment: 2010. *Br J Ophthalmol*. 2012;96(5):614-8.
2. Boland MV, Ervin AM, Friedman DS, Jampel HD, Hawkins BS, Vollenweider D, et al. Comparative effectiveness of treatments for open-angle glaucoma: a systematic review for the U.S. Preventive Services Task Force. *Ann Intern Med*. 2013;158(4):271-9.
3. Heijl A, Leske MC, Bengtsson B, Hyman L, Bengtsson B, Hussein M, et al. Reduction of intraocular pressure and glaucoma progression: results from the Early Manifest Glaucoma trial. *Arch Ophthalmol*. 2002;120(10):1268-79.
4. Asrani S, Zeimer R, Wilensky J, Gieser D, Vitale S, Lindemuth K. Large diurnal fluctuations in intraocular pressure are an independent risk factor in patients with glaucoma. *J Glaucoma*. 2000;9(2):134-42.
5. Shrivastava A, Singh K. The effect of cataract extraction on intraocular pressure. *Curr Opin Ophthalmol*. 2010;21(2):118-22.
6. Shingleton BJ, Pasternack JJ, Hung JW, O'Donoghue MW. Three and five year changes in intraocular pressures after clear corneal phacoemulsification in open angle glaucoma patients, glaucoma suspects, and normal patients. *J Glaucoma*. 2006;15(6):494-8.
7. Mansberger SL, Gordon MO, Jampel H, Bhorade A, Brandt JD, Wilson B, et al. Reduction in intraocular pressure after cataract extraction: the Ocular Hypertension Treatment Study. *Ophthalmology*. 2012;119(9):1826-31.
8. Chen PP, Lin SC, Junk AK, Radhakrishnan S, Singh K, Chen TC. The effect of phacoemulsification on intraocular pressure in glaucoma patients: a report by the American Academy of Ophthalmology. *Ophthalmology*. 2015;122(7):1294-307.
9. Markić B, Mavija M, Smoljanović Skočić S, Burgić SS. Effects of cataract surgery on short-term and long-term intraocular pressure fluctuations in non-glaucomatous and medically controlled primary open-angle glaucoma patients. *Med Pregl*. 2019;72(7-8):202-8.
10. Foster PJ, Buhrmann R, Quigley HA, Johnson GJ. The definition and classification of glaucoma in prevalence surveys. *Br J Ophthalmol*. 2002;86(2):238-42.
11. Azuara-Blanco A, Burr J, Ramsay C, Cooper D, Foster PJ, Friedman DS, et al. Effectiveness of early lens extraction for the treatment of primary angle-closure glaucoma (EAGLE): a randomised controlled trial. *Lancet*. 2016;388(10052):1389-97.
12. Shaffer RN, Tour RL. A comparative study of gonioscopic methods. *Am J Ophthalmol*. 1956;41(2):256-65.
13. Perez CI, Chansangpetch S, Feinstein M, Mora M, Nguyen A, Badr M, et al. Novel gonioscopy score and predictive factors for intraocular pressure lowering after phacoemulsification. *J Glaucoma*. 2018;27(7):622-6.
14. Quaranta L, Katsanos A, Russo A, Riva I. 24-hour intraocular pressure and ocular perfusion pressure in glaucoma. *Surv Ophthalmol*. 2013;58(1):26-41.
15. Konstas AG, Kahook MY, Araie M, Katsanos A, Quaranta L, Rossetti L, et al. Diurnal and 24-h intraocular pressures in glaucoma: monitoring strategies and impact on prognosis and treatment. *Adv Ther*. 2018;35(11):1775-804.
16. Aziz K, Friedman DS. Tonometers-which one should I use? *Eye (Lond)*. 2018;32(5):931-7.
17. Gillmann K, Mansouri K. Minimally invasive surgery, implantable sensors, and personalized therapies. *J Ophthalmic Vis Res*. 2020;15(4):531-46.
18. Tojo N, Hayashi A, Otsuka M. Correlation between 24-h continuous intraocular pressure measurement with a contact lens sensor and visual field progression. *Graefes Arch Clin Exp Ophthalmol*. 2020;258(1):175-82.
19. Konstas AG, Quaranta L, Bozkurt B, Katsanos A, Garcia-Feijoo J, Rossetti L, et al. 24-h efficacy of glaucoma treatment options. *Adv Ther*. 2016;33(4):481-517.
20. Özyol P, Özyol E, Sül S, Baldemir E, Çavdar S. Intraocular pressure fluctuation after cataract surgery in primary angle-closure glaucoma eyes medically controlled after laser iridotomy. *Acta Ophthalmol*. 2016;94(7):e528-33.
21. Liu CJ, Cheng C, Wu CW, Lau LI, Chou JC, Hsu WM. Factors predicting intraocular pressure control after phaco-

mulsification in angle-closure glaucoma. Arch Ophthalmol. 2006;124(10):1390-4.

22. Shams PN, Foster PJ. Clinical outcomes after lens extraction for visually significant cataract in eyes with primary angle closure. J Glaucoma. 2012;21(8):545-50.

23. Pandav SS, Seth NG, Arora A, Thattaruthody F, Juran-gal A, Kaushik S, et al. Intraocular pressure reduction in a

spectrum of angle closure disease following cataract extraction. Indian J Ophthalmol. 2019;67(9):1433-8.

24. Traverso CE, Cutolo CA. The Effects of phacoemulsification and intraocular lens implantation on anatomical and functional parameters in patients with primary angle closure: a prospective study. (An American Ophthalmological Society thesis). Trans Am Ophthalmol Soc. 2017;115:T7.

Rad je primljen 9. IX 2022.

Recenziran 22. XI 2022.

Prihvaćen za štampu 2. XII 2022.

BIBLID.0025-8105:(2022):LXXV:7-8:217-223.

Oncology Institute of Vojvodina, Sremska Kamenica<sup>1</sup>  
University of Novi Sad, Faculty of Medicine Novi Sad<sup>2</sup>

Original study  
*Originalni naučni rad*  
UDK 618.1-006.6-036.8:615.849  
<https://doi.org/10.2298/MPNS2208224R>

## THE IMPACT OF VOLUMETRIC MODULATED ARC RADIOTHERAPY ON CLINICAL OUTCOMES OF PATIENTS WITH GYNECOLOGICAL MALIGNANCIES

*UTICAJ PRIMENE VOLUMETRIJSKI MODULISANE LUČNE RADIOTERAPIJE NA KLINIČKI ISHOD KOD PACIJENTKINJA LEČENIH OD GINEKOLOŠKIH KARCINOMA*

Milijana RAKIN<sup>1</sup>, Nataša ANIČIĆ<sup>1</sup>, Olivera IVANOV<sup>1,2</sup>, Sanja JARIĆ<sup>1</sup>,  
Nemanja NOVAKOVIĆ<sup>1</sup> and Ivan KOPRIVICA<sup>1</sup>

### Summary

**Introduction.** In locally advanced cancers of the cervix, endometrium and vulva, radiotherapy is the primary treatment modality. In recent years, new modern techniques of external radiation have been developed in radiation oncology, with the goal of dose escalation to the target volume, while sparing healthy tissues. The aim of this study is to determine the impact of volumetric modulated arc therapy on clinical outcomes of patients with gynecological malignancies. **Material and Methods.** Data were retrospectively collected from 60 patients treated for *International Federation of Gynecology and Obstetrics* stage I – III cervical, endometrial and vulvar cancers, using definitive (n = 35) or adjuvant (n = 25) radiotherapy/chemoradiotherapy. Thirty patients underwent three-dimensional conformal radiation therapy (definitive in 22 and adjuvant in 8) and the other 30 patients were treated with volumetric modulated arc therapy (definitive in 13 and adjuvant in 17). The following clinical outcome parameters were compared between the two groups: complete clinical response, disease free survival, progression free survival, and 4-year overall survival. **Results.** Progression free survival of patients treated with definitive radiotherapy/chemoradiotherapy using volumetric modulated arc therapy was 17.2 months, while in the group treated with three-dimensional conformal radiation therapy it was 7.9 months (p = 0.300). Four-year overall survival in patients who were treated with definitive radiotherapy/chemoradiotherapy using three-dimensional conformal radiation therapy was 50%, and 61.5% in the group treated with definitive volumetric modulated arc therapy (p = 0.200), while in patients treated using adjuvant radiotherapy/chemoradiotherapy it was 75% vs. 88.2%, respectively (p = 0.400). **Conclusion.** Although without statistical significance, volumetric modulated arc therapy showed better results with respect to progression free survival and 4-year overall survival in previously unoperated patients who underwent definitive radiotherapy/chemoradiotherapy.

**Key words:** Radiotherapy; Radiotherapy, Intensity-Modulated; Genital Neoplasms, Female; Survival Rate; Treatment Outcome

### Sažetak

**Uvod.** Kod lokalno uznapredovalih karcinoma cerviksa, endometriuma i vulve, radioterapija predstavlja primarnu terapijsku metodu. Poslednjih godina došlo je do razvoja novih, savremenih tehnika spoljašnjeg zračenja čiji je cilj eskalacija doze na ciljni volumen uz što veću poštedu organa od rizika. Cilj ovog istraživanja je utvrđivanje uticaja primene napredne volumetrijski modulisanu lučne radioterapijske tehnike na klinički ishod bolesnica lečenih od ginekoloških karcinoma. **Materijali i metode.** Retrospektivno su prikupljeni podaci od 60 pacijentkinja lečenih od karcinoma cerviksa, endometriuma ili vulve stadijuma po klasifikaciji Međunarodne federacije ginekologa i akušera, definitivnom (n = 35) ili adjuvantnom (n = 25) radioterapijom/hemioradioterapijom. Kod 30 pacijentkinja je sprovedena trodimenzionalna konformalna teleterapija (kod 22 definitivna i kod osam adjuvantna), a kod ostalih 30 volumetrijski modulisanu lučnu radioterapiju (kod 13 definitivnu i kod 17 adjuvantnu). Poredili smo sledeće kliničke ishode između dve navedene grupe: kompletan klinički odgovor, period preživljavanja bez bolesti, period do prve progresije bolesti i četvorogodišnje preživljavanje. **Rezultati.** Period preživljavanja do prve progresije bolesti je kod prethodno neoperisanih bolesnica lečenih volumenski modulisanom lučnom radioterapijskom tehnikom bio 17,2 meseca, dok je kod lečenih trodimenzionalnom konformalnom tehnikom bio 7,9 meseci (p = 0,300). Četvorogodišnje preživljavanje bilo je zastupljeno kod 50% lečenih definitivnom trodimenzionalnom konformalnom i 61,5% lečenih definitivnom volumetrijski modulisanom lučnom radioterapijskom tehnikom (p = 0,200) i kod 75% naspram 88,2% bolesnica lečenih adjuvantnom radioterapijom, respektivno (p = 0,400). **Zaključak.** Iako bez statističke značajnosti, pokazan je trend boljeg preživljavanja bez progresije bolesti kod prethodno neoperisanih pacijentkinja, kao i trend boljeg četvorogodišnjeg preživljavanja bolesnica kod kojih je primenjena volumetrijski modulisanu lučnu radioterapijsku tehniku. **Ključne reči:** radioterapija; volumetrijski modulisanu lučna radioterapija; ginekološke neoplazme; preživljavanje; ishod lečenja

### Introduction

According to the data published by the Global Cancer Observatory in 2020, cervical cancer was the fourth

most common malignancy in women (6.5% of all carcinomas) while endometrial cancer ranked sixth (4.5% of all carcinomas) [1]. Cervical cancer is the second most common cancer in women between the ages of

**Abbreviations**

CRT	– chemoradiotherapy
VMAT	– volumetric modulated arc therapy
IMRT	– intensity modulated radiation therapy
3DCRT	– three-dimensional conformal radiation therapy
EBRT	– external beam radiation therapy
CBCT	– cone beam computed tomography
FIGO	– International Federation of Gynecology and Obstetrics
MRI	– magnetic resonance imaging
CT	– computed tomography

15 and 44 [2]. According to the data published by the Institute of Public Health of Serbia “Dr. Milan Jovanović Batut”, the standardized incidence of cervical carcinoma in the territory of the Republic of Serbia in 2013 was 20.3, the incidence of endometrial carcinoma was 13.4 while the mortality rates were 12.7 and 7.1, respectively [3].

The treatment of patients with gynecological cancers varies and primarily depends on the local progression of the tumor and the stage of the disease. In locally advanced cancers of the cervix, endometrium and vulva, radiotherapy is the primary treatment modality, used alone or as chemoradiotherapy [4]. There are two types of radiation therapy used for gynecological malignancies: external beam radiation therapy (EBRT) (teletherapy) and intracavitary or interstitial radioisotope therapy (brachytherapy). In recent decades, three-dimensional conformal technique (3DCRT) of EBRT has gained precedence in the treatment of gynecological cancers. The main goal of conformal radiotherapy is to adjust and conform the external beam to the desired target volume (tumor) providing uniform distribution of the prescribed dose within the target volume, while at the same time minimizing the dose to the surrounding healthy tissues and organs [5, 6]. However, continual developments in radiation oncology have resulted in development of new, more precise techniques with the goal of further escalating the dose to the desired target volume and even greater sparing of healthy tissues. One of these new techniques is intensity modulated radiation therapy (IMRT). Many dosimetric studies have shown a significant reduction in the dose administered to organs at risk (small intestine, rectum and bladder) when IMRT is used, compared to 3DCRT [7]. Volumetric modulated arc therapy (VMAT) is a novel radiation therapy technique that derived from IMRT and was first described by Yu et al. in 1995 [8]. The VMAT technique allows continuous external beam shaping, as well as changes in the intensity of the beam, thus providing increased doses delivered to the target volume, while simultaneously reducing the treatment delivery time [9, 10].

The aim of this study is to examine the effects of VMAT on the clinical outcomes of patients with gynecological cancers using definitive and adjuvant radiation therapy.

**Material and Methods**

This retrospective study included 60 patients treated for gynecological cancers at the Oncology

Institute of Vojvodina in Sremska Kamenica, Republic of Serbia, between 2016 and 2018. At the moment of diagnosis, the patients were in stages I - III of the International Federation of Gynecology and Obstetrics (FIGO) classification. Patients with distant metastases or para-aortic lymph node spread were excluded from the study. The staging procedures and determination of local disease progression were based on pelvic and abdominal magnetic resonance imaging (MRI), computed tomography (CT) and chest X-ray. Treatment of these patients was conducted according to our institution's current protocols, which are based on National Comprehensive Cancer Network practice guidelines. Patients with cervical, endometrial and vulvar cancer were included in the study (**Table 1**). The treatment strategies were determined based on disease local progression, patients' age, and comorbidities. In 35 patients radiotherapy/chemoradiotherapy (RT/CRT) was the initial and definitive treatment, while the other 25 underwent primary surgical treatment, followed by adjuvant RT/CRT (**Table 2**). Most patients with cervical and endometrial cancer received brachytherapy following EBRT (**Table 2**). Based on the radiotherapy technique used, patients were divided into the following groups:

- Patients who underwent definitive RT/CRT – 22 treated with 3DCRT and 13 with VMAT (**Table 2**);
- Patients who underwent adjuvant RT/CRT – 8 treated with 3DCRT and 17 with VMAT (**Table 2**).

All patients received the same dose of 45 gray (Gy) in 25 fractions.

After completion of RT/CRT, all patients were regularly monitored at our institution by a radiation oncologist and a gynecologist. The monitoring included physical examination, analysis of blood samples, abdominal ultrasound and pelvic MRI which were done 4 months post treatment completion. Complete clinical response was based on the results of the first pelvic MRI. Further monitoring included the following parameters:

- Disease free survival – a measure of time after treatment during which no sign of cancer is found; also called relapse free survival.
- Progression free survival – a measure of time during and after treatment in which the disease is present, but there is no progression of the disease.
- Overall survival – percentage of patients in a study or treatment group who are still alive for a certain period of time from the date of diagnosis, most commonly stated as five-year survival; in this study it was stated as a four-year survival rate [11].

These parameters were observed separately for patients who received initial and definitive RT/CRT in comparison to those who received adjuvant RT/CRT following primary surgical treatment.

The Chi-square test was used for comparison of complete clinical response and 4-year overall survival and the Mann-Whitney test was used for comparison of disease free survival and progression free survival in patients treated with 3DCRT and VMAT. A  $p < 0.05$  was considered to be a statistically significant difference.

## Results

The mean patient age in the 3DCRT group was 57 years, while in the VMAT group it was 53 years. Patients were further divided into groups according to cancer localization, histopathological type of cancer and FIGO classification, as shown in **Table 1**. Squamous cell carcinoma of the cervix was the most prevalent type in both 3DCRT and VMAT groups. In regard to FIGO staging, patients in the

3DCRT group were predominantly in stage II, while in the VMAT group most were in stage I.

Of 60 patients, 35 were treated with definitive RT/CRT (**Table 2**). Adjuvant RT/CRT was performed in the remaining 25 patients. In total, 76.67% of patients in the 3DCRT group and 56.67% in the VMAT group underwent chemoradiotherapy (**Table 2**). Almost all of the 60 patients received brachytherapy following RT/CRT (**Table 2**).

**Table 1.** Mean age distribution according to cancer localization, histological type and FIGO classification

**Tabela 1.** Distribucija pacijentkinja prema prosečnoj starosti, lokalizaciji tumora, histološkom tipu tumora i FIGO klasifikaciji

		3D conformal/3D konformalna	VMAT/VMLT
Mean patient age at the time of diagnosis <i>Prosečna starost pacijentkinja u vreme postavljanja dijagonze (god.)</i>		57	53
Cancer localization <i>Lokalizacija tumora</i>	Cervix/Grlić materice	26 (86.67%)	20 (66.67%)
	Endometrium/Endometrium	3 (10%)	9 (30%)
	Vulva/Vulva	1 (3.33%)	1 (3.33%)
Histological type <i>Histološki tip tumora</i>	Planocellular/Planocelularni	23 (76.67%)	17 (56.67%)
	Adenocarcinoma/Adenokarcinom	5 (16.6%)	12 (40%)
	Adenosquamous/Adenoskvamozni	1 (3.33%)	1 (3.33%)
	Anaplastic/Anaplastični	1 (3.33%)	0
FIGO classification <i>FIGO klasifikacija</i>	I	10 (33.3%)	13 (43.3%)
	II	13 (43.3%)	12 (40%)
	III	7 (23.3%)	5 (16.6%)

Legend: 3D – three-dimensional; VMAT – volumetric modulated arc therapy; FIGO – International Federation of Gynecology and Obstetrics

Legenda: 3D – trodimenzionalan; VMLT – volumetrijski modulirana lučna terapija; FIGO – Međunarodna federacija ginekologije i akušerstva

**Table 2.** Distribution of patients according to treatment protocol

**Tabela 2.** Distribucija pacijentkinja prema primenjenim metodama lečenja

		3D conformal/3D konformalna	VMAT/VMLT
Primary surgery followed by RT/CRT <i>Operacija pre RT/HRT</i>	Yes/Da	8 (26.67%)	17 (56.67%)
	No/Ne	22 (73.33%)	13 (43.33%)
Chemoradiotherapy (Cisplatin IV series) <i>Hemioradioterapija (Cisplatin u IV serije)</i>	Yes/Da	23 (76.67%)	17 (56.67%)
	No/Ne	7 (23.33%)	13 (43.33%)
Brachytherapy following RT/CRT <i>Brahiterapija nakon RT/HRT</i>	Yes/Da	27 (90%)	24 (80%)
	No/Ne	3 (10%)	6 (20%)

Legend: 3D – three-dimensional; VMAT – volumetric modulated arc therapy; RT – Radiotherapy; CRT – chemoradiotherapy

Legenda: 3D – trodimenzionalan; VMLT – volumetrijski modulirana lučna terapija; RT – radioterapija; HRT – hemoradioterapija

**Table 3.** Comparison of treatment outcomes between 3D conformal and VMAT technique in patients who underwent definitive radiotherapy/chemoradiotherapy

**Tabela 3.** Poređenje kliničkih ishoda između pacijentkinja kod kojih je primenjena 3D konformalna i VMAT definitivna radioterapija/hemioradioterapija

		3D conformal/3D konformalna	VMAT/VMLT	
Complete clinical response/ <i>Kompletan klinički odgovor</i>		14 (63.6%)	8 (61.5%)	0.901
Disease free survival/ <i>Period bez prisustva bolesti</i>		46.5 months/meseci	47.6 months/meseci	0.948
Progression free survival/ <i>Period do prve progresije bolesti</i>		7.9 months/meseci	17.2 months/meseci	0.300
4-year overall survival/ <i>Četvorogodišnje preživljavanje</i>		11 (50.0%)	8 (61.5%)	0.643

Legend: 3D – three-dimensional; VMAT – volumetric modulated arc therapy

Legenda: 3D – trodimenzionalan; VMLT – volumetrijski modulirana lučna terapija

**Table 4.** Comparison of treatment outcomes between 3D conformal and VMAT technique in patients who underwent adjuvant radiotherapy/chemoradiotherapy**Tabela 4.** Poređenje kliničkih ishoda između pacijentkinja kod kojih je primenjena 3D konformalna i VMAT adjuvantna radioterapija/hemioradioterapija

	3D conformal/3D konformalna	VMAT/VMLT	p/p
Complete clinical response <i>Kompletan klinički odgovor</i>	8 (100%)	15 (88.2%)	0.312
Disease free survival <i>Period bez prisustva bolesti</i>	53.2 months (meseći)	47.8 months (meseći)	0.184
Progression free survival <i>Period do prve progresije bolesti</i>	/	13.6 months (meseći)	/
4-year overall survival <i>Četvorogodišnje preživljavanje</i>	6 (75%)	15 (88.2%)	0.400

Legend; 3D – three-dimensional; VMAT – volumetric modulated arc therapy

Legenda; 3D – trodimenzionalan; VMLT – volumetrijski modulirana lučna terapija

In patients who underwent definitive RT/CRT, a complete clinical response was achieved in 14 (63.6%) patients who were treated with 3DCRT and in 8 (61.5%) patients treated with VMAT, thus showing no statistically significant difference ( $p = 0.910$ ) (Table 3). In patients who were treated with adjuvant RT/CRT following surgery, a complete clinical response was achieved in all 8 (100%) patients who were treated with 3DCRT, and in 15 (88.2%) patients treated with VMAT (Table 4).

The average disease free survival in patients who were treated with definitive RT/CRT was 46.5 months in the 3DCRT group and 47.6 months in the

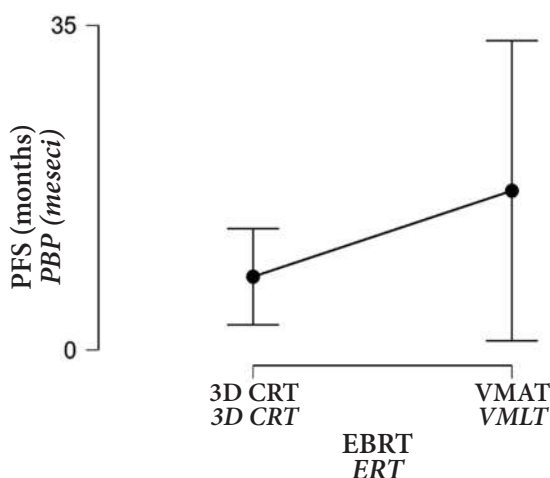
VMAT group, so there was no statistically significant difference between the two groups ( $p = 0.316$ ) (Table 3). In patients who underwent adjuvant RT/CRT, the average disease free survival was 53.2 months in the 3DCRT group and 47.8 months in the VMAT group ( $p = 0.184$ ) (Table 4).

The progression free survival in patients who were treated with definitive RT/CRT was 17.2 months in the VMAT group, almost double compared to 7.9 months in the 3DCRT group (Table 3, Graph 1). The VMAT group showed better 4-year overall survival as well, 65% compared to 50% in the 3DCRT group. Better 4-year overall survival was also reported in patients who underwent adjuvant RT/CRT when using VMAT technique (88.2%) compared to 3DCRT technique (75%) (Table 4). These differences were not statistically significant considering the sample size, but the reported results do show a trend of better survival in the VMAT group, which could potentially show a significant statistical difference in a bigger sample size.

## Discussion

Although our study showed no statistically significant difference between clinical outcomes of patients treated with 3DCRT and VMAT, in absolute terms it is clear that progression free survival of patients treated with definitive RT/CRT in the VMAT group is twice longer than in the 3DCRT group (17 months versus 7.9 months) and this may be considered as a significant result in oncology patients. Furthermore, the 4-year overall survival was over 10% in patients treated with VMAT technique. While reviewing the literature, we have come across only a few studies that reported on clinical results of 3DCRT and VMAT techniques in the treatment in gynecological malignancies. The available studies on related topics usually examine the outcomes of IMRT, dosimetry and organs at risk of toxicity.

Droge et al. reported comparable clinical results among patients who were treated for cervical carcinoma (FIGO I - IVA) using 3DCRT ( $n = 75$ ) and VMAT ( $n = 30$ ) technique of RT/CRT [12]. Their study demonstrated no statistically significant dif-

**Graph 1.** Difference in progression free survival between 3D conformal and VMAT technique in patients who underwent definitive radiotherapy/chemoradiotherapy**Grafikon 1.** Razlika u periodu do prve progresije bolesti između 3D i VMAT tehnike kod pacijentkinja koje su primile definitivnu radioterapiju/hemioradioterapiju

Legend; EBRT – external beam radiotherapy (Teletherapy); PFS – progression free survival; 3DCRT – three-dimensional conformal radiotherapy; VMAT – volumetric modulated arc therapy

Legenda; ERT – eksterna radioterapija (Teleterapija); PBP – preživljavanje bez progresije; 3DCRT – trodimenzionalna konformna radioterapija; VMLT – volumetrijska modulirana lučna terapija

ference in survival rates between the two groups. Lan et al. observed 115 patients who were treated for cervical carcinoma (FIGO IA - IIB) by radical hysterectomy, followed by either 3DCRT (n = 89) or IMRT (n = 26) technique, without brachytherapy [13]. The 2-year overall survival was 90.3% in the 3DCRT group, while in the IMRT group it was 91.6% (p = 0.674) and there was no statistically significant difference in the compared disease free survival either [13]. Comparable results can be seen in a study published by Tsuchida et al. [14]. They studied 73 patients diagnosed with locally advanced cervical carcinoma (parametrial tissue or pelvic lymph node involvement) who were treated using adjuvant radiation therapy. Out of 73 patients, 33 were treated with 3DCRT technique, and 40 using IMRT. This study showed no statistically significant difference in the 4-year overall survival (82% versus 78%, p = 0.744) or in the disease free survival. Cancer recurrence was recorded in 11 and 13 patients, respectively [14].

There is a concern that modern techniques, such as IMRT and VMAT, may increase locoregional recurrence by reducing the target volume, in order to protect organs at risk. However, previous studies have reported that the clinical outcomes did not deteriorate when using modern techniques compared to 3DCRT [15, 16].

A particularly difficult challenge in the treatment of gynecological malignancies and pelvic malignancies in general, is the interfractional target motion caused by variations in bladder and intestine volume compared to planning values, uterine peristalsis and motility. These can lead to reduced target volume coverage and consequent suboptimal radiation therapy. However, among modern techniques such as IMRT and VMAT, cone beam computed tomography (CBCT) is an effective image guided radiotherapy tool used daily to evaluate the position and coverage of target volume [5]. By using CBCT, we can generate volumetric CT images and perform target matching to the initial CT plan. If necessary, repositioning of patient is done in order to reduce

the possibility of error and to ensure precise delivery of treatment [5]. In 3DCRT, verification and target matching is performed by using kilovoltage orthogonal images which are compared with CT scans based on bony anatomy of the pelvis without any insight into the surrounding soft tissues. Consequently, it is expected that modern radiation therapy techniques will achieve better treatment results and thus better patient survival.

When reviewing the available literature on this topic, we have come across a few studies comparing IMRT and VMAT techniques in treatment of gynecological malignancies, most of them accenting dosimetry and organs at risk of toxicity. Cozzy et al. have noted that VMAT technique shows significant improvements in organs at risk and healthy tissue sparing with uncompromised target coverage compared to IMRT [17]. Knapp et al. reported similar results, noting greater sparing of organs at risk, while maintaining equal or even greater target coverage with VMAT, which has led to implementation of new clinical protocols in radiotherapy of gynecological carcinomas [18].

The limitations of our study include retrospective data collection and a small sample size; yet it is one of the few studies on this topic, which gives it significance. In our opinion, research on this topic should be continued in order to further examine the importance of modern radiotherapy techniques in the treatment of gynecological malignancies.

## Conclusion

Our study showed that differences between the compared clinical outcomes among patients treated with three-dimensional conformal radiation therapy and volumetric modulated arc therapy technique were statistically insignificant. However, our results demonstrated a positive trend in progression free survival in patients who underwent definitive radiotherapy/chemoradiotherapy, as well as better 4-year overall survival with volumetric modulated arc therapy.

## References

1. Sung H, Ferlay J, Siegel RL, Laversanne M, Soerjomataram I, Jemal A, et al. Global cancer statistics 2020: GLOBOCAN estimates of incidence and mortality worldwide for 36 cancers in 185 countries. *CA Cancer J Clin.* 2021;71(3):209-49.
2. Bailey HH, Chuang LT, duPont NC, Eng C, Foxhall LE, Merrill JK, et al. American Society of Clinical Oncology Statement: human papillomavirus vaccination for cancer prevention. *J Clin Oncol.* 2016;34(15):1803-12.
3. Miljuš D, Živković S, Božić Z, editors. Incidencija i mortalitet od raka u centralnoj Srbiji 2015. Beograd: Institut za javno zdravlja Srbije „Dr Milan Jovanović Batut“; 2017.
4. Lukovic J, Patil N, D'souza D, Millman B, Yaremko BP, Leung E, et al. Intensity-modulated radiation therapy versus 3D conformal radiotherapy for postoperative gynecologic cancer: are they covering the same planning target volume? *Cureus.* 2016;8(1):e467.
5. Ivanov O. Savremena radijaciona onkologija. 1st ed. Novi Sad: Univerzitet u Novom Sadu, Medicinski fakultet; 2020.
6. Tepper JE, Foote RL, Michalski JM, editors. Gunderson and Tepper's clinical radiation oncology. 5th ed. Philadelphia: Elsevier; 2021.
7. Heron DE, Gerszten K, Selvaraj RN, King GC, Sonnik D, Gallion H, et al. Conventional 3D conformal versus intensity-modulated radiotherapy for the adjuvant treatment of gynecologic malignancies: a comparative dosimetric study of dose-volume histograms. *Gynecol Oncol.* 2003;91(1):39-45.
8. Yu CX. Intensity-modulated arc therapy with dynamic multileaf collimation: an alternative to tomotherapy. *Phys Med Biol.* 1995;40(9):1435-49.
9. Davidson MT, Blake SJ, Batchelar DL, Cheung P, Mah K. Assessing the role of volumetric modulated arc therapy (VMAT) relative to IMRT and helical tomotherapy in the management of

localized, locally advanced, and post-operative prostate cancer. *Int J Radiat Oncol Biol Phys.* 2011;80(5):1550-8.

10. Macchia G, Deodato F, Cilla S, Cammelli S, Guido A, Ferioli M, et al. Volumetric modulated arc therapy for treatment of solid tumors: current insights. *Onco Targets Ther.* 2017;10:3755-72.

11. National Cancer Institute. NCI dictionary of cancer terms [Internet]. [cited 2022 Jun 14]. Available from: <https://www.cancer.gov/publications/dictionaries/cancer-terms>

12. Droge LH, von Sivers FF, Schirmer MA, Wolff HA. Conventional 3D conformal radiotherapy and volumetric modulated arc therapy for cervical cancer: comparison of clinical results with special consideration of the influence of patient- and treatment-related parameters. *Strahlenther Onkol.* 2021;197(6):520-7.

13. Lan ML, YU X, Xiao H, Zhou P, Hu N, Li J, et al. Clinical outcomes and toxicity of postoperative intensity-modulated versus three-dimensional conformal radiation therapy in patients with cervical cancer. *Asia Pac J Clin Oncol.* 2016;12(4):430-6.

14. Tsuchida K, Murakami N, Kato T, Okuma K, Okamoto H, Kashihara T, et al. Postoperative pelvic intensity-modulated radiation therapy reduced the incidence of late gastrointestinal complications for uterine cervical cancer patients. *J Radiat Res.* 2019;60(5):650-7.

Rad je primljen 25. VIII 2022.

Recenziran 21. XI 2022.

Prihvaćen za štampu 22. XII 2022.

BIBLID.0025-8105:(2022):LXXV:7-8:224-229.

15. Folkert MR, Shih KK, Abu-Rustum NR, Jewell E, Kollmeier MA, Makker V, et al. Postoperative pelvic intensity-modulated radiotherapy and concurrent chemotherapy in intermediate- and high-risk cervical cancer. *Gynecol Oncol.* 2013;128(2):288-93.

16. Isohashi F, Mabuchi S, Yoshioka Y, Seo Y, Suzuki O, Tamari K, et al. Intensity-modulated radiation therapy versus three-dimensional conformal radiation therapy with concurrent nedaplatin-based chemotherapy after radical hysterectomy for uterine cervical cancer: comparison of outcomes, complications, and dose-volume histogram parameters. *Radiat Oncol.* 2015;10:180.

17. Cozzi L, Dinshaw KA, Shrivastava SK, Mahantshetty U, Engineer R, Deshpande DD, et al. A treatment planning study comparing volumetric arc modulation with RapidArc and fixed field IMRT for cervix uteri radiotherapy. *Radiother Oncol.* 2008;89(2):180-91.

18. Knnap P, Eva B, Reseigh G, Gibbs A, Sim L, Daly T, et al. The role of volumetric modulated arc therapy (VMAT) in gynaecological radiation therapy: a dosimetric comparison of intensity modulated radiation therapy versus VMAT. *J Med Radiat Sci.* 2019; 66(1):44-53.



Garrison Outpatient Clinic, Kruševac<sup>1</sup>  
 Military Medical Academy, Clinic of Hematology, Belgrade<sup>2</sup>

Original study  
*Originalni naučni rad*  
 UDK 616-006.44-036.8:616.14-005.6  
 UDK 616-006.44-036.8:616.24-05  
<https://doi.org/10.2298/MPNS2208230M>

## MULTIPLE MYELOMA AND DEEP VEIN THROMBOSIS/PULMONARY THROMBOEMBOLISM – INCIDENCE AND RISK FACTORS

*MULTIPLI MIJELOMOM I DUBOKA VENSKA TROMBOZA/PLUĆNA TROMBOEMBOLIJA – UČESTALOST I FAKTORI RIZIKA*

Jovana MARINKOVIĆ<sup>1</sup> and Olivera TARABAR<sup>2</sup>

### Summary

**Introduction.** Deep vein thrombosis and pulmonary thromboembolism are among the most important causes of morbidity and mortality in cancer patients. They are common and serious complications that are affected by various risk factors. The aim of this study was to determine the incidence of thromboembolic complications and their association with risk factors in patients with newly diagnosed multiple myeloma. **Material and Methods.** A retrospective study included 32 patients and the following variables were collected: age, C-reactive protein, beta-2 microglobulin, hemoglobin, platelets, total proteins, nephrotic syndrome, fibrinogen, D-dimer, albumin, lactate dehydrogenase, creatinine, calcium, gender, performance status, type of multiple myeloma, clinical stage, and applied therapy. All variables were compared between two groups of patients: group with thromboembolic complications (deep venous thrombosis and pulmonary thromboembolism), and the group without these complications. **Results.** The study sample included 18 men and 14 women. The patients' age ranged from 36 to 73 years. Of the 32 patients, 6 had deep venous thrombosis of the lower extremities, and 2 patients had deep venous thrombosis and pulmonary thromboembolism. The only two biomarkers that showed an association with venous thromboembolism in our patients with myeloma were elevated levels of C-reactive protein and D-dimer. **Conclusion.** The incidence of thromboembolic complications in patients with newly diagnosed multiple myeloma was 25%. When making the diagnosis of myeloma, risk factors that were significantly associated with venous thromboembolism were elevated levels of C-reactive protein and D-dimer. The occurrence of venous thromboembolism in patients with multiple myeloma was not associated with significantly higher mortality compared to patients without venous thromboembolism.

**Key words:** Multiple Myeloma; Venous Thrombosis; Pulmonary Embolism; Risk Factors; C-Reactive Protein; Fibrin Fibrinogen Degradation Products; Incidence; Neoplasms

### Introduction

Multiple myeloma is a malignant disease from the group of B-cell proliferative diseases characterized by clonal proliferation and accumulation of pathologically altered plasma cells in the bone mar-

### Sažetak

**Uvod.** Duboka venska tromboza i plućna tromboembolija su među najvažnijim uzrocima morbiditeta i mortaliteta kod pacijenata sa karcinomom. Predstavljaju česte i ozbiljne komplikacije na koje utiču različiti faktori rizika. Cilj ovog rada je da se utvrdi učestalost tromboembolijskih komplikacija i njihova povezanost sa faktorima rizika kod pacijenata sa novodijagnostikovanim multiplim mijelomom. **Materijal i metode.** Retrospektivnom studijom obuhvaćena su 32 pacijenta i praćene su sledeće varijable: starost, C-reaktivni protein, beta-2-mikroglobulin, hemoglobin, trombociti, ukupni proteini, nefrotski sindrom, fibrinogen, D-dimer, albumin, laktat dehidrogenaza, kreatinin, kalcijum, pol, performans status, tip multiplog mijeloma, klinički stadijum i primenjena terapija. Sve ove varijable poređene su između dve grupe: grupe pacijenata sa tromboembolijskim komplikacijama (duboka venska tromboza i plućna tromboembolija) i grupe pacijenata bez navedenih komplikacija. **Rezultati.** Unutar posmatranog uzorka bilo je 18 muškaraca i 14 žena. Starost pacijenata je bila od 36 do 73 godine. Od 32 pacijenta, šest je imalo duboku vensku trombozu donjih ekstremiteta, a dva pacijenta udruženu duboku vensku trombozu i plućnu tromboemboliju. Jedina dva biomarkera koja su pokazala povezanost sa venskim tromboembolizmom u našoj grupi pacijenata sa mijelomom bili su povišeni nivoi C-reaktivnog proteina i D-dimera. **Zaključak.** Incidencija tromboembolijskih komplikacija kod pacijenata sa novodijagnostikovanim multiplim mijelomom iznosila je 25%. Faktori rizika pri dijagnozi mijeloma koji su bili značajno udruženi sa pojavom venskog tromboembolizma su povišene vrednosti C-reaktivnog proteina i D-dimera. Pojava venskog tromboembolizma kod pacijenata sa multiplim mijelomom nije bila povezana sa značajno većim mortalitetom u poređenju sa pacijentima bez venskog tromboembolizma.

**Ključne reči:** multipli mijelom; venska tromboza; plućna embolija; faktori rizika; CRP; D-dimer; incidenca; karcinomi

row [1]. The annual incidence of multiple myeloma is up to 3 per 100,000 individuals, accounting for about 1% of all diagnosed neoplasms and 10% of all hematologic malignancies (second only to non-Hodgkin's lymphoma). In Europe, 40,000 new cases were diagnosed in 2015, and it is estimated that

**Abbreviations**

VRd	– bortezomib, lenalidomide, and dexamethasone
VTE	– venous thromboembolism
DVT	– deep venous thrombosis
PTE	– pulmonary thromboembolism
VAD	– vincristine, doxorubicin and dexamethasone
CRP	– C-reactive protein
$\beta$ 2M	– $\beta$ -2 microglobulin
LDH	– lactate dehydrogenase
CS	– clinical stage
PS	– performance status
BJ	– Bence-Jones type

the number will increase to 46,000 by 2025 [2]. The estimated world-wide 5-year prevalence is approximately 230,000 patients [3]. The five-year survival rate varies from 23 – 47% [4]. The diagnosis of multiple myeloma is based on the presence of more than 10% of pathological monoclonal plasma cells in the bone marrow, serum/urine monoclonal protein, one or more parameters indicating organ dysfunction caused by myeloma activity (calcium elevation, renal dysfunction, anemia and bone disease), and presence of one or more biomarkers of active diseases [5].

Typically, patients are treated with approximately 3 to 4 cycles of induction therapy with bortezomib, lenalidomide, and dexamethasone (VRd) prior to stem cell harvest [6]. In patients under the age of 65 years without pronounced comorbidities after introductory triplet therapy, the treatment is continued with high-dose chemotherapy based on melphalan and autologous hematopoietic stem cell transplantation [7].

Venous thromboembolism (VTE) is the third most prevalent acute cardiovascular syndrome after myocardial infarction and stroke, and it is associated with a significant disease burden [8]. The VTE includes deep vein thrombosis (DVT) and pulmonary thromboembolism (PTE) and it is an important cause of morbidity and mortality among patients with cancer [9]. Results of a recent population-based cohort study showed that the presence of cancer is associated with a 9-fold increased risk of VTE [10]. It is estimated that approximately 4 – 20% of cancer patients will experience VTE at some stage, with the rate being the highest in the initial period following the diagnosis. Annually, 0.5% of cancer patients will experience thrombosis, compared with a 0.1% incidence rate in the general population [11]. In the long term, VTE is a chronic disease and about 30% of all patients with VTE have a recurrence within 10 years [12]. The pathophysiology of venous thrombosis has been famously described by Rudolf Virchow, known as the Virchow's triad, which includes stasis, endothelial injury, and hypercoagulability [13]. The pathogenesis of DVT in cancer patients is multifactorial. All aspects of the Virchow's triad, prolonged immobilization of the patient, application of various therapies (chemotherapy, growth factors, and angiogenesis inhibitors) and surgical interventions that lead to endothelial damage and hypercoagulability associated with cancer, contribute to significantly more frequent DVT in patients with malignant diseases [14].

Several patient-, treatment-, and tumor-related factors affect the risk of VTE in cancer patients [15]. Reasons for higher risk of VTE in the first few months after cancer diagnosis are likely related to intensive therapy (surgical, radiation, and systemic) and a higher tumor burden at the time of diagnosis that decreases with effective therapy. It should also be noted that older studies did not adjust for the competing risk of death when estimating the cumulative incidence of cancer-associated thrombosis and therefore may have overestimated early incidence of some particularly lethal tumors. The overall incidence of VTE in cancer patients has continued to increase over time [16]. This may be due to multiple factors, including increased detection by serial imaging for staging purposes, changes in treatment, which may be more thrombogenic, and longer survival of patients with multiple cancers, therefore increasing an individual's time at risk of VTE [17]. More recently, tumor genetic characteristics also appear to play a role in VTE formation, since genetic profiling demonstrated that mutations in K-ras in colon and lung cancer show an association with increased risk of VTE [18]. The first report of an increased incidence of VTE in patients with newly diagnosed multiple myeloma dates back to 1999. The incidence was 10% and these were patients receiving vincristine, doxorubicin and dexamethasone (VAD) or high doses of cyclophosphamide. Since then, numerous papers have been published on the incidence of thromboembolic complications in patients with multiple myeloma, whether newly diagnosed, refractory or relapsing [19]. Despite thromboprophylaxis, the incidence of VTE with contemporary immunomodulatory drug-based regimens is 6 – 7% [20].

Patients with cancer who survive VTE are at risk of the consequences of the initial event, such as increased bleeding, post-thrombotic syndrome, pulmonary hypertension, and recurrent VTE. The diagnosis of VTE remains a challenge, since it is often asymptomatic. In one prospective study of hospitalized patients, the rate of pulmonary thromboembolism was 1%, but the diagnosis was not made in 70% of patients who died of acute PE, which was detected at autopsy. However, VTE is one of the most common causes that can prevent and reduce the mortality of cancer patients, which makes prophylaxis crucial in this high-risk group of patients. Effective thromboprophylaxis has been shown to reduce morbidity and mortality due to cancer-related thrombosis. According to international guidelines, low molecular weight heparin is the first choice for initial and long-term treatment of VTE and has largely replaced unfractionated heparin and oral vitamin K antagonists, such as warfarin, due to a 50% lower risk of recurrent VTE and similar rates of major bleeding [21–23].

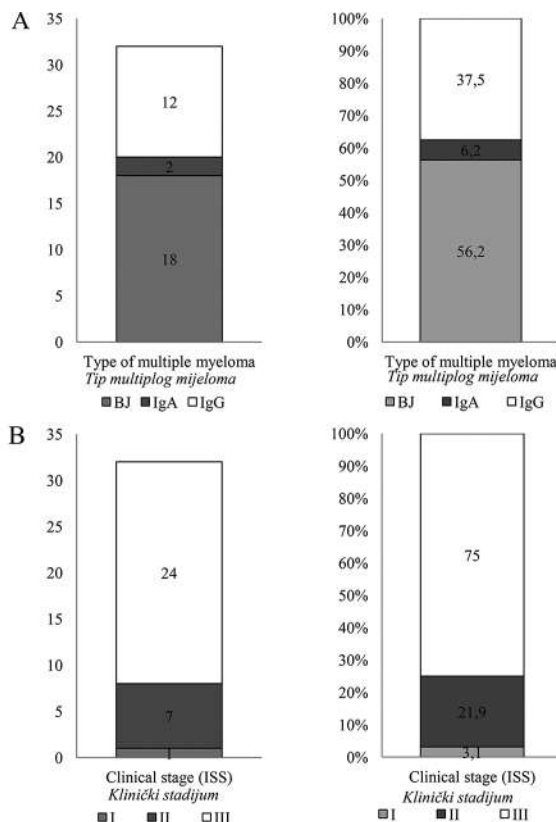
The aims of our study were to determine the incidence of thromboembolic complications (DVT and pulmonary thromboembolism) in patients with newly diagnosed multiple myeloma and to examine the association of risk factors in the diagnosis of the disease with the occurrence of DVT/pulmonary thromboembolism.

## Material and Methods

The retrospective study included 32 patients with newly diagnosed multiple myeloma who were diagnosed, treated and systematically followed-up at the Hematology Clinic of the Military Medical Academy, Belgrade, Serbia. The diagnosis and treatment of multiple myeloma was carried out according to the current European Society for Medical Oncology guidelines in the period from 2014 to 2017. This study was approved by the relevant Ethics Committee. The following characteristics were monitored: age, C-reactive protein (CRP),  $\beta 2$  microglobulin ( $\beta 2M$ ), hemoglobin, platelets, total protein, nephrotic syndrome, fibrinogen, D-dimer, albumin, lactate dehydrogenase (LDH), creatinine and calcium. Non-parametric variables monitored in the study were: gender, performance status (PS) (0 or 1 vs  $\geq 2$ ), type of multiple myeloma (immunoglobulin A, immunoglobulin M, Bence-Jones), clinical stage (CS). According to the international prognostic index patients were stratified into stages I – III, and applied therapy (based on thalidomide, bortezomib and combined VAD chemotherapy). All patients receiving VAD polychemotherapy had a central venous access. All these variables were compared between two groups: group of patients with thromboembolic complications (DVT and PTE), and group of patients without these complications. Statistical data processing was performed using the software package SPSS 20. The calculated parameters for numerical features were described as: mean, standard deviation, and median; in the analysis of the non-parametric features, the characteristics were expressed as a percentage. The frequency of non-parametric phenomena among groups was compared with the Chi-square test (Cross table, Chi-square). Student's t-test for two independent samples compared the values of numerical features by groups. The statistically significant difference was set at  $p < 0.05$ .

## Results

Within the observed sample of 32 patients with multiple myeloma, there were 18 men (56.3%) and



**Graph 1.** Other characteristics of patients with multiple myeloma show that more than 56% of patients had Bence-Jones type myeloma (A), the most common clinical stage was the third in 75% of patients (B).

**Grafikon 1.** Ostale karakteristike pacijenata sa multipim mijelomom pokazuju da je više od 56% pacijenata imalo Bens Dožnsonov mijelom tipa (A), najčešći klinički stadijum je bio treći kod 75% pacijenata (B)

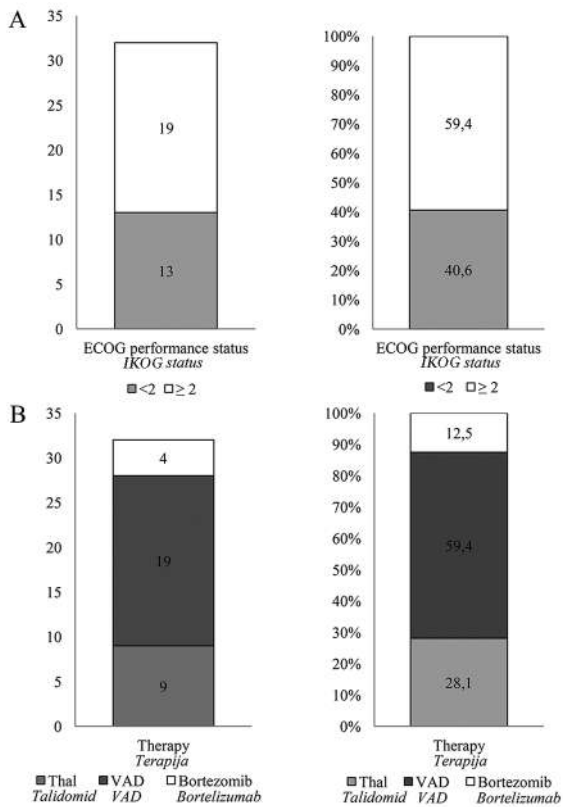
Legenda: BJ – Bens Džonsonov

14 women (43.7%). The laboratory test results at the time of diagnosis of myeloma (**Table 1**) showed elevated CRP in 17 patients (53.1%), 30 patients had

**Table 1.** Laboratory test results at the time of multiple myeloma diagnosis

**Tabela 1.** Laboratorijske karakteristike pacijenata u vreme dijagnoze multiplog mijeloma

Variables/Varijable	Value/Vrednost	Number of patients/Broj pacijenata
CRP/C-reaktivni protein	> 5 mg/l	17 (53.1%)
$\beta 2M$ /Beta 2 mikroglobulin	> 2.2 mg/l	30 (93.8%)
Hemoglobin/Hemoglobin	< 100 g/l	21 (65.6%)
Platelets/Trombociti	> $350 \times 10^9/l$	3 (9.4%)
Total proteins/Ukupni proteini	> 84 g/l	13 (40.6%)
Nephrotic syndrome/Nefrotski sindrom	> 3.5 g/l	15 (46.9%)
Fibrinogen/Fibrinogen	> 4.5 g/l	15 (46.9%)
D-dimer/D-dimer	> 0.5 ng/ml	18 (56.2%)
Albumins/Albumini	< 30 g/l	17 (53.1%)
Lactate dehydrogenase/Laktat dehidrogenaza	> 280 IJ/l	18 (56.2%)
Creatinine/Kreatinin	> 177 mmol/l	13 (40.6%)
Calcium/Kalcijum	> 2.75 mmol/l	8 (25%)



**Graph 2.** Eastern Cooperative Oncology Group (ECOG) performance status of patients with multiple (A) and most commonly used therapy (B)

**Grafikon 2.** Istočna korporativna onkološka grupa (IKOG) performans status pacijenata sa multiplim mijelomom (A) i terapijski pristupi (B)

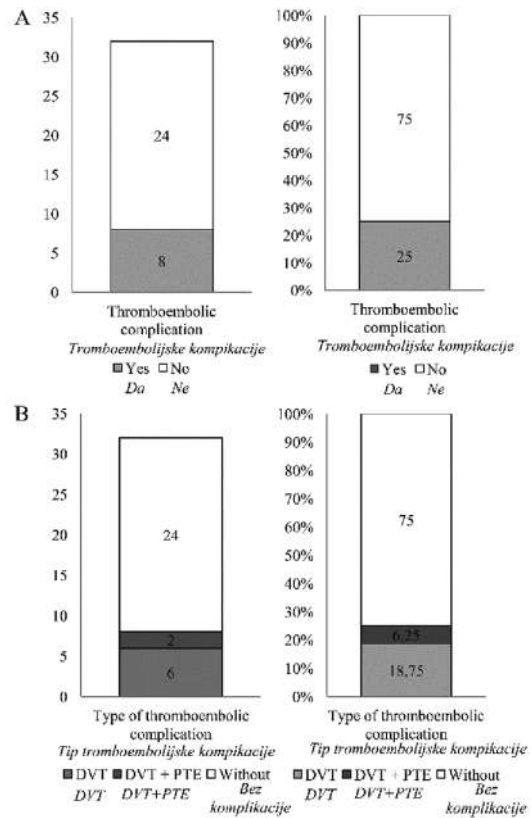
Legenda: IKOG – Istočna korporativna onkološka grupa, VAD – vinskristin, doksorubicin, deksametazon

elevated  $\beta 2M$  and 18 patients (56.2%) had elevated levels of D-dimer ( $> 0.5$  ng/ml). Also, more than half of the patients had anemia (65.6%), hypoalbuminemia (53.1%) and elevated LDH (56.2%).

Slightly more than 56% of patients had Bence-Jones type (BJ) myeloma; the most common CS was III in 75% of patients, and unfavorable PS was found in 59.4% (Graph 1). The most commonly used therapy was the VAD protocol in 19 patients, thalidomide-based therapy in 9 patients, while bortezomib-based therapy was the least common in 4 patients (Graph 2).

Of the 32 patients, some type of thromboembolic complication was confirmed in 8 (25.0%), DVT of the lower extremities was confirmed in 6 patients, and 2 patients had combined DVT and PTE. None of the patients with central venous access developed DVT at the site of placement. In 3 patients, DVT occurred in the first month after the diagnosis of the disease, while the other 5 developed thrombosis during treatment ranging from 3 to 5 months (Graph 3).

When comparing the characteristics of patients with DVT/PTE in relation to the characteristics of patients without thrombosis (Table 2), it can be seen that



**Graph 3.** Incidence of thromboembolic complications in patients with multiple myeloma

**Grafikon 3.** Incidencija tromboembolijskih komplikacija kod pacijenata sa multiplim mijelomom

Legenda: DTV – duboka venska tromboza, PTE – plućna tromboembolija

elevated CRP values were statistically significantly more often present in patients with thrombosis compared to patients without DVT ( $p = 0.041$ ), i.e. 7 of 8 patients with DVT had elevated CRP levels. Also, it can be noticed that all 8 patients with DVT had an increased level of D-dimer, which showed a statistically significant difference compared to patients without DVT ( $p = 0.004$ ). Comparing the characteristics of patients with DVT/PTE in relation to the characteristics of patients without thrombosis, no statistically significant difference was observed between sexes, levels of  $\beta 2M$ , hemoglobin, platelets, total protein, albumin, fibrinogen, creatinine, calcium, and 24-h proteinuria.

Furthermore, there was no statistically significant difference in the development of DVT in relation to PS, CS, or in relation to the applied therapy (thalidomide versus bortezomib versus VAD therapy). No difference in mortality was observed between patients whose course of disease was complicated by DVT, compared to patients without DVT.

### Discussion

The association of cancer and thromboembolic complications, including DVT and PTE, is a well-

**Table 2.** Comparative characteristics of patients with multiple myeloma in relation to the presence of deep venous thrombosis/venous thromboembolism**Tabela 2.** Usporedne karakteristike pacijenata sa multiplim mijelomom u odnosu na prisustvo duboke venske tromboze/plućne tromboembolije

Variables Varijable		DVT/PTE		p/p
		Yes/Da	No/Ne	
Gender Pol	Male/Muški	6 (33.3)	12 (66.7)	0.412
	Female/Ženski	2 (14.3)	12 (85.7)	
CRP/C-reaktivni protein	> 5 mg/l	7 (41.2)	10 (58.8)	<b>0.041</b>
	≤ 5 mg/l	1 (6.7)	14 (93.3)	
β2M/Beta 2 mikroglobulin	> 2.2 mg/l	8 (26.7)	22 (73.3)	1.000
	≤ 2.2 mg/l	0 (0.0)	2 (100.0)	
Hemoglobin/Hemoglobin	< 100 g/l	3 (27.3)	8 (72.7)	1.000
	≥ 100 g/l	5 (23.8)	16 (76.2)	
Platelets/Trombociti	> 350 × 10 <sup>9</sup> /l	1 (33.3)	2 (66.7)	1.000
	≤ 350 × 10 <sup>9</sup> /l	7 (24.1)	22 (75.9)	
Total proteins/Ukupni proteini	> 84 g/l	4 (30.8)	9 (69.2)	0.684
	≤ 84 g/l	4 (21.1)	15 (78.9)	
Nephrotic syndrome/Nefrotski sindrom	Yes/Da	3 (20.0)	12 (80.0)	0.691
	No/Ne	5 (29.4)	12 (70.6)	
Fibrinogen/Fibrinogen	> 4.5 g/l	5 (33.3)	10 (66.7)	0.423
	≤ 4.5 g/l	3 (17.6)	14 (82.4)	
D-dimer/D-dimer	> 0.5 ng/ml	8 (44.4)	10 (55.6)	<b>0.004</b>
	≤ 0.5 ng/ml	0 (0.0)	14 (100.0)	
Albumins/Albumini	< 30 g/l	3 (17.6)	14 (82.4)	0.423
	≥ 30 g/l	5 (33.3)	10 (66.7)	
LDH/Laktat dehidrogenaza	> 280 IJ/l	5 (27.8)	13 (72.2)	1.000
	≤ 280 IJ/l	3 (21.4)	11 (78.6)	
Creatinine/Kreatinin	> 177 mmol/l	4 (30.8)	9 (69.2)	0.684
	≤ 177 mmol/l	4 (21.1)	15 (78.9)	
Calcium/Kalcijum	> 2.75 mmol/l	2 (25.0)	6 (75.0)	1.000
	≤ 2.75 mmol/l	6 (25.0)	18 (75.0)	

known complication in the treatment of oncology and hematology patients. Risk factors of DVT in cancer patients are related to: a) characteristics of the tumor itself, b) characteristics of the patient and associated comorbidities, c) used therapy, and d) various biomarkers.

Similar to other malignant diseases, common risk factors (e.g. diseases of cardiovascular origin, long-term immobility, infections) play a significant role in the pathogenesis of thrombosis in myeloma. In addition to paraproteinemia, which contributes to blood hyperviscosity, various mechanisms contribute to hypercoagulability, such as the interaction of neoplastic plasma cells, bone marrow stromal cells, and effects of multiple inflammatory cytokines on the endothelial cells, most commonly interleukin-6 and vascular endothelial growth factor. High levels of paraproteins affect fibrin polymerization and fibrinolysis. Disturbed balance between procoagulant and anticoagulant factors, impaired protein C activity due to acquired resistance to activated protein C are some of the known and shown mechanisms in the pathogenesis of myeloma thrombosis [24]. In our group of subjects with newly diagnosed myeloma, the incidence of VTE was 25%, which is in line with the results of

previously presented studies. The results of several studies on myeloma that analyzed the association of VTE with the clinical characteristics of the disease showed that advanced myeloma and the degree of hyperviscosity were parameters associated with a more frequent occurrence of thromboembolic complications. In our study, there was no statistically significant difference in the incidence of VTE in relation to CS, elevated total proteins and the presence of nephrotic syndrome. Although it was observed that 7 of 8 patients with VTE belonged to CS III, no statistically significant difference in the occurrence of thrombosis was observed in relation to CS I and II ( $p = 0.731$ ).

The results of published studies also show that hematological blood parameters, such as increased leukocyte and platelet counts and decreased hemoglobin levels, may be associated with a significantly higher incidence of DVT [14]. However, in our study, no association was observed between platelet count and decreased hemoglobin levels with a more frequent occurrence of DVT. Also, other examined parameters (albumin, creatinine, fibrinogen, calcium level, β2M and LDH) were not associated with the occurrence of DVT. One of the risk factors for the development of DVT as a complication in patients

with multiple myeloma is unfavorable PS ( $\geq 2$ ), which may be associated with severe damage/fractures of the flat bones and a pronounced pain syndrome that binds patients to bed. However, although almost 60% of patients in our myeloma group had PS  $\geq 2$ , no significant difference in DVT was observed compared to patients with PS 0 and 1.

The only two biomarkers that showed an association with DVT in our myeloma patients were elevated levels of CRP and D-dimer. Our results showed that elevated CRP levels were found in 7 out of 8 patients with DVT ( $p = 0.041$ ). The CRP is known to be a marker of systemic inflammation. Although some studies have confirmed its association with DVT in cancer patients, other studies in patients with chronic myeloproliferative neoplasms have not confirmed its importance [14]. In our study, all patients with myeloma and VTE had elevated levels of D-dimer ( $p = 0.004$ ) which is consistent with the results of some studies [25]. As D-dimer is the primary degradation product of fibrin and reflects the global activation of the coagulation and fibrinolytic system, it is expected that its increased level is associated with thromboembolic complications, which was shown in our study.

Immunomodulatory/cereblon-binding agents are the basic therapy for multiple myeloma at all phases of therapy. While these agents are generally well tolerated, increased risk of VTE presents a clinical challenge. This challenge is compounded by the lack of rigor, prospective trials of thromboprophylactic regimens for VTE prevention in these vulnerable patients [26]. The highest risk of VTE in multiple myeloma patients is associated with receiving immunomodulatory agents such as thalidomide or lenalidomide, which is exacerbated by the concomitant use of high dose steroids [27]. The incidence of thrombosis in multiple myeloma is less than 5% for thalidomide alone, versus 10 - 20% for thalidomide with dexamethasone and 20 - 40% for thalidomide with chemotherapy [28]. In a randomized trial on lenalidomide with either high-dose or low-dose dexamethasone, the incidence of VTE was 26% and 12%, respectively [29].

The patients included in this study mostly received VAD polychemotherapy (19 patients), followed by combination therapy based on thalidomide (combinations with dexamethasone and cyclophosphamide or with dexamethasone and doxorubicin) (9 patients). Bortezomib-based therapy was the least commonly used (4 patients). There was no statistically significant difference in the incidence of DVT in regard to the applied therapy ( $p = 0.841$ ), i.e. 4 out

of 15 patients on VAD therapy, 3 out of 6 patients on thalidomide and 1 out of 4 patients on bortezomib developed DVT. Considering the applied combination therapy, the incidence of DVT in our patients was similar to that in other study groups. Bortezomib, a proteasome inhibitor, is the drug that has so far shown the lowest incidence of thromboembolic complications (0 - 1%), either as monotherapy or in combination with dexamethasone. Data from studies that link VTE and inferior overall survival in multiple myeloma patients are conflicting, and a clear association has not been established [30, 31]. Although it has been shown that DVTs are associated with malignant diseases, being the leading cause of death after cancer, our study showed no significant difference in the survival of patients with myeloma in relation to the presence or absence of DVT.

Given that the combined triplet therapy with thalidomide and lenalidomide is accompanied by a significant rate of thromboembolic complications, the American Society of Clinical Oncologists and the European Society of Oncologists recommend preventive use of aspirin or low molecular weight heparin in low-risk and high-risk patients [32, 33]. However, direct-acting oral anticoagulants are becoming increasingly popular. Their profile is favorable, as secondary to safety and efficacy, they are administered orally and do not require routine monitoring. They are currently licensed for use in the treatment of cancer-associated thrombosis [34-36].

## Conclusion

The incidence of thromboembolic complications (deep vein thrombosis/pulmonary thromboembolism) in patients with newly diagnosed multiple myeloma was 25%. When making the diagnosis of myeloma, risk factors that were significantly associated with the occurrence of deep vein thrombosis were elevated C-reactive protein and D-dimer.

There was no statistically significant difference in the occurrence of deep vein thrombosis in relation to the type of myeloma, clinical stage of the disease, values of hematological blood parameters,  $\beta$ -2 microglobulin, lactate dehydrogenase, fibrinogen, creatinine levels, total protein, albumin, performance status, or the applied therapy. The occurrence of deep vein thrombosis in patients with multiple myeloma was not associated with significantly higher mortality compared to patients without deep vein thrombosis.

## References

1. Greer JP, Rodgers GM, Glader BE, Arber DA, Means RM, List AF, et al. *Wintrobe's clinical hematology*. 14th ed. Philadelphia: Wolters Kluwer; 2018.
2. Bray F, Ferlay J, Soerjomataram I, Siegel RL, Torre LA, Jemal A. Global cancer statistics 2018: GLOBOCAN estimates of incidence and mortality worldwide for 36 cancers in 185 countries. *CA Cancer J Clin*. 2018;68(6):394-424.
3. Cid Ruzafa J, Merinopoulou E, Baggaley RF, Leighton P, Werther W, Felici D, et al. Patient population with multiple myeloma and transitions across different lines of therapy in the USA: an epidemiologic model. *Pharmacoepidemiol Drug Saf*. 2016;25(8):871-9.
4. Kazandjian D. Multiple myeloma epidemiology and survival: a unique malignancy. *Semin Oncol*. 2016;43(6):676-81.
5. Rajkumar SV, Dimopoulos MA, Palumbo A, Blade J, Merlini G, Mateos MV, et al. International Myeloma Working Group

updated criteria for the diagnosis of multiple myeloma. *Lancet Oncol.* 2014;15(12):e538-48.

6. Durie BGM, Hoering A, Abidi MH, Rajkumar SV, Epstein J, Kahanic SP, et al. Bortezomib with lenalidomide and dexamethasone versus lenalidomide and dexamethasone alone in patients with newly diagnosed myeloma without intent for immediate autologous stem-cell transplant (SWOG S0777): a randomised, open-label, phase 3 trial. *Lancet.* 2017;389(10068):519-27.

7. Moreau P, San Miguel J, Sonneveld P, Mateos MV, Zamagni E, Avet-Loiseau H, et al. Multiple myeloma: ESMO Clinical Practice Guidelines for diagnosis, treatment and follow-up. *Ann Oncol.* 2017;28(Suppl 4):iv52-61.

8. Schulman S, Ageno W, Konstantinides SV. Venous thromboembolism: past, present and future. *Thromb Haemost.* 2017;117(7):1219-29.

9. Lyman GH, Culakova E, Poniewierski MS, Kuderer NM. Morbidity, mortality and costs associated with venous thromboembolism in hospitalized patients with cancer. *Thromb Res.* 2018;164 Suppl 1:S112-8.

10. Mulder FI, Horváth-Puhó E, van Es N, van Laarhoven HWM, Pedersen L, Moik F, et al. Venous thromboembolism in cancer patients: a population-based cohort study. *Blood.* 2021;137(14):1959-69.

11. Meyer HJ, Wienke A, Surov A. Incidental pulmonary embolism in oncologic patients-a systematic review and meta-analysis. *Support Care Cancer.* 2021;29(3):1293-302.

12. Sista AK, Klok FA. Late outcomes of pulmonary embolism: the post-PE syndrome. *Thromb Res.* 2018;164:157-62.

13. McLendon K, Goyal A, Attia M. Deep venous thrombosis risk factors. In: *StatPearls.* Treasure Island: StatPearls Publishing; 2022.

14. Ay C, Pabinger I, Cohen AT. Cancer-associated venous thromboembolism: burden, mechanisms, and management. *Thromb Haemost.* 2017;117(2):219-30.

15. Leiva O, Newcomb R, Connors JM, Al-Samkari H. Cancer and thrombosis: new insights to an old problem. *J Med Vasc.* 2020;45(6S):6S8-16.

16. Khorana AA, Francis CW, Culakova E, Kuderer NM, Lyman GH. Frequency, risk factors, and trends for venous thromboembolism among hospitalized cancer patients. *Cancer.* 2007;110(10):2339-46.

17. Timp JF, Braekkan SK, Versteeg HH, Cannegieter SC. Epidemiology of cancer-associated venous thrombosis. *Blood.* 2013;122(10):1712-23.

18. NCCN Guidelines Version 1. Cancer-associated venous thromboembolic disease. Plymouth: National Comprehensive Cancer Network; 2019.

19. Barlogie B, Jagannath S, Desikan KR, Mattox S, Vesole D, Siegel D, et al. Total therapy with tandem transplants for newly diagnosed multiple myeloma. *Blood.* 1999;93(1):55-65.

20. Chakraborty R, Bin Riaz I, Malik SU, Marneni N, Mejia Garcia A, Anwer F, et al. Venous thromboembolism risk with contemporary lenalidomide-based regimens despite thromboprophylaxis in multiple myeloma: a systematic review and meta-analysis. *Cancer.* 2020;126(8):1640-50.

21. Palumbo A, Rajkumar SV, Dimopoulos MA, Richardson PG, San Miguel J, Barlogie B, et al. Prevention of thalidomide-

and lenalidomide-associated thrombosis in myeloma. *Leukemia.* 2008;22(2):414-23.

22. Lee AYY, Kamphuisen PW, Meyer G, Bauersachs R, Janas MS, Jarner MF, et al. Tinzaparin vs warfarin for treatment of acute venous thromboembolism in patients with active cancer: a randomized clinical trial. *JAMA.* 2015;314(7):677-86.

23. Akl EA, Kahale L, Barba M, Neumann I, Labedi N, Terrenato I, et al. Anticoagulation for the long-term treatment of venous thromboembolism in patients with cancer. *Cochrane Database Syst Rev.* 2014;(7):CD006650.

24. Franchini M. Thromboembolic risk in hematological malignancies. *Clin Chem Lab Med.* 2015;53(8):1139-47.

25. Posch F, Riedl J, Reitter EM, Crowther MJ, Grilz E, Quehenberger P, et al. Dynamic assessment of venous thromboembolism risk in patients with cancer by longitudinal D-dimer analysis: a prospective study. *J Thromb Haemost.* 2020;18(6):1348-56.

26. Storrar NPF, Mathur A, Johnson PRE, Roddie PH. Safety and efficacy of apixaban for routine thromboprophylaxis in myeloma patients treated with thalidomide- and lenalidomide-containing regimens. *Br J Haematol.* 2019;185(1):142-4.

27. Kekre N, Connors JM. Venous thromboembolism incidence in hematologic malignancies. *Blood Rev.* 2019;33:24-32.

28. Swan D, Rocci A, Bradbury C, Thachil J. Venous thromboembolism in multiple myeloma - choice of prophylaxis, role of direct oral anticoagulants and special considerations. *Br J Haematol.* 2018;183(4):538-56.

29. Zamagni E, Brioli A, Tacchetti P, Zannetti B, Pantani L, Cavo M. Multiple myeloma, venous thromboembolism, and treatment-related risk of thrombosis. *Semin Thromb Hemost.* 2011;37(3):209-19.

30. De Stefano V, Za T, Rossi E. Venous thromboembolism in multiple myeloma. *Semin Thromb Hemost.* 2014;40(3):338-47.

31. Schoen MW, Carson KR, Luo S, Gage BF, Li A, Afzal A, et al. Venous thromboembolism in multiple myeloma is associated with increased mortality. *Res Pract Thromb Haemost.* 2020;4(7):1203-10.

32. Anderson SM, Beck B, Sterud S, Lockhorst R, Ngorsuraches S. Evaluating the use of appropriate anticoagulation with lenalidomide and pomalidomide in patients with multiple myeloma. *J Oncol Pharm Pract.* 2019;25(4):806-12.

33. Takaishi K, Tsukamoto S, Ohwada C, Takeuchi M, Kawasaki Y, Nagai Y, et al. Low incidence of thromboembolism in multiple myeloma patients receiving immunomodulatory drugs; a retrospective single-institution analysis. *J Thromb Thrombolysis.* 2019;48(1):141-8.

34. Raskob GE, van Es N, Verhamme P, Carrier M, Di Nisio M, Garcia D, et al. Edoxaban for the treatment of cancer-associated venous thromboembolism. *N Engl J Med.* 2018;378(7):615-24.

35. Carrier M, Abou-Nassar K, Mallick R, Tagalakis V, Shivakumar S, Schattner A, et al. Apixaban to prevent venous thromboembolism in patients with cancer. *N Engl J Med.* 2019;380(8):711-9.

36. Park DY, Poudel SK, Jia X, Wilks ML, Pinkava V, O'Brien M, et al. Clinical outcomes with direct oral anticoagulants compared to low molecular weight heparins in the treatment of cancer-associated venous thromboembolism. *Blood.* 2018;132(Suppl 1):1237.

Rad je primljen 11. VII 2022.

Recenziran 23. X 2022.

Prihvaćen za štampu 23. X 2022.

BIBLID.0025-8105:(2022):LXXV:7-8:230-236.

## PROFESSIONAL ARTICLES

### STRUČNI ČLANCI

University of Novi Sad, Faculty of Medicine Novi Sad  
Department of Pathophysiology and Laboratory Medicine<sup>1</sup>  
Clinical Center of Vojvodina, Novi Sad  
Center of Laboratory Medicine<sup>2</sup>  
Clinic of Neurology<sup>3</sup>

Professional article  
*Stručni članak*  
UDK 616.832-004.2:616-008.9  
<https://doi.org/10.2298/MPNS2208237S>

## TRIGLYCERIDE GLUCOSE INDEX IN PATIENTS WITH MULTIPLE SCLEROSIS

### INDEKS TRIGLICERIDA I GLUKOZE KOD PACIJENATA SA MULTIPLOM SKLEROZOM

Maša SLADOJEVIĆ<sup>1,2</sup>, Tanja ŠAŠIĆ OSTOJIC<sup>1,2</sup>, Stanislava NIKOLIĆ<sup>1,2</sup>,  
Željko ŽIVANOVIĆ<sup>1,3</sup>, Branislava ILINČIĆ<sup>1,2</sup> and Velibor ČABARKAPA<sup>1,2</sup>

#### Summary

**Introduction.** Multiple sclerosis is a chronic, inflammatory disease of the central nervous system characterized by areas with inflammatory changes associated with demyelination. Cholesterol is a significant structural component of the central nervous system incorporated into the myelin sheath. The aim of study was to examine values of lipid status parameters in patients with multiple sclerosis and the correlation between these parameters and the triglyceride glucose index. **Material and Methods.** A retrospective study included 28 patients with multiple sclerosis. Medical records of the Clinic of Neurology and databases of the Center of Laboratory Medicine, Clinical Center of Vojvodina were analyzed. Based on the obtained data of the glycaemic index and lipid profile, triglyceride glucose index was calculated. **Results.** Borderline elevated values of total cholesterol and low-density cholesterol ( $5.25 \pm 1.08$  mmol/L;  $3.90 \pm 4.54$ ) were found in patients with multiple sclerosis. Linear correlation analysis showed a statistically positive correlation between triglyceride glucose index and total cholesterol ( $r = 0.572$ ;  $p = 0.01$ ), low-density cholesterol ( $r = 0.256$ ;  $p = 0.05$ ) and low-density cholesterol to high-density cholesterol ratio ( $r = 0.502$ ;  $p = 0.01$ ). No statistically significant correlation between triglyceride glucose index and high-density cholesterol was observed. **Conclusion.** The examined group with multiple sclerosis had borderline elevated values of total cholesterol and low-density cholesterol. There is a significant correlation between the triglyceride glucose index and values of total cholesterol, low-density cholesterol, as well as the low-density cholesterol to high-density cholesterol ratio.

**Key words:** Multiple Sclerosis; Triglycerides; Blood Glucose; Lipids; Glycaemic Index; Insulin Resistance; Cholesterol, LDL; Cholesterol, HDL

#### Introduction

Demyelinating diseases are disorders of the central and peripheral nervous system which are char-

#### Sažetak

**Uvod.** Multipla skleroza je hronično, inflamatorno oboljenje centralnog nervnog sistema koje karakterišu izolovana područja zapaljenjskih promena udruženih sa demijelinizacijom. Unutar centralnog nervnog sistema, holesterol je većinski inkorporiran u mijelinski omotač, te predstavlja značajnu strukturnu komponentu. Cilj rada bilo je ispitivanje vrednosti parametara lipidskog statusa kod pacijenata obolelih od multiple skleroze i stepena povezanosti navedenih parametara sa indeksom triglicerida i glukoze. **Materijal i metode.** Retrospektivna studija obuhvatila je 28 pacijenata obolelih od multiple skleroze. Uvidom u medicinsku dokumentaciju Klinike za neurologiju i baze podataka Centra za laboratorijsku medicinu Kliničkog centra Vojvodine preuzete su izmerene vrednosti glikemije u bazalnim uslovima, vrednosti parametara lipidskog statusa i izračunata je vrednost indeksa triglicerida i glukoze. **Rezultati.** Kod obolelih od multiple skleroze uočavaju se granično povišene vrednosti ukupnog holesterola i holesterola niske gustine ( $5,25 \pm 1,08$  mmol/l;  $3,90 \pm 4,54$ ). Linearnom korelacionom analizom triglicerida i glukoze utvrđena je statistički pozitivna korelacija indeksa sa vrednostima ukupnog holesterola ( $r = 0,572$ ;  $p = 0,01$ ), holesterola niske gustine ( $r = 0,256$ ;  $p = 0,05$ ), i vrednostima odnosa holesterola niske i visoke gustine ( $r = 0,502$ ;  $p = 0,01$ ). Nije uočena statistički značajna korelacija indeksa triglicerida i glukoze sa vrednostima holesterola visoke gustine. **Zaključak.** Ispitivana grupa imala je granično povišene vrednosti ukupnog i holesterola niske gustine. Postoji značajna korelacija indeksa triglicerida i glukoze sa vrednostima ukupnog, holesterola niske gustine, kao i sa vrednostima odnosa holesterola niske i visoke gustine.

**Gljučne reči:** multipla skleroza; trigliceridi; glikemija; lipidi; glikemijski indeks; insulinska rezistencija; LDL holesterol; HDL holesterol

acterized by damage to the myelin sheath of neurons. Various causes, such as infectious, toxic, metabolic and autoimmune processes may lead to the damage of the myelin sheath. The most common



### Abbreviations

CNS	– central nervous system
MS	– multiple sclerosis
HDL	– high-density cholesterol
LDL	– low-density cholesterol
TyG	– triglyceride glucose
HOMA-IR	– homeostasis model assessment of insulin resistance

demyelinating disease of the central nervous system (CNS) is multiple sclerosis (MS) [1].

Today, it is believed that MS is an autoimmune disease that occurs in genetically predisposed individuals, i.e. individuals who possess an altered major histocompatibility complex on chromosome 6 [1]. The development of the disease in genetically predisposed individuals is associated with a certain “trigger” (viral infection, psychological stress, toxins, physical trauma...). The transendothelial migration of activated lymphocytes from the blood into the brain tissue is the main cause of inflammatory lesions of CNS. As a result of the activation of the immune system in the nervous tissue there is an abundant intrathecal synthesis of class G immunoglobulins by individual clones of activated lymphocytes [1].

Generally, MS is diagnosed between the age of 20 and 40 years (~70%) twice as often in women than in men [2]. The disease has a variable course, and on the one hand the predominant clinical presentation is benign MS which implies the existence of minimal disability, while on the other hand, the rapid progression of the disease may lead to severe disability or death. Multiple sclerosis greatly impairs the quality of life, and a large number of patients are confined to a wheelchair. About 15% of patients in the final stages of the disease require full supervision and care. About 50% of MS patients die from complications that occur during the course of disease [2].

Cholesterol is an important structural component of the CNS. Approximately 25% of total cholesterol in the body is found in the CNS [3], mostly as a structural component of the myelin sheath, while smaller amounts of cholesterol originate from the plasma membranes of astrocytes and neurons. In addition to its structural role, cholesterol plays a significant role in maintaining the morphology of neurons, as well as synaptic transmission. Multiple sclerosis is characterized by the destruction of myelin, as well as changes in lipid metabolism within the CNS. Lipids, especially lipoproteins, are involved in the regulation of nerve functions in the CNS by different metabolic mechanisms. High-density lipoproteins (HDL) and low-density lipoproteins (LDL) play a key role in the transport of cholesterol and lipids in plasma, primarily HDL particles have immunomodulatory and antioxidant effects on endothelial cells [4]. The pathophysiological mechanisms of changes in plasma lipid levels in MS patients have not yet been fully clarified. Some studies point primarily to the significant role of the autonomic nervous system on lipolysis and lipoprotein metabolism [5]. It is thought that lipolysis caused by increased sympathetic activity may be one of the potential pathophysiological

mechanisms leading to dyslipidemia in patients with MS. The aim in this study is to determine the parameters of lipid status in patients with MS and to examine the association between these parameters and the triglyceride glucose (TyG) index as an indicator of insulin resistance.

### Material and Methods

This retrospective study was conducted at the Clinical Center of Vojvodina after obtaining the approval of the Ethics Committee of this institution.

The study included 28 medical history data of patients with the diagnosis of MS. Patients with acute infections, thyroid dysfunction, liver disease, and malignancy were excluded from the study.

In all the respondents, plasma glucose was determined by a standard enzyme-specific glucose oxidase and phenol aminophenazone peroxidase method using a biochemical analyzer Abbott Architect c 8000. The reference values for glucose are 3.9 - 6.1 mmol/L.

Serum concentrations of total cholesterol, HDL-cholesterol and triglycerides were determined automatically, using the biochemical analyzer Abbott Architect 4,000 and commercial sets. Recommended reference values for total cholesterol do not exceed 5.19 mmol/L, border risk values are 5.20 - 6.19 mmol/L, and high-risk values are  $\geq 6.20$  mmol/L; for triglyceride do not exceed 1.70 mmol/L, border-risk values are 1.70 - 2.29 mmol/L, and high-risk values are  $\geq 2.30$  mmol/L; desirable values for HDL-cholesterol are above 1.60 mmol/L for both sexes, the border risk values are 1.00 - 1.60 mmol/L, and high risk values are  $\leq 1.00$  mmol/L.

The LDL-cholesterol was determined indirectly by the Friedewald formula. Recommended reference values for LDL-cholesterol do not exceed 3.40 mmol/L, border risk values are 3.40 - 4.09 mmol/L, and high-risk values are  $\geq 4.10$  mmol/L [1].

In all patients the TyG index was calculated using the formula:

$$\text{TyG index} = \frac{\ln(\text{triglycerides (mg/dL)} \times \text{glucose (mg/dL)})}{2}$$

Complete statistical analysis was done using the Excel Data Analysis (Microsoft Corp, Redmond, WA) statistical software. The results are shown in tables.

### Results

This retrospective study included 28 patients with MS.

Borderline elevated values of total cholesterol and LDL-cholesterol were found in patients with MS:  $5.25 \pm 1.08$  mmol/L;  $3.90 \pm 4.54$  mmol/L, respectively, while the TyG index values were  $4.49 \pm 0.32$  mmol/L. The values of other tested parameters did not differ from the reference values (**Table 1**).

Linear correlation analysis showed a statistically significant positive correlation between the TyG index and the values of total cholesterol ( $r = 0.572$ ;  $p < 0.01$ ),

**Table 1.** Characteristics of the respondents  
**Tabela 1.** Karakteristike ispitanika

	MS/MS	
	M/M=10	F/Ž = 18
Gender/Pol		
Years/Godine	45.1 ± 9.6	
Glucose (mmol/L)/Glukoza (mmol/L)	5.02 ± 0.74	
Cholesterol (mmol/L)/Holesterol (mmol/L)	5.25 ± 1.08	
Triglycerides (mmol/L)/Trigliceridi (mmol/L)	1.22 ± 0.79	
HDL cholesterol (mmol/L)/HDL holesterol (mmol/L)	1.54 ± 0.36	
LDL cholesterol (mmol/L)/LDL holesterol (mmol/L)	3.90 ± 4.54	
LDL/HDL	2.19 ± 0.84	
TyG index/TyG indeks	4.49 ± 0.32	

Legend: HDL - high-density cholesterol; LDL - low-density cholesterol; LDL/HDL - low to high density cholesterol ratio; TyG index - triglyceride glucose index

Legenda: HDL - holesterol visoke gustine, LDL - holesterol niske gustine; LDL/HDL – odnos holesterola niske i visoke gustine; TyG indeks - indeks triglicerida i glukoze

**Table 2.** Linear correlation analysis  
**Tabela 2.** Linearna korelaciona analiza

n = 28	TyG index/TyG indeks	
	r	p
Total cholesterol/Ukupni holesterol	0.572	0.01
LDL cholesterol/LDL holesterol	0.256	0.05
LDL/HDL	0.502	0.01
HDL cholesterol/HDL holesterol	- 0.191	0.102

Legend: HDL - high-density cholesterol; LDL - low-density cholesterol; LDL/HDL - low to high density cholesterol ratio; TyG index - triglyceride glucose index; r - correlation coefficient; p - statistical significance

Legenda: HDL – holesterol visoke gustine, LDL – holesterol niske gustine; LDL/HDL – odnos holesterola niske i visoke gustine; TyG indeks – indeks triglicerida i glukoze; r – koeficijent korelacije; p – statistička značajnost

LDL-cholesterol ( $r = 0.256$ ;  $p < 0.05$ ), and the LDL/HDL ratio ( $r = 0.502$ ;  $p < 0.01$ ). There was no statistically significant correlation between the TyG index and HDL-cholesterol values.

## Discussion

Multiple sclerosis is a chronic, inflammatory disease of the CNS characterized by numerous isolated areas with inflammatory changes (plaques) associated with demyelination. Considering that MS is a disease that contributes to early disability, disclosure of the diagnosis at the right time is necessary. The diagnosis of MS is based on several factors, clinical symptoms, magnetic neuroimaging, and blood and cerebrospinal fluid laboratory testing.

Laboratory tests have a very important place in the diagnosis of MS, primarily the cerebrospinal fluid analysis. The cerebrospinal fluid analysis of the lumbar puncture includes macroscopic examination, cytological examination, biochemical tests, as well as electrophoretic techniques and examination of the degree of intrathecal synthesis of immunoglobulins. Oligoclonal bands in the cerebrospinal fluid indicate the intrathecal synthesis of immunoglobulins and it is found in approximately 90% of patients with MS [6].

The diagnosis of MS is based on a combination of clinical and paraclinical criteria. Diagnostic algorithms that are used today are recommended by the International Commission for the Diagnosis of MS (revised McDonald Criteria) [7–9].

In this study, elevated values of certain lipid parameters (total cholesterol and LDL-cholesterol) were observed in patients with MS. Similar results were reported by other studies [10, 11], clearly showing elevated levels of total cholesterol in MS patients compared to the healthy population. Also, some studies indicate a significant correlation of high plasma cholesterol levels with cognitive impairment and significant clinical disability in MS [12], which indicates the importance of determining this parameter of lipid metabolism.

In this study, mean triglyceride values were within the reference range, which is in accordance with other studies, indicating no significant deviations of the triglyceride values in the group of subjects with MS [11, 13]. However, the results of the study by Weinstock et al. showed significantly higher triglyceride values in patients with MS [14].

Changes in energy metabolism in MS patients have not been fully clarified. Certain studies point to the possibility of the sympathetic nervous system, the hypothalamus, affecting the energy metabolism

[14]. Autonomic dysfunction, primarily increased sympathetic activity, in combination with reduced physical activity, may be considered as a significant pathophysiological mechanism for early dysregulation of glucose metabolism [15]. Recent studies also indicate an important role of the hypothalamus in triglyceride metabolism primarily through the innervation of the liver, white and brown adipose tissue mainly through the sympathetic innervation of the autonomic nervous system. Some neurons, such as neuropeptide Y and neurons which express melanocortin as well as some hormones may affect the sympathetic response of the hypothalamus to target organs and thus affect the peripheral metabolism of triglycerides [16].

In this study, the TyG index was calculated in the group of subjects with MS in order to assess insulin resistance. According to the study results, the mean TyG index was  $4.49 \pm 0.32$  mmol/L, which is in agreement with other studies examining insulin resistance in patients with MS [17]. According to the literature data, the TyG index was in the range of 4 - 8. Given the relatively wide range of normal values, finer changes in energy metabolism could be monitored by this parameter as a surrogate index of insulin resistance [18].

Certain studies showed a significant correlation between the TyG index and the homeostasis model assessment of insulin resistance (HOMA-IR) index, and pointed to the fact that this index could be used in the assessment of insulin resistance in routine clinical practice, considering that it only includes data from basic laboratory analyses, i.e. basal blood glucose and triglyceride levels [19, 20].

Systemic chronic inflammation is considered to be one of the important pathophysiological factors in the pathogenesis of insulin resistance [21]. There are numerous studies that indicate the existence of insulin resistance, compensated by hyperinsulinemia in certain neurodegenerative diseases [22]. A study by Oliveira et al. [23] showed the existence of insulin resistance in approximately 40% of MS patients compared to the control group, based on the value of the HOMA index.

To quantify the insulin resistance, several indices are used today, primarily the HOMA index [24], but other indices are also used, such as TyG index, which assesses insulin resistance based on basal blood glucose and triglyceride levels. The TyG index provides assessment of insulin resistance without determination of basal insulin and it can be considered a quick and simple test for establishing the existence of insulin resistance [25].

The pathophysiological mechanisms of insulin resistance in patients with MS have not been fully explained. Some authors point to the dysregulation of the autonomic nervous system as a potential cause of metabolic disorders, i.e. the development of insulin resistance while on the other hand the resulting hyperinsulinemia additionally activates the sympathetic nervous system [26]. In addition, physical inactivity, reducing the content of mitochondria, reduces the sensitivity of cells to insulin, and according to some authors, it is an important factor of insulin resistance in these patients [27]. Also, insulin resistance with proatherogenic lipid profile is considered to be a contributing factor in the occurrence and development of atherosclerosis [28].

The results we obtained showed borderline elevated values of total cholesterol and LDL-cholesterol in patients with MS. There was a significant correlation between the TyG index and values of total cholesterol, LDL-cholesterol, and the LDL/HDL ratio. In relation to all of the above, in patients with MS, it would be useful to determine the lipid status parameters, as well as indicators of insulin resistance, as an additional diagnostic tool in monitoring the progression of the underlying disease.

## Conclusion

Borderline elevated values of total cholesterol and low-density cholesterol were found in patients with multiple sclerosis. There is a significant correlation between the triglyceride glucose index and the values of total cholesterol, low-density cholesterol, as well as the low-density cholesterol to high-density cholesterol ratio.

## References

1. Reich DS, Lucchinetti CF, Calabresi PA. Multiple sclerosis. *N Eng J Med*. 2018;378(2):169-80.
2. Ascherio A. Environmental factors in multiple sclerosis. *Expert Rev Neurother*. 2013;13(12 Suppl):3-9.
3. Dietschy JM, Turley SD. Thematic review series: brain lipids. Cholesterol metabolism in the central nervous system during early development and in the mature animals. *J Lipid Res*. 2004;45(8):1375-97.
4. Weinstock-Guttman B, Živadinov R, Mahfooz N, Carl E, Drake A, Schneider J, et al. Serum lipid profiles are associated with disability and MRI outcomes in multiple sclerosis. *J Neuroinflammation*. 2011;8:127.
5. Bartness TJ, Sherestha YB, Vaughan CH, Schwartz GJ, Song CK. Sensory and sympathetic nervous system control of white adipose tissue lipolysis. *Mol Cell Endocrinol*. 2010;318(1-2):34-43.
6. Bourahoui A, De Seze J, Gutierrez R, Onraed B, Hennache B, Ferriby D, et al. CSF isoelectrofocusing in a large cohort of MS and other neurological diseases. *Eur J Neurol*. 2004;11(8):525-9.
7. Čovićković Šternić N, editor. Nacionalni vodič dobre kliničke prakse za dijagnostikovanje i lečenje multiple skleroze. Beograd: Ministarstvo zdravlja Republike Srbije; 2013.
8. Deisenhammer F, Zetterberg H, Fitzner B, Zettl UK. The cerebrospinal fluid in multiple sclerosis. *Front Immunol*. 2019;10:726.
9. Simonsen CS, Flemmen HØ, Lauritzen T, Berg-Hansen P, Moen SM, Celius EG. The diagnostic value of IgG index versus oligoclonal bands in cerebrospinal fluid of patients with multiple sclerosis. *Mult Scler J Exp Transl Clin*. 2020;6(1): 2055217319901291.

10. Noori H, Gheini MR, Rezaeimanesh N, Saeedi R, Rezaei Aliabadi H, Sahraian MA, et al. The correlation between dyslipidemia and cognitive impairment in multiple sclerosis patients. *Mult Scler Relat Disord*. 2019;36:101415.
11. Radikova Ž, Penesova A, Vlček M, Havranova A, Sivakova M, Šiarnik P, et al. LDL and HDL lipoprotein subfractions in multiple sclerosis patients with decreased insulin sensitivity. *Endocr Regul*. 2018;52(3):139-45.
12. Zhornitsky S, McKay KA, Metz LM, Teunissen CE, Rangachari M. Cholesterol and markers of cholesterol turnover in multiple sclerosis: relationship with disease outcome. *Mult Scler Relat Disord*. 2016;5:53-65.
13. Radikova Ž, Penesova A, Vlček M, Havranova A, Sivakova M, Šiarnik P, et al. Lipoprotein profiling in early multiple sclerosis patients: effect of chronic inflammation? *Lipids Health Dis*. 2020;19(1):49.
14. Seoane-Collazo P, Fernø J, Gonzalez F, Diéguez C, Leis R, Nogueiras R, et al. Hypothalamic-autonomic control of energy homeostasis. *Endocrine*. 2015;50(2):276-91.
15. Carnethon MR, Jacobs DR Jr, Sidney S, Liu K; CARDIA study. Influence of autonomic nervous system dysfunction on the development of type 2 diabetes: the CARDIA study. *Diabetes Care*. 2003;26(11):3035-41.
16. Geerling JJ, Boon MR, Kooijman S, Parlevliet ET, Havekes LM, Romijn JA, et al. Sympathetic nervous system control of trygliceride metabolism: novel concepts derived from recent studies. *J Lipid Res*. 2014;55(2):180-9.
17. Penesova A, Vlček M, Imrich R, Vernerova L, Marko A, Meskova M, et al. Hyperinsulinemia in newly diagnosed patients with multiple sclerosis. *Metab Brain Dis*. 2015;30(4): 895-901.
18. Placzkowska S, Pawlik-Sobecka L, Kokot I, Piwowar A. Indirect insulin resistance detection: current clinical trends and laboratory limitations. *Biomed Pap Med Fac Univ Palacky Olomouc Czech Repub*. 2019;163(3):187-99.
19. Guerrero-Romero F, Simental-Mendía LE, González-Ortiz M, Martínez-Abundis E, Ramos-Zavala MG, Hernández-González SO, et al. The product of triglycerides and glucose, a simple measure of insulin sensitivity. Comparison with the euglycemic-hyperinsulinemic clamp. *J Clin Endocrinol Metab*. 2010;95(7):3347-51.
20. Lee EY, Yang HK, Lee J, Kang B, Yang Y, Lee SH, et al. Triglyceride glucose index, a marker of insulin resistance, is associated with coronary artery stenosis in asymptomatic subjects with type 2 diabetes. *Lipids Health Dis*. 2016;15(1):155.
21. Kim JH, Bachmann RA, Chen J. Interleukin-6 and insulin resistance. *Vitam Horm*. 2009;80:613-33.
22. Watson GS, Craft S. Insulin resistance, inflammation, and cognition in Alzheimer's disease: lessons for multiple sclerosis. *J Neurol Sci*. 2006;245(1-2):21-33.
23. Oliveira SR, Simao AN, Kallaur AP, de Almeida AR, Morimoto HK, Lopes J, et al. Disability in patients with multiple sclerosis: influence of insulin resistance, adiposity and oxidative stress. *Nutrition*. 2014;30(3):268-73.
24. Nikolić S, Čurić N, Mijović R, Ilinčić B, Benc D. Significance and role of homeostatic model assessment in the evaluation of glucose regulation mechanisms. *Med Pregl*. 2017;70(5-6):155-61.
25. Unger G, Benozzi SF, Perruzza F, Pennacchiotti GL. Triglycerides and glucose index: a useful indicator of insulin resistance. *Endocrinol Nutr*. 2014;61(10):533-40.
26. Adamec I, Habek M. Autonomic dysfunction in multiple sclerosis. *Clin Neurol Neurosurg*. 2013;115 Suppl 1:S73-8.
27. Bergouignan A, Rudwill F, Simon C, Blanc S. Physical inactivity as the culprit of metabolic inflexibility: evidence from bed-rest studies. *J Appl Physiol* (1985). 2011;111(4):1201-10.
28. Dichi I, Simao AN. Metabolic syndrome: new targets for an old problem. *Expert Opin Ther Targets*. 2012;16(2):147-50.

Rad je primljen 14. X 2022.

Recenziran 7. XII 2022.

Prihvaćen za štampu 12. XII 2022.

BIBLID.0025-8105:(2022):LXXV:7-8:237-241.

#### Erratum

In the double issue of the journal *Medical Review* 3-4/2022, an inadvertent error occurred when entering the DOI number for the paper entitled *Congenital Pulmonary Airway Malformation In Adults - Case Series* by Ivan Ergelašev and associates published on pages 128 - 131. The published DOI number is <https://doi.org/10.2298/MPNS2204133P>.

The correct DOI number for this paper is <https://doi.org/10.2298/MPNS2204128E>.

On this occasion, we sincerely apologize to the authors for an unintentional mistake, and a correction will be made on the websites of DOI Serbia and the Society of Physicians of Vojvodina.

Editorial Board

#### Erratum

U dvobroju časopisa „Medicinski pregled“ 3-4/2022 došlo je do nenamerne greške prilikom unošenja DOI broja za rad autora Ivana Ergelaševa i saradnika pod naslovom: *Congenital Pulmonary Airway Malformation In Adults – Case Series*, objavljenog na stranama 128-131, dodeljen je DOI broj <https://doi.org/10.2298/MPNS2204133P>.

Adekvatan DOI broj za ovaj rad je <https://doi.org/10.2298/MPNS2204128E>.

Ovom prilikom izvinjavamo se autorima na nenamerno učinjenoj grešci, a na sajtu Kobsona i Društva lekara Vojvodine biće izvršena ispravka.

Uredništvo časopisa

## CASE REPORTS

## PRIKAZI SLUČAJEVA

University of Novi Sad, Faculty of Medicine Novi Sad  
Institute of Cardiovascular Diseases of Vojvodina, Sremska Kamenica  
Cardiology Clinic

Case report  
*Prikaz slučaja*  
UDK 616.127 005.8:616.12-006]-07/-08  
<https://doi.org/10.2298/MPNS2208243I>

## A RARE CAUSE OF MYOCARDIAL INFARCTION – CORONARY ARTERY EMBOLIZATION BY MYXOMA FRAGMENTS

*REDAK UZROK INFARKTA MIOKARDA – EMBOLIZACIJA KORONARNE ARTERIJE FRAGMENTIMA MIKSOMA*

Vladimir IVANOVIĆ, Dragana DABOVIĆ, Maja STEFANOVIĆ,  
Marija BJELOBRK, Golub SAMARDŽIJA and Branislav CRNOMARKOVIĆ

### Summary

**Introduction.** Myxoma is the most common intracardiac tumor accounting for about 50% of all heart tumors. The symptoms depend on the size of the tumor, its location and mobility. Embolic manifestations of coronary arteries are extremely rare, occurring in about 0.06% of cases, and they are caused by tumor fragments.

**Case Report.** A 54-year-old female patient was admitted for an acute myocardial infarction with ST segment elevation in the inferior leads. Urgent coronary angiography was performed showing no coronary vessel stenosis. In the projection of the left atrium, a mobile mass with partial calcification was registered, which was stained to a lesser extent with a contrast agent. These were nutrient vessels with a typical “tumor blush” sign. An echocardiographic examination showed a round, inhomogeneous mass in the left atrium, which was fixed to the interatrial septum. The findings were presented to the cardiology team and urgent surgical extirpation was performed. During the follow-up period of two years, the patient was doing well and echocardiographic examination showed a normal finding, without recurrence of the tumor. **Conclusion.** Acute myocardial infarction in people without risk factors for ischemic heart disease is very rare. The most common cause of this type of acute coronary syndrome is spontaneous coronary artery dissection. Acute myocardial infarction caused by embolization of the coronary artery by myxoma fragments is a rare phenomenon. Echocardiographic examination is the method of choice in the diagnosis of myxoma. The most effective treatment for these patients is surgical resection of the tumor with low operative mortality.

**Key words:** Myocardial Infarction; Embolism; Coronary Vessels; Myxoma; MINOCA; Coronary Angiography

### Introduction

Myxoma is the most common intracardiac tumor accounting for about 50% of all heart tumors [1]. It occurs most often in women between the ages of

### Sažetak

**Uvod.** Miksom predstavlja najčešći tumor srca i čini oko 50% svih srčanih tumora. Simptomi zavise od veličine tumora, pozicije i mobilnosti. Embolijske manifestacije koronarnih arterija su izuzetno retke, javljaju se u oko 0,06% slučajeva i uzrokovane su fragmentacijom tumorske mase. **Prikaz slučaja.** Bolesnica, 54 godine, primljena je zbog akutnog infarkta miokarda sa ST elevacijom donjeg zida. Urađena je urgentna koronarografija, kojom se registruje uredan luminogram koronarnih krvnih sudova. U projekciji leve pretkomore uočava se delimično kalcifikovana pokretna formacija, koja se u manjoj meri obojava i kontrastnim sredstvom – nutritivni krvni sudovi. Ehokardiografskim pregledom se u levoj pretkomori registruje okruglasta, nehomogena, eho formacija, koja je bazom fiksirana za interatrijalni septum. Dokumentacija je prikazana kardiološko-kardiohirurškom kozilijumu, koji je mišljenja da je indikovana hitna hirurška ekstitracija tumorske mase, što je i učinjeno. U toku praćenja, u periodu od dve godine, bolesnica je subjektivno dobro i ehokardiografskim pregledom se registruje uredan nalaz, bez recidiva tumora. **Zaključak.** Akutni infarkt miokarda kod osoba bez faktora rizika za ishemijsku bolest srca je vrlo retka pojava. Najčešći uzrok takvog tipa akutnog koronarnog sindroma je spontana disekcija koronarne arterije. Još ređa pojava je akutni infarkt miokarda, kao posledica embolizacije fragmentima miksoma. Ehokardiografski pregled predstavlja metodu izbora u postavljanju dijagnoze miksoma. Najefikasniji tretman ovih pacijenata predstavlja hirurška resekcija tumora sa niskim operativnim mortalitetom.

**KLjučne reči:** infarkt miokarda; embolizacija; koronarni krvni sudovi; miksom; infarkt miokarda bez opstrukcije koronarnih arterija; koronarna angiografija

thirty and sixty [2]. In asymptomatic patients, the diagnosis is made incidentally. Symptoms depend on the size of the tumor, its position and mobility. Myxoma is characterized by three groups of symptoms: intracardiac obstruction, embolization, and

### Abbreviations

ECG – electrocardiogram

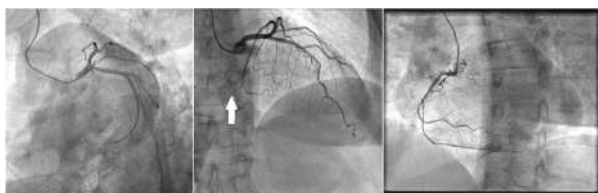
MINOCA – myocardial infarction with non-obstructive coronary arteries

systemic manifestations (fever, anemia, arthralgia, dyspnea). Systemic embolization is not rare, since it manifests in about 30 - 40% of cases. Coronary artery embolism manifestations are extremely rare, and they account for about 0.06% of cases and they are caused by tumor fragments [3]. In the literature, several cases of acute myocardial infarction caused by embolization of coronary arteries with myxoma fragments (nonatherosclerotic coronary artery disease) have been described [1].

We present the case of a 54-year-old woman, who developed acute myocardial infarction, as a consequence of the embolization of the coronary artery by fragments of a thrombotic mass from the surface of the myxoma and spontaneous recanalization of the coronary artery.

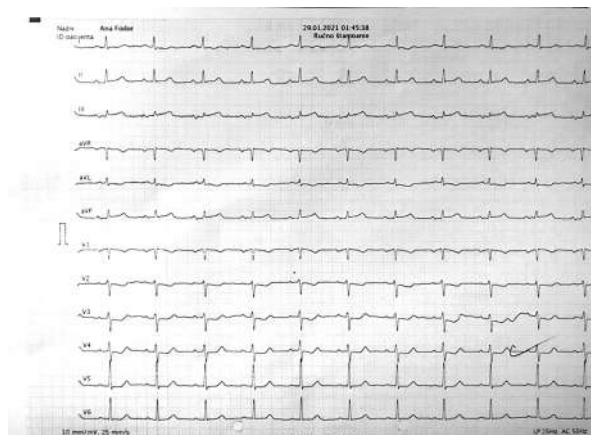
### Case Report

A 54-year-old woman was admitted to Intensive Care Unit due to an acute myocardial infarction with ST elevation in the inferior leads (**Figure 1**). Chest pain radiating to the left arm occurred about 4 hours before admission. Dual antiplatelet therapy (acetylsalicylic acid and ticagrelor) and low molecular weight heparin were initiated. She denied other diseases and risk factors since previously she had no health problems. Upon admission, she was hemodynamically and rhythmically stable, cardiac compensated (blood pressure was 110/60 mmHg and heart rate 75 beats per minute). Physical examination was unremarkable, except for a soft grade 3/6 systolic murmur at the cardiac apex. Urgent coronarography was performed showing no coronary vessel stenosis (**Figure 2**). In the projection of the left atrium, a mobile mass with partial calcification was registered, which was stained to a lesser extent with a contrast agent (**Figure 2**). These were nutrient vessels with a typical “tumor blush” sign. The laboratory findings showed multiple elevated values of cardio specific enzymes



**Figure 2.** Coronarography shows coronary artery without stenosis. In the projection of the left atrium, a mobile mass with partial calcification stained to a lesser extent with a contrast agent, was found

**Slika 2.** Na koronarografiji se ne registruju stenoze koronarnih krvnih sudova. U projekciji leve pretkomore uočava se delimično kalcifikovana pokretna formacija, koja se u manjoj meri obojava i kontrastnim sredstvom

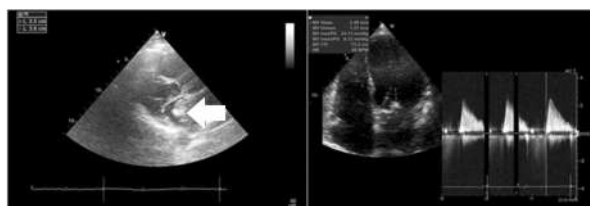

**Figure 1.** ECG shows ST segment elevation in the inferior leads

**Slika 1.** Na elektrokardiografskom zapisu se registruje elevacija ST segmenta u inferiornim odvodima

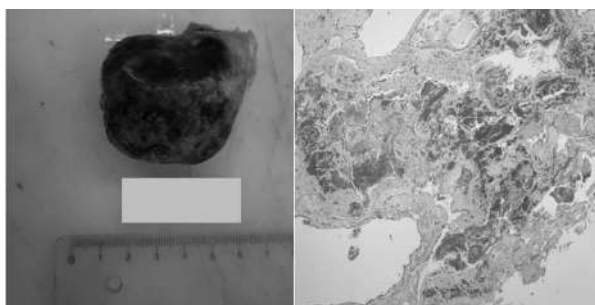
(high sensitive troponin 6,523 ng/l; reference values less than 34 ng/l). The resolution of ST elevation, identified upon admission, was registered on the electrocardiogram (ECG). According to current guidelines, this was a patient with myocardial infarction with non-obstructive coronary arteries (MINOCA). An echocardiographic examination showed a large (3.6 x 3.5 cm), round, inhomogeneous mass in the left atrium, fixed to the interatrial septum with a stalk (**Figure 3**). The described mass prolapsed into the left ventricle during diastole and caused mechanical obstruction of the mitral valve (**Figure 3**). Hypokinesis of the basal segment of the inferior wall was registered.

The findings were presented to the cardiology team and urgent surgical extirpation of the tumor mass was performed. Histopathological findings were consistent with a left atrial myxoma (**Figure 4**). A grayish nodule, gelatinous on cross-section, supplied with blood and calcified, was confirmed. It was composed of spindle and stellate-shaped cells with an oval hyperchromatic nucleus, scanty cyto-



**Figure 3.** Echocardiographic examination showed a large (3.6 x 3.5 cm) round, inhomogeneous mass in the left atrium, fixed to the interatrial septum with a stalk. The described mass prolapsed into the left ventricle during diastole and caused mechanical obstruction of the mitral valve

**Slika 3.** Ehokardiografskim pregledom se registruje velika (3,6x3,5cm), okruglasta, nehomogena, ehoformacija, koja je bazom fiksirana za interatrijalni septum. Opisana masa prolabira u levu komoru tokom dijasole i uzrokuje mehaničku opstrukciju mitralne valvule



**Figure 4.** Histopathological findings are consistent with a left atrial myxoma

*Slika 4.* Patohistološki nalaz ukazuje na miksom leve pretkomore

plasm, immersed in an abundant myxoid stroma (**Figure 4**).

The patient was without symptoms, hemodynamically and rhythmically stable, with cardiac compensation. An echocardiographic examination registered a normal finding, without segmental kinetics disorder. The patient was discharged on the seventh day of hospitalization. Since it was a myocardial infarction caused by thromboembolism from a tumor mass, with spontaneous recanalization and without angiographically registered atherosclerotic disease, the patient was discharged with one antiplatelet drug (acetylsalicylic acid).

On follow-up, two years later, the patient was doing well and the echocardiographic examination showed a normal finding, without recurrence of the tumor. A written consent to publish this report was obtained from the patient.

## Discussion

Acute myocardial infarction in people without risk factors for ischemic heart disease is very rare. The most common cause of this type of acute coronary syndrome is spontaneous coronary artery dissection. Acute myocardial infarction caused by embolization of the coronary artery by myxoma fragments is a rare phenomenon. Embolic complications of coronary arteries are extremely rare, in contrast to embolic complications of targeted vessels, such as cerebral arteries, mesenteric arteries and other peripheral arteries. According to current guidelines, our patient presented with MINOCA. Coronary embolism is included in microvascular causes of MINOCA, as it usually involves microcirculation, although angiographically visible embolization of the epicardial coronary artery branches may occur [4]. In our patient, coronarography showed no visible embolization. The cause of very rare embolization of the coronary arteries can be explained by the perpendicular position of the ostia of the coronary arteries, protection of the ostia by aortic valve cusps in systole, and the small diameter of the coronary arteries [5]. Embolization of the right coronary artery is more common than of the left coronary artery. This can be understood as a consequence of the smaller

angle at which the right coronary artery is placed. Panos et al. reported that the right coronary artery is most often affected (in 50% of cases), the left coronary artery is affected in 20% of cases, and the circumflex artery in about 10% of cases [6].

In our case, chest pain and electrocardiographic ST segment elevation in the inferior leads are most likely the result of embolization of the coronary artery by small thrombotic fragments from the surface of the tumor mass.

The patient received dual antiplatelet therapy and low molecular weight heparin. This therapy contributed to a recanalization of the coronary artery. Coronarography did not show a thrombus or a narrowing of the blood vessel. The patient was without any symptoms and the ECG registered resolution of ST segment elevation. El Zaharani et al. reported that coronary blood vessel without stenosis occurs in 55% of patients with myocardial infarction and myxoma, found in 17 cases between 2003 and 2014. They showed that the coronary blood vessel without stenosis was the result of spontaneous recanalization of the coronary artery [7].

A common finding on angiography in these patients is late or delayed contrast opacification of the tumor mass in vascularized tumors. This is described in the literature as “tumor blush” which represents the neovascularization of the tumor mass [8]. This feature helps to differentiate myxoma from atrial thrombus [9]. In our patient, the “tumor blush” was registered on coronarography.

Echocardiographic examination is the most frequently used method in establishing the diagnosis. This is a non-invasive method that provides sensitivity between 95 and 100%. A “tumor plop” sound can be heard during auscultation of these patients. A case study including 112 patients with myxoma shows that 65% of patients had auscultatory abnormalities, but only 15% of patients had a tumor plop [10]. Our patient had a systolic murmur, but not a “tumor plop”.

In the current recommendations, there are no clear guidelines for dual antiplatelet therapy in such patients. According to the literature, administration of dual antiplatelet therapy is associated with a significant intraoperative bleeding in patients who undergo surgical tumor extirpation. Since myocardial infarction was caused by thromboembolism from a tumor mass, with spontaneous recanalization and without angiographically registered atherosclerotic disease, the patient was discharged with one antiplatelet drug (acetylsalicylic acid). The most effective treatment for these patients is surgical resection of the tumor with low operative mortality.

The recurrence rate after surgical excision is relatively low (5%), but long-term follow-up with echocardiographic imaging is recommended [11].

## Conclusion

Acute myocardial infarction in people without risk factors for ischemic heart disease is a very rare. The



most common cause of this type of acute coronary syndrome is spontaneous coronary artery dissection. Acute myocardial infarction caused by embolization of the coronary artery by myxoma fragments is a rare

phenomenon. Echocardiographic examination is a method of choice in the diagnosis of myxoma. The most effective treatment for these patients is surgical resection of the tumor with low operative mortality.

### References

1. Lalla S, Kawall J, Seecheran R, Ramadhin D, Seecheran V, Persad S, et al. Atrial myxoma presenting as a non-ST-segment elevation myocardial infarction. *Int Med Case Rep J.* 2019;12:179-83.
  2. Reynen K. Frequency of primary tumors of the heart. *Am J Cardiol.* 1996;77(1):107.
  3. Lehrman KL, Prozan GB, Ullyot D. Atrial myxoma presenting as acute myocardial infarction. *Am Heart J.* 1985;110(6):1293-5.
  4. Scalone G, Niccoli G, Crea F. Editor's choice - pathophysiology, diagnosis and management of MINOCA: an update. *Eur Heart J Acute Cardiovasc Care.* 2019;8(1):54-62.
  5. Attar MN, Moore RK, Khan S. Left atrial myxoma presenting with ventricular fibrillation. *J Cardiovasc Med (Hagerstown).* 2008;9(3):282-4.
  6. Panos A, Kalangos A, Sztajzel J. Left atrial myxoma presenting with myocardial infarction. Case report and review of the literature. *Int J Cardiol.* 1997;62(1):73-5.
  7. Al Zahrani IM, Alraqtan A, Rezk A, Almasswary A, Bella A. Atrial myxoma related myocardial infarction: case report and review of the literature. *J Saudi Heart Assoc.* 2014;26(3):166-9.
  8. Kim YK, Yong HS, Kang EY, Woo OH. Left atrial myxoma with neovascularization: detected on cardiac computed tomography angiography. *Int J Cardiovasc Imaging.* 2009;25 Suppl 1:95-8.
  9. Tang W, Chen J. Myocardial infarction and "dye brushes" sign from an atrial myxoma. *Int J Cardiovasc Imaging.* 2020;36(1):1-2.
  10. Reynen K. Cardiac myxomas. *N Engl J Med.* 1995;333(24):1610-7.
- Rad je primljen 29. XII 2022.  
 Recenziran 24. I 2023.  
 Prihvaćen za štampu 24. I 2023.  
 BIBLID.0025-8105:(2022):LXXV:7-8:243-246.

Clinical Center of Vojvodina, Radiology Center, Novi Sad<sup>1</sup>  
University of Novi Sad, Faculty of Medicine Novi Sad<sup>2</sup>  
Clinical Center of Vojvodina, Clinic of Endocrinology,  
Diabetes and Metabolic Diseases, Novi Sad<sup>3</sup>  
Institute for Child and Youth Health Care of Vojvodina, Novi Sad<sup>4</sup>  
Health Center "Novi Sad", Novi Sad<sup>5</sup>

Case report  
*Prikaz slučaja*  
UDK 616.64-007.1:612.6.058]-07/-08  
<https://doi.org/10.2298/MPNS2208247D>

## TESTICULAR ULTRASOUND IN A PATIENT WITH KALLMANN SYNDROME – A CASE REPORT

### ULTRAZVUK TESTISA KOD KALMANOVOG SINDROMA – PRIKAZ SLUČAJA

Daniela DONAT<sup>1</sup>, Sonja LUKAČ<sup>1,2</sup>, Ivana BAJKIN<sup>2,3</sup>, Ivana VORGUČIN<sup>2,4</sup>,  
Viktor TILL<sup>1,2</sup> and Slađana ZAGORAC<sup>5</sup>

#### Summary

**Introduction.** Kallmann syndrome is a genetic disorder marked by hypogonadotropic hypogonadism and anosmia. Patients with Kallmann syndrome have low circulating testosterone levels and low gonadotropin levels, whereas other pituitary hormones are normal. The treatment is based on sex steroid replacement with the aim to restore normal pubertal development and includes attempts to restore fertility by using gonadotropin-releasing hormones. Ultrasound examination of the testicles is a very useful complement to determine and monitor the precise testicular volume, which is an important prognostic factor for future fertility. **Case Report.** At the age of 18, the patient was suspected of having Kallmann syndrome and was referred to an endocrinologist. After three months of testosterone therapy, the patient was sent for an ultrasound of the testicles. The right testicle measured 16 x 6 mm, the left testicle 10 x 5 mm, both with a discrete marginal circular dichroism signal. One year after the first testicular ultrasound, the patient came for a check-up. The right testicle measured 14 x 5 mm, the left testicle 11 x 5 mm, stationary structure. **Conclusion.** The diagnosis of Kallmann syndrome is often delayed, because hypogonadotropic hypogonadism is usually not apparent until puberty, and individuals with anosmia are often unaware of this sensory deficit. In this case, late recognition of the syndrome, as well as late initiation of therapy, did not give satisfactory results.

**Key words:** Kallmann Syndrome; Ultrasonography; Testis; Hypogonadism; Congenital Abnormalities; Anosmia

#### Introduction

Kallmann syndrome (KS) has several synonyms: de Morsier-Gauthier syndrome, olfacto-genital dysplasia, and congenital hypogonadism with anosmia. It is a genetic disorder marked by hypogonadotropic hypogonadism and anosmia [1].

Dr. Aureliano Maestre de San Juan was the first who recognized the association between anosmia and small testicles, whereas Franz Josef Kallmann

#### Sažetak

**Uvod.** Kalmanov sindrom se može okarakterisati kao genetski poremećaj obeležen hipogonadotropnim hipogonadizmom i anosmijom. Pacijenti sa Kalmanovim sindromom imaju nizak nivo testosterona sa niskim nivoom gonadotropina, dok su drugi hormoni hipofize normalni. Lečenje se zasniva na zameni seksualnih steroida sa ciljem obnavljanja normalnog pubertetskog razvoja i uključuje pokušaje vraćanja plodnosti primenom hormona koji oslobađaju gonadotropin. Ultrazvučni pregled testisa je veoma korisna dopuna određivanju i praćenju preciznog volumena testisa, što je važan prognostički faktor za buduću plodnost. **Prikaz slučaja.** Posumnano je da pacijent ima Kalmanov sindrom i sa 18 godina je upućen endokrinologu. Nakon tromesečne terapije testosteronom, pacijent je poslat na ultrazvučni pregled testisa. Desni testis je dimenzija 16 x 6 mm, levi testis 10 x 5 mm, oba sa prisutnim diskretnim marginalnim CD signalom. Godinu dana nakon prvog ultrazvučnog pregleda testisa, pacijent dolazi na pregled. Desni testis je dimenzija 14 x 5 mm, levi testis je 11 x 5 mm, stacionarne strukture. **Zaključak.** Dijagnoza Kalmanovog sindroma se često odlaže jer hipogonadotropni hipogonadizam obično nije očigledan do puberteta, a osobe sa anosmijom često nisu svesne ovog senzornog deficita. U ovom slučaju se pokazalo da kasno prepoznavanje sindroma, kao i kasna primena terapije, nisu dali zadovoljavajuće rezultate.

**Ključne reči:** Kalmanov sindrom; ultrasonografija; testis; hipogonadizam; kongenitalne anomalije; anosmija

was the first who described this condition in 1944, suggesting it had a hereditary origin [2].

In the last decade, findings from research on the embryogenesis of olfactory sensory neurons and genetic mutations were incorporated to the description and diagnostic criteria assigned to KS, while X-linked, autosomal dominant, and autosomal recessive inheritance patterns were recognized [3].

Congenital hypogonadotropic hypogonadism (CHH) is defined by isolated deficiency or dysfunction of gonadotropin-releasing hormone (GnRH). It

### Abbreviations

KS	– Kallmann syndrome
GnRH	– gonadotropin-releasing hormone
MRI	– magnetic resonance imaging

is clinically characterized by absent or incomplete development during puberty, resulting in small testicles by the age of 18 years, and infertility in adults. These patients have low circulating testosterone levels with low gonadotropin levels, whereas other pituitary hormones are normal [4].

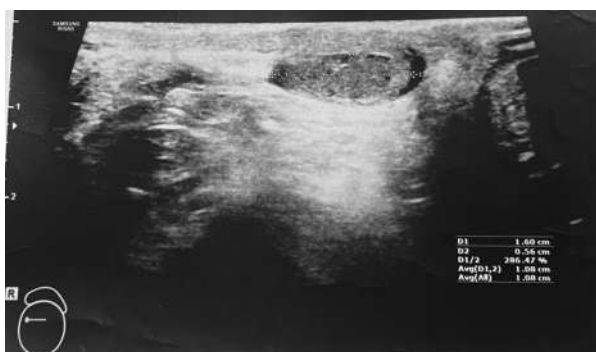
Also, anosmia has been correlated with GnRH deficiency, since the migration and differentiation of GnRH neurons rely on the formation of the olfactory bulb. Olfactory bulb neurons and GnRH neurons stem from the embryonic nasal epithelium, migrate toward the meninges, and cross the cribriform plate. The GnRH neurons subsequently move to the preoptic area of the hypothalamus guided by olfactory bulb neuron projections. Therefore, defects in the formation of the olfactory bulb and tract may disturb the migration and differentiation of GnRH neurons [3].

Morphological abnormalities of olfactory apparatus in KS are best evaluated by magnetic resonance imaging (MRI). Individuals with KS may present with other malformations including cleft palate, high-arched palate, renal agenesis, sensorineural hearing loss, color blindness, learning disability, and impaired spermatogenesis and fertility [5].

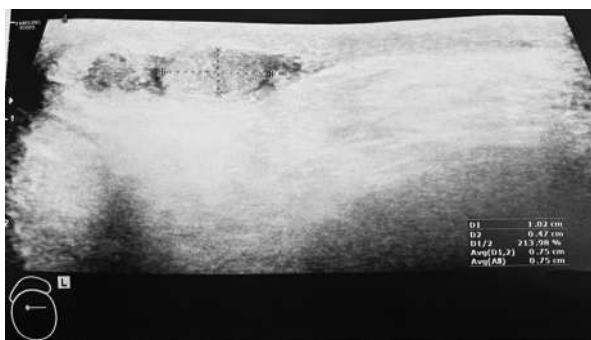The prevalence of KS varies between 1:10,000 and 1: 80,000 in males, and 1: 50,000 in females, with males being more affected than females (female to male ratio 5:11.5) [6].

The treatment is based on sex steroid replacement with the aim to restore normal pubertal development and includes attempts to restore fertility by administration of GnRH. Timely treatment is important not only to restore metabolic, bone, and sexual balance, but also to mitigate the psychosocial effects associated with KS [7].

Ultrasound examination of the testicles and internal genital organs by an experienced radiologist is a very useful complement to physical examination for precise testicular volume determination and monitoring (during hormone therapy), which is an important prognostic factor for future fertility and



**Figure 1.** First ultrasound examination - right testicle  
*Slika 1. Prvi ultrazvučni pregled – desni testis*



**Figure 2.** First ultrasound examination - left testicle  
*Slika 2. Prvi ultrazvučni pregled – levi testis*

detection of associated abnormalities of the genital tract that may worsen the reproductive function. It also shows the inguinal or intra-abdominal position of one or both testicles in case of ectopy, and this may help guide the therapeutic approach (medical or surgical) in case of cryptorchidism [8, 9].

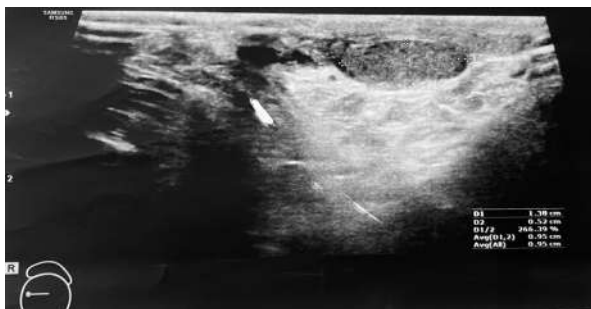
### Case Report

A full-term male patient weighing 4,050 g and measuring 56 cm at birth through a vaginal delivery was diagnosed with bilateral retractile testicles by a pediatric surgeon and was followed until bilateral orchidopexy at the age of five.

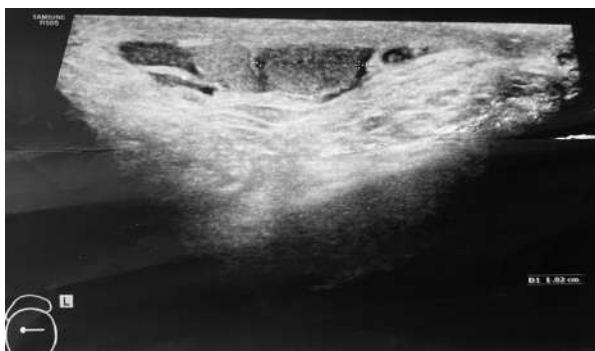After orchidopexy, he visited a pediatrician at the age of seventeen, when he complained of diminished sense of smell. His height and weight were 180.8 cm and 80.5 kg, with left and right testicular volumes of 2 ml, and a penis length -2 SD.

His workup did not show alterations in gonadotropin, testosterone, or estradiol levels: luteinizing hormone < 0.2 mIU/ml (1.7 - 8.6 mIU/ml); follicle stimulating hormone = 0.7 mIU (1.5 - 12.4 mIU/ml); estradiol < 20 pg/ml (7.63 - 42.6 pg/ml); testosterone 0,13 ng/ml. Bone age assessment by X-ray showed a chronological age of 15 years and 6 months.

Skull MRI showed that the patient had hypoplastic olfactory bulbs and shallow olfactory grooves, along with a normal pituitary gland and a normal pituitary stalk. Kallmann syndrome was suspected and the patient was referred to an endocrinologist. He was treated with gonadotropins for a year; after



**Figure 3.** Control ultrasound examination - right testicle  
*Slika 3. Kontrolni ultrazvučni pregled – desni testis*



**Figure 4.** Control ultrasound examination - left testicle  
*Slika 4.* Kontrolni ultrazvučni pregled – levi testis

that he started treatment with testosterone cypionate 150 mg/month and the dose was then increased to 250 mg/month.

After three months of testosterone therapy, the patient was sent for an ultrasound of the testicles. The right testicle measured 16 x 6 mm, slight heterogeneous structure, with a discrete marginal circular dichroism signal (**Figure 1**).

The left testis measured 10 x 5 mm, with discrete heterogeneous structure, also with circular dichroism signal (**Figure 2**).

One year after the first ultrasound examination of the testicles, the patient came for a check-up. At the time of examination, the patient was on testosterone therapy 250 mg/month. The right testicle measured 14 x 5 mm (**Figure 3**), the left testicle measured 11 x 5 mm, stationary structure (**Figure 4**).

### Conclusion

Although rare, Kallmann syndrome has a great impact on child and adolescent health, since early diagnosis may trigger multidisciplinary treatment and hormone replacement therapy for hypogonadism and/or help the patient cope with persisting alterations such as anosmia and the risk of infertility. The diagnosis of Kallmann syndrome is often delayed, because hypogonadotropic hypogonadism is usually not apparent until puberty, and individuals with anosmia are often unaware of this sensory deficit. In this case, late recognition of the syndrome, as well as late initiation of therapy, did not give satisfactory results.

### References

1. Meczekalski B, Podfigurna-Stopa A, Smolarczyk R, Katulski K, Genazzani AR. Kallmann syndrome in women: from genes to diagnosis and treatment. *Gynecol Endocrinol.* 2013;29(4):296-300.
2. Kallmann FJ, Schoenfeld WA, Barrera SE. The genetic aspects of primary eunuchoidism. *Am J Ment Defic.* 1944;48:203-36.
3. Navarro NF, Sukster E, Feijó RB. An adolescent with Kallmann syndrome: a case report. *Residência Pediátrica.* 2019;9(2):173-5.
4. Hao M, Nie M, Yu BQ, Gao YJ, Wang X, Ma WL, et al. Gonadotropin treatment for male partial congenital hypogonadotropic hypogonadism in Chinese patients. *Asian J Androl.* 2020;22(4):390-5.
5. Salama N. Kallmann syndrome and deafness: an uncommon combination: a case report and a literature review. *Int J Reprod Biomed.* 2016;14(8):541-4.
6. Forni PE, Wray S. GnRH, anosmia and hypogonadotropic hypogonadism-where are we? *Front Neuroendocrinol.* 2015;36:165-77.
7. Kim SH. Congenital hypogonadotropic hypogonadism and Kallmann syndrome: past, present, and future. *Endocrinol Metab (Seoul).* 2015;30(4):456-66.
8. Young J. Approach to the male patient with congenital hypogonadotropic hypogonadism. *J Clin Endocrinol Metab.* 2012;97(3):707-18.
9. Nikolić O, Lukač I. Doppler sonography in diagnosis of the acute scrotum. *Med Pregl.* 2006;59(3-4):111-7.

Rad je primljen 24. XI 2022.

Recenziran 4. I 2023.

Prihvaćen za štampu 15. I 2023.

BIBLID.0025-8105:(2022):LXXV:7-8:247-249.

Institute for Pulmonary Diseases of Vojvodina, Sremska Kamenica<sup>1</sup>  
 College of Vocational Studies for the Education of Preschool Teachers  
 and Sports Trainers, Department of Biomedical Sciences, Subotica<sup>2</sup>  
 University of Novi Sad, Faculty of Medicine Novi Sad,  
 Department of Internal Medicine<sup>3</sup>

College of Social Work, Department of Psychology, Belgrade<sup>4</sup>

College of Applied Studies "Sirmium", Department of Medical Sciences, Sremska Mitrovica<sup>5</sup>

Clinical Center of Vojvodina, Clinic of Otorhinolaryngology and Head and Neck Surgery, Novi Sad<sup>6</sup>

Case report

*Prikaz slučaja*

UDK 616.711-002.5-07/-08

<https://doi.org/10.2298/MPNS2208250M>

## A SPINAL TUMOR OR TUBERCULOSIS – A CASE REPORT AND SHORT LITERATURE REVIEW

### TUMOR ILI TUBERKULOZA KIČME – PRIKAZ SLUČAJA I KRATAK PREGLED LITERATURE

Ana MILENKOVIĆ<sup>1</sup>, Jovan JAVORAC<sup>1-3</sup>, Dejan ŽIVANOVIĆ<sup>4,5</sup>, Svetlana KAŠIKOVIĆ LEČIĆ<sup>1,3</sup>,  
 Vanja TOVILOVIĆ<sup>6</sup> and Miroslav ILIĆ<sup>1,3</sup>

#### Summary

**Introduction.** Among infectious diseases, tuberculosis ranks first in terms of morbidity and mortality. It mainly affects the lungs, but it can affect any organ in the body. **Case Report.** A 29-year old female patient, bacillus Calmette-Guerin vaccinated, human immunodeficiency virus-negative, non-smoker, active athlete, presented with magnetic resonance imaging of the spine indicating vertebral body collapse of Th10 with signs of intraosseous infiltration, extraosseous prevertebral, and extracorporeal spread into the spinal canal. Corpectomy of Th10 and Th11 with an anterior fusion of Th9-12 was performed by neurosurgical intervention. Histopathological examination of the vertebral body confirmed a necrotic granulomatous inflammation. No acid-fast bacilli were seen by Ziehl-Neelsen staining, while *Mycobacterium tuberculosis* culture was positive. Chest X-ray and computed tomography were normal, induced sputum smear microscopy was negative for *Mycobacterium tuberculosis*. The antituberculosis therapy lasted for 12 months. **Conclusion.** Spinal tuberculosis is a differential diagnostic problem in relation to pyogenic infections and metastatic bone tumors.

**Key words:** Spine; Neoplasms; Tuberculosis; Tuberculosis, Spinal; Diagnosis, Differential; Tuberculosis, Extrapulmonary

#### Introduction

In terms of mortality, tuberculosis (TB) ranks first among infectious diseases, despite the fact that it has been around for over 4,000 years. Every year, about 10 million patients in the world are affected by TB, 1.2 million die, and 16% of patients have an extrapulmonary form of TB [1]. In 2019 in Serbia, the incidence of TB was 9.02 per 100,000 people with 14 fatalities (0.13 per 100,000) [2].

Extrapulmonary TB has a non-specific clinical picture, which makes the diagnosis and treatment

#### Sažetak

**Uvod.** Među infektivnim bolestima, tuberkuloza je na prvom mestu po broju obolelih i umrlih. Najčešće su zahvaćena pluća, ali svaki organ može oboleti. **Prikaz slučaja.** Pacijentkinja starosti 29 godina, vakcinisana be-se-že vakcinom, negativna na HIV, nepušač, aktivni sportista. Magnetna rezonancija kičme ukazuje na kolaps Th10 pršljenkog tela sa znacima intraosealnog infiltrata, ekstraosealnog prevertebralnog i retrokorporalnog širenja u kičmeni kanal. Neurohirurškom intervencijom urađena je korpo- rektomija Th10 i Th11 sa prednjom fuzijom Th9-12. Patohistološkim pregledom pršljenkog tela verifikovana je nekrotična granulomatozna upala. Bojenjem po Cil-Nilsenu (*Ziehl-Neelsen*) nisu viđeni acidorezistentni bacili, dok su kulture na *Mycobacterium tuberculosis* bile pozitivne. Radiogram i pregled kompjuterizovanim tomografijom grudnog koša bili su urednog nalaza, indukovani sputumi direktnom mikroskopijom i kulturama negativni na *Mycobacterium tuberculosis*. Lečenje antituberkuloticima je sprovedeno u ukupnom trajanju od 12 meseci. **Zaključak.** Tuberkuloza kičme je diferencijalno-dijagnostički problem u odnosu na piogene infekcije i metastatske tumore kostiju.

**KLjučne reči:** kičma; neoplazme; tuberkuloza; tuberkuloza kičme; diferencijalna dijagnoza; ekstrapulmonalna tuberkuloza

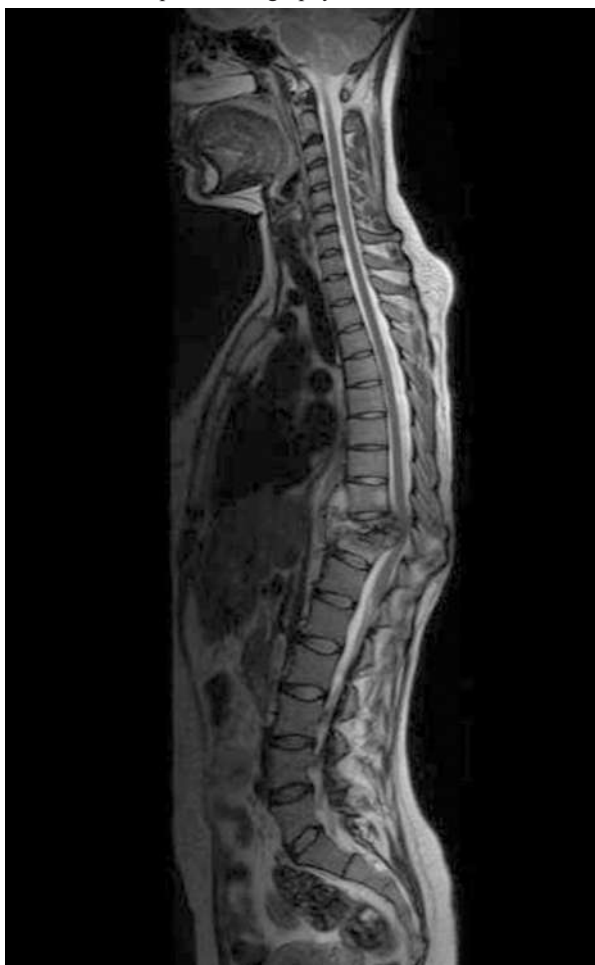more difficult. The aim of this study was to present such a case.

#### Case Report

A 29-year-old woman suffered a thoracic spine injury (Th10) in a traffic accident due to a sudden jerk during the impact. In the next three years, she felt occasional pain at the point of injury, without neurological or general problems. She was bacillus Calmette-Guerin vaccinated, human immunodeficiency virus (HIV)-negative, non-smoker, active bowler, living in good social conditions, and denied-

**Abbreviations**

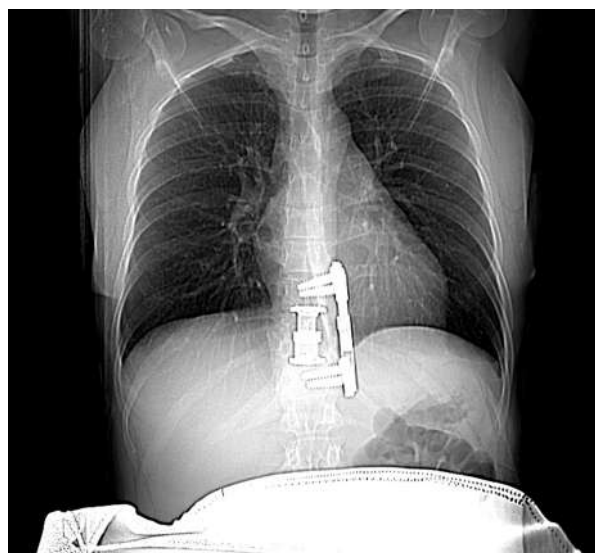
TB	– tuberculosis
MRI	– magnetic resonance imaging
HIV	– human immunodeficiency virus
MT	– Mycobacterium tuberculosis
CT	– computed tomography



**Figure 1.** Sagittal section of T2 MRI showing expansive mass between Th10 and Th11 vertebral bodies

**Slika 1.** Sagitalni presek T2 magnetne rezonancije koji prikazuje ekspanzivnu masu između Th10-11 kičmenog pršljena

previous contact with a TB patient. During this period, she was examined several times by a specialist in general medicine, neurologists, and orthopedists and was treated with nonsteroidal anti-inflammatory drugs. The neurological status was normal. Magnetic resonance imaging (MRI) of the thoracolumbar segment showed an inhomogeneous lesion in the body of the Th10 vertebra, which was radiologically characterized as post-traumatic. In the meantime, she got pregnant and gave birth to a healthy child by natural birth. After childbirth, the symptoms got worse, including increased pain intensity and development of deformities in the form of swelling at the level of the previous injury, which was clinically painful to palpation, without signs of skin inflammation or suppuration.



**Figure 2.** Chest X-ray before therapy without signs of active pulmonary tuberculosis

**Slika 2.** Radiogram grudnog koša pre započinjanja terapije bez aktivnih plućnih promena

The repeated MRI showed a complete collapse of the Th10 vertebral body with signs of intraosseous infiltration and extraosseous prevertebral and extracorporeal expansion into the spinal canal, with a significant compressive effect on the spinal cord with absolute narrowing of the spinal canal (**Figure 1**). Partial collapse of the Th11 vertebral body was also confirmed. The neurological status was still normal. Considering the clinical and radiological progression, a corpectomy of Th10 and Th11 with an anterior fusion of Th9-12 was performed. No acid-resistant bacilli were seen by direct microscopy of the vertebral bodies. Bacteriological cultures remained sterile, while cultures for Mycobacterium tuberculosis (MT) were positive. Histopathological examination of the material verified necrotic granulomatous inflammation, while Ziehl-Neelsen staining did not show acid-resistant bacilli or Periodic acid-Schiff + microorganisms. A susceptibility test was performed to determine susceptibility to all antitubercular agents and treatment was started according to the scheme for category I patients. Chest X-ray computed tomography (CT) findings were normal (**Figure 2**). No acid-resistant bacilli were seen by direct microscopy of induced sputum, and MT cultures were negative. However, the QuantiFERON test was positive. No postoperative complications were observed and further treatment was uneventful. After the surgery, the patient denied the previously mentioned problem (pain in the affected part of the spine). The antituberculosis treatment lasted for 12 months.

**Discussion**

Considering that this is a young person without risk factors for TB, we initially checked the HIV status (negative) since the increase in the number of

**Table 1.** Data from several studies investigating spinal TB  
**Tabela 1.** Rezultati nekoliko studija koje su istraživale spinalnu tuberkulozu

Authors <i>Autori</i>	Country <i>Zemlja</i>	Study design <i>Vrsta studije</i>	No. of patients/ <i>Broj</i> <i>pacijenata</i>	Symptoms <i>Simptomi</i>	Localization <i>Lokalizacija</i>	Surgery <i>Hirurgija</i>	Antitubercular agents <i>Antituberkulotici</i>
Lin L, et al.	China <i>Kina</i>	Meta-analysis <i>Meta-analiza</i>	851	ND <i>NP</i>	ND <i>NP</i>	All <i>Svi</i>	Short/ <i>Kratki</i> režim: 397 Standard/ <i>Standardni</i> : 454
Narayan V, et al.	USA <i>SAD</i>	Systematic review/ <i>Pregledna</i> studija	ND <i>NP</i>	Focal back pain, motor deficit/ <i>Lokalizovan bol u leđima, motorni deficit</i>	ND <i>NP</i>	All <i>Svi</i>	All <i>Svi</i>
Yuan B, et al.	China <i>Kina</i>	Systematic review/ <i>Pregledna</i> studija	456	Back pain <i>Bol u leđima</i>	Cervical spine <i>Vratna kičma</i>	329	All <i>Svi</i>
Bao D, et al.	China <i>Kina</i>	Meta-analysis <i>Meta-analiza</i>	247	ND <i>NP</i>	Cervical spine <i>Vratna kičma</i>	153	94
Li M, et al.	China <i>Kina</i>	Case series <i>Serijski slučajevi</i>	26	Back pain, general symptoms/ <i>Bol u leđima, opšti simptomi</i>	Lumbosacral spine <i>Lumbosakralna kičma</i>	26	26 (Standard <i>Standardni</i> )
Pu F, et al.	China <i>Kina</i>	Case series <i>Serijski slučajevi</i>	10	Back pain, spinal activity limitation <i>Bol u leđima, ograničeni pokreti kičme</i>	Thoracic 3, thoracolumbar 1, lumbar 5, sacral 1/ <i>Torakalna 3, torakolumbalna 1, lumbalna 5, sakralna 1</i>		
Wang P, et al.	China <i>Kina</i>	Retrospective study <i>Retrospektivna studija</i>	597	Back pain, sweating <i>Bol u leđima, prenojanje</i>	Thoracic 50.19%, lumbar 40.09%, sacral 4.14%, cervical 2.59%/ <i>Torakalna 50.19%, lumbalna 40.09%, sakralna 4.14%, vratna 2.59%</i>	483	136

Legend: ND – No data

Legenda NP – nema podataka

patients with HIV correlates with the increase in the number of TB patients [1].

Spinal TB is the most common extrapulmonary TB, accounting for about 50% of musculoskeletal TB and 1% of all forms of TB [3]. It is caused by lymphohematogenous spread from the primary focus [4]. **Table 1** summarizes the most important data from several studies that investigated spinal TB [3, 5–10].

The main risk factors for the development of TB are HIV infection, low social status, alcoholism, and old age. However, our patient did not have any of these risk factors. In our case, the risk factors included the traffic accident (post-traumatic lesion), as well as active bowling (sports injury). Numerous studies have shown that there is a genetic predisposition due to which some people develop an active form of the disease and some do not [11].

As far as the clinical features are concerned, spinal TB compresses the spinal cord and leads to pain, limited mobility, kyphosis, paralysis, and even death [3]. When evaluating back pain, general symptoms should raise suspicion of a specific proc-

ess such as weight loss, night sweats, and persistence of pain after 6 weeks of treatment with nonsteroidal anti-inflammatory drugs [12].

The use of the QuantiFERON test in case of suspected active TB is justified if the lesion is not available for biopsy, or as an additional test to confirm or exclude the diagnosis [13–15]. In our case, the QuantiFERON test served for confirmation of spinal TB.

In addition to medical treatment as the basic type of treatment, in certain cases, surgery plays an auxiliary role, and in our patient, the surgical approach was both diagnostic and therapeutic.

## Conclusion

Spinal tuberculosis is a differential diagnostic problem in relation to pyogenic infections and metastatic bone tumors. Histopathological and bacteriological examinations are a great challenge due to the localization of the disease and potential complications during invasive procedures.

### References

1. World Health Organization (WHO). Global tuberculosis report 2020. Geneva: WHO; 2020.
  2. Institut za javno zdravlje Srbije „Dr Milan Jovanović Batut“ (IZJZS). Godišnji izveštaj o zaraznim bolestima u Republici Srbiji za 2019. godinu. Beograd: IZJZS; 2020.
  3. Wang P, Liao W, Cao G, Jiang Y, Rao J, Yang Y. Characteristics and management of spinal tuberculosis in tuberculosis endemic area of Guizhou province: a retrospective study of 597 patient in a teaching hospital. *Biomed Res Int.* 2020;2020:1468457.
  4. Rajasekaran S, Kanna RM, Shetty AP. Pathophysiology and treatment of spinal tuberculosis. *JBJS Rev.* 2014;2(9):e4.
  5. Lin L, Ke Z, Cheng S. Efficacy and safety of short-term chemotherapy for patients with spinal tuberculosis undergoing surgery in Chinese population: a meta-analysis. *J Orthop Surg Res.* 2021;16(1):229.
  6. Narayan V, Mohammed N, Savardekar AR, Patra DP, Nanda A. Tuberculous spondylolisthesis: a reappraisal of the clinicoradiologic spectrum and surgical treatment paradigm. *World Neurosurg.* 2018;114:361-7.
  7. Yuan B, Zhao Y, Zhou S, Wang Z, Chen X, Jia L. Treatment for tuberculosis of the subaxial cervical spine: a systematic review. *Arch Orthop Trauma Surg.* 2021;141(11):1863-76.
  8. Bao D, Li L, Gong M, Xiang Z. Treatment of atlanto-axial tuberculosis with neurological impairment: a systematic review. *World Neurosurg.* 2020;135:7-13.
  9. Li M, Huang J, Chen J, Liu Sh, Deng Z, Hu J, et al. Unilateral limited laminectomy for debridement to treat localized short-segment lumbosacral spinal tuberculosis: a retrospective case series. *Orthop Surg.* 2021;13(4):1170-80.
  10. Pu F, Feng J, Yang L, Zhang L, Xia P. Misdiagnosed and mismanaged atypical spinal tuberculosis: a case series report. *Exp Ther Med.* 2019;18(5):3723-8.
  11. Quafli M, Najimi M, Elaouad R, Sadki K. Current immunogenetic predisposition to tuberculosis in the Moroccan population. *Int J Immunogenet.* 2017;44(6):286-304.
  12. Banerji JS. Persistent back pain in a young woman. *Cleve Clin J Med.* 2015;82(6):337-8.
  13. Phetsuksiri B, Srisungngam S, Rudeeaneksin J, Boonchu S, Klayut W, Norrrarat R, et al. QuantiFERON-TB Gold In-Tube test in active tuberculosis patients and healthy adults. *Rev Inst Med Trop Sao Paulo.* 2018;60:e56.
  14. Choi S, Jung KH, Son HJ, Lee SH, Hong JM, Kim MC, et al. Diagnostic usefulness of the QuantiFERON-TB gold in-tube test (QFT-GIT) for tuberculous vertebral osteomyelitis. *Infect Dis (Lond).* 2018;50(5):346-51.
  15. Masood K, Jamil B, Akber A, Hassan M, Islam M, Hasan Z. Testing for Mycobacterium tuberculosis infection using the QuantiFERON-TB GOLD assay in patients with comorbid conditions in a tertiary care endemic setting. *Trop Dis Travel Med Vaccines.* 2020;6(1):3.
- Rad je primljen 9. VII 2022.  
 Recenziran 2. XII 2022.  
 Prihvaćen za štampu 2. XII 2022.  
 BIBLID.0025-8105:(2022):LXXV:7-8:250-253.



Clinical Center of Vojvodina Novi Sad, Radiology Center<sup>1</sup>  
 University of Novi Sad, Faculty of Medicine Novi Sad<sup>2</sup>  
 Clinical Center of Vojvodina Novi Sad  
 Vascular and Endovascular Surgery Clinic<sup>3</sup>  
 Neurology Clinic<sup>4</sup>

Case report  
*Prikaz slučaja*  
 UDK 616-005.7:616.831-005]-073  
<https://doi.org/10.2298/MPNS2208254K>

## SYSTEMIC EMBOLIC EVENTS ASSOCIATED WITH PERSISTENT FORAMEN OVALE – A CASE REPORT

*SISTEMSKI EMBOLIJSKI DOGAĐAJI POVEZANI SA PERZISTENTNIM FORAMENOM OVALE  
 – PRIKAZ SLUČAJA*

Tijana KOKOVIĆ<sup>1</sup>, Nikola BATINIĆ<sup>2,3</sup>, Željko ŽIVANOVIĆ<sup>2,4</sup> and Viktor TILL<sup>1,2</sup>

### Summary

**Introduction.** Embolization into the systemic circulation through the persistent foramen ovale is known as paradoxical embolization. Coexistence of paradoxical embolism with pulmonary thromboembolism is rare and it requires detailed examination. The objective of this study was to present an unusual case of stroke that was complicated by the occurrence of pulmonary thromboembolism, with thrombosis of the superior mesenteric artery, and arterial infarction of numerous visceral organs, a few days after its onset. **Case Report.** A 60-year-old female patient was admitted to the Emergency Center with clinical symptoms of acute ischemic stroke, with sudden left hemiparesis. Computed tomography showed a fresh ischemia in the basin of the right anterior cerebral artery. The initial clinical course was favorable, with gradual regression of neurological symptoms. On the seventh day of hospitalization, the patient presented with a sudden worsening of symptoms. Computed tomography confirmed multiple infarctions of the liver, spleen and both kidneys, partial thrombosis of the superior mesenteric artery, as well as thrombosis of both pulmonary arteries and two fresh ischemic zones, namely right temporal and parieto-occipital, cortico-subcortical. A persistent foramen ovale was found by transesophageal echocardiography, which also confirmed the existence of an atrial septal aneurysm. In the further course, there was an improvement of symptoms. The patient was referred for further rehabilitation therapy. A surgical closure of persistent foramen ovale was indicated. **Conclusion.** Paradoxical embolism remains a pathology rarely mentioned by clinicians, although it can affect the functional and vital status and prognosis of the patient. Good cardiac evaluation and detection of persistent foramen ovale in every patient with embolic ischemia is of great importance.

**Key words:** Foramen Ovale, Patent; Embolism, Paradoxical; Tomography, X-Ray Computed; Heart Aneurysm; Infarction; Stroke; Pulmonary Embolism; Diagnosis; Signs and Symptoms

### Introduction

Simultaneous occurrence of stroke, pulmonary thromboembolism, arterial thrombosis and multiple infarctions of visceral organs is rare and requires detailed investigation [1].

### Sažetak

**Uvod.** Pojava embolizacije u sistemsku cirkulaciju kroz perzistentni foramen ovale naziva se paradoksalna embolizacija. Pojava paradoksalne embolizacije istovremeno sa plućnom tromboembolijom je retka i zahteva detaljan pregled. Cilj rada je prikaz neuobičajenog slučaja moždanog udara koji je nekoliko dana nakon početka bio komplikovan pojavom plućne tromboembolije, sa trombozom gornje mezenterične arterije i arterijskim infarktom brojnih visceralnih organa. **Prikaz slučaja.** Pacijentkinja stara 60 godina primljena je u Urgentni centar sa kliničkom slikom akutnog ishemijskog moždanog udara, sa iznenadnom levom hemiparezom. Kompjuterizovanom tomografijom je potvrđena sveža ishemija u slivu desne prednje moždane arterije. Inicijalni klinički tok je bio povoljan, uz postepenu regresiju neuroloških tegoba. Sedmog dana hospitalizacije došlo je do naglog pogoršanja simptoma. Kompjuterizovanom tomografijom su potvrđeni višestruki infarkti jetre, slezine i oba bubrega, uz prisustvo parcijalne tromboze gornje mezenterične arterije, kao i tromboza obe plućne arterije i dve sveže moždane ishemijske zone i to desno temporalno i parijeto-okcipitalno, kortiko-supkortikalno. Perzistentni foramen ovale je dokazan transezofagealnom ehokardiografijom, čime je potvrđeno i postojanje atrijalne septalne aneurizme. U daljem toku došlo je do poboljšanja tegoba. Pacijentkinja je upućena na dalji rehabilitacioni tretman. Postavljena je indikacija za operativno rešavanje perzistentnog foramena ovale. **Zaključak.** Paradoksalna embolija je patologija koja se retko pominje među kliničarima, iako može uticati na funkcionalno i vitalno stanje i prognozu pacijenta. Kod svakog pacijenta sa embolijskom ishemijom veoma je važna dobra kardiološka evaluacija i detekcija perzistentnog foramena ovale.

**KLjučne reči:** perzistentni foramen ovale; sistemska embolizacija; CT; srčana aneurizma; moždani udar; pulmonarni tromboembolizam; dijagnoza; znaci i simptomi

The mechanism of venous and arterial thrombosis is different. In the literature, their simultaneous occurrence is described in patients with persistent foramen ovale (PFO), atrial septal defect, pulmonary arteriovenous fistulas, and some other arteriovenous shunts [2].

**Abbreviations**

PFO	– persistent foramen ovale
PDE	– paradoxical embolism
SMA	– superior mesenteric artery
CT	– computed tomography
ACA	– anterior cerebral artery
CDUS	– color duplex ultrasound

Foramen ovale is an inter-atrial communication in the fetal period. The PFO occurs in about 25% of the population, and the prevalence is significantly higher in patients with stroke of unclear cause [3].

Embolization into the systemic circulation through a PFO is known as paradoxical embolism (PDE). The occurrence of PDE simultaneously with pulmonary thromboembolism is rare and it is mainly part of a paraneoplastic syndrome, or it is found in patients with thrombophilia [2].

Patients with combined venous and arterial thrombosis require combined anticoagulant and antiplatelet therapy. Studies have shown that closing a PFO significantly reduces the risk of stroke [4, 5].

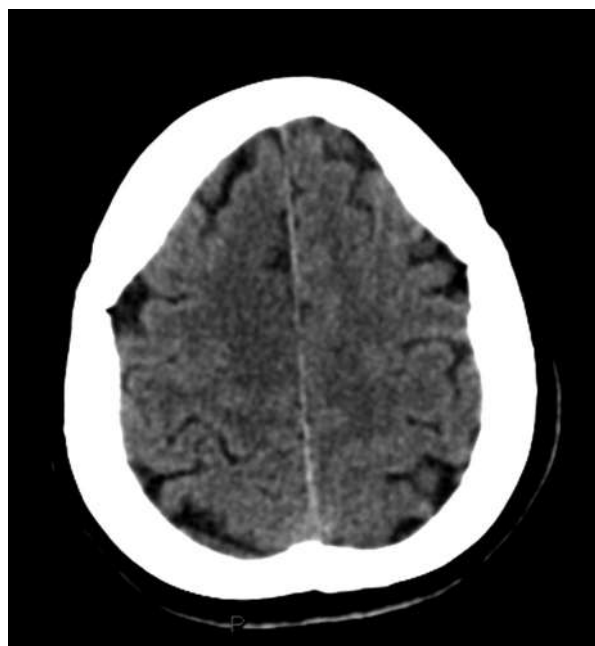
In this paper, we present an unusual case of stroke that was complicated by the occurrence of pulmonary thromboembolism, thrombosis of the superior mesenteric artery (SMA) and arterial infarction of numerous visceral organs a few days after its onset.

**Case Report**

A 60-year-old female patient was admitted to the Emergency Center with clinical symptoms of an acute ischemic stroke, with sudden left hemiparesis. The complaints started on the same day and were not accompanied by other symptoms. The patient denied comorbidities and risk factors for cerebrovascular diseases. At the time of admission, the patient was conscious, oriented and communicative, hemodynamically stable, and the neurological findings showed a left sided crural hemiparesis, National Institutes of Health stroke scale score 8. Computed tomography (CT) of the brain confirmed fresh ischemia in the basin of the right anterior cerebral artery (ACA) (**Figure 1**). A color duplex ultrasound (CDUS) of the carotid and vertebral arteries was performed, as well as a transcranial Doppler of the circle of Willis, where no stenotic lesions were detected. Routine laboratory findings were within normal limits.

Upon admission to the Neurology Clinic, sphenopalatine ganglion stimulation was initiated and it lasted for 5 days. The initial clinical course was favorable, with gradual regression of neurological symptoms. A control CT of the brain performed on the fifth day showed a clearly demarcated cortico-subcortical infarction in the basin of the right ACA, with signs of hemorrhagic transformation (**Figure 2**). The patient was hemodynamically and rhythmically stable. The lipid status was normal.

On the seventh day of hospitalization, the patient presented with a sudden worsening of symptoms, with abdominal pain, nausea and vomiting, and on

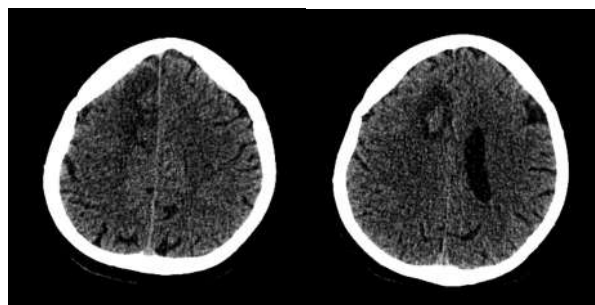


**Figure 1.** CT of the brain, fresh ischemia in the basin of the right anterior cerebral artery

*Slika 1. Snimak mozga kompjuterizovanom tomografijom – sveža ishemija u slivu desne prednje cerebralne arterije*

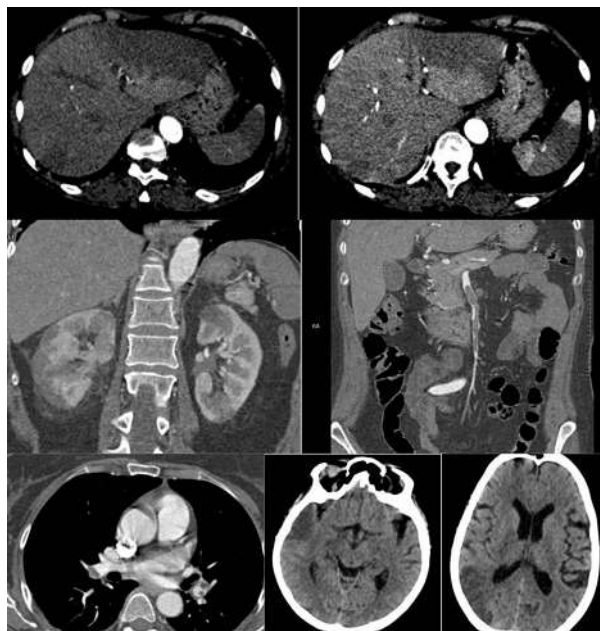
the following day, hemianopsia appeared on the left. The patient was examined by an internist and a gastroenterologist and an ultrasound of the abdomen and an X-ray of the lungs and heart were performed, where no pathological changes were found.

The laboratory findings showed an increase in pro-inflammatory parameters (C-reactive protein and procalcitonin), as well as high D-dimer values. Gastroscopy showed hyperemia of the duodenum, probably of vascular ischemic etiology. A CT of the abdomen and pelvis was performed and it showed multiple infarctions of the liver, spleen and both kidneys, with the presence of partial thrombosis of the



**Figure 2.** Control CT of the brain performed on the fifth day, cortico-subcortical infarction in the basin of the right anterior cerebral artery with signs of hemorrhagic transformation

*Slika 2. Kontrolni snimak mozga kompjuterizovanom tomografijom petog dana, kortiko-supkortikalni infarkt u slivu desne prednje cerebralne arterije sa hemoragičnom transformacijom*



**Figure 3.** Multiple infarctions of the liver, spleen and both kidneys, partial thrombosis of the superior mesenteric artery, thrombosis of both pulmonary arteries, fresh ischemic zones – right temporal and parieto-occipital, cortico-subcortical

**Slika 3.** Multipli infakti jetre, slezine i oba bubrega, parcijalna tromboza gornje mezenterične arterije, tromboza obe pulmonalne arterije, sveže ishemijske zone – desno temporalno i parijeto-okcipitalno, kortiko-supkortikalno

SMA, as well as thrombosis of both pulmonary arteries (**Figure 3**). In the same act, a CT of the brain was performed, where two fresh ischemic zones were found, right temporal and parieto-occipital, cortico-subcortical (**Figure 3**). An urgent echocardiography of the heart was performed, which was without thrombotic masses in the heart cavities.

Anticoagulant therapy with high doses of low molecular weight heparin was initiated, with gradual transfer to oral anticoagulant therapy. Laboratory tests were performed in the direction of thrombophilia and immune disorders. Immunological tests indicated the presence of antinuclear antibodies on HeP-2 cells, positive nucleoplasm, while other findings were negative. During the entire hospitalization, the patient was hemodynamically stable, conscious, oriented and communicative.

The existence of PFO was suspected by transcranial Doppler bubble ultrasonography and it was also confirmed by transesophageal echocardiography, as well as an atrial septal aneurysm. Deep and superficial vein thrombosis was ruled out by CDUS of the veins of the lower extremities.

In the further course, there was an improvement of the complaints, as well as a gradual normalization of the laboratory parameters. A control CT of the brain, thorax, abdomen and pelvis with native, arterial and venous phase was performed 10 days later. The previously described ischemias of the brain were in the

chronification phase, without new fresh ischemias. Both pulmonary arteries and SMA were completely recanalized. The liver parenchyma was without signs of previously described ischemic zones. Ischemic lesions of the spleen were in the chronic phase. Ischemic lesions persisted on the right kidney also in the chronic phase. On the left kidney, the ischemic zones subsided. There were no infiltrative lesions on the control CT of the chest, abdomen and pelvis.

After the rehabilitation treatment started, there was a significant regression of the neurological deficit, with residual mild left-sided hemiparesis, dominantly expressed on the leg with the National Institutes of Health stroke score 2. Walking was performed with aid (Modified Rankin Score 3). The patient was referred for further rehabilitation treatment. A surgical closure of PFO was indicated.

### Discussion

Ischemic strokes can be classified into two major categories: a) those with a known cause, such as large-artery atherosclerosis, intracardiac thrombus, small-artery occlusion, and b) those without a known cause, i.e. cryptogenic infarction.

The detection of a PFO in a patient with a confirmed stroke does not necessarily mean that the cause of the stroke has been identified [6].

A PDE is expected to cause brain infarcts that are similar on brain imaging to those of other (cardiac or arterial) embolic causes. At brain imaging, the occlusion of a superficial arterial branch or the presence of a large infarct involving more than one lobe is strongly suggestive of embolic infarction, which was identified in our patient [7].

Scattered lesions or cortical-subcortical territorial lesions are also indicative of embolic infarction. Multiple acute infarcts, especially those that are bilateral and affect various networks of cerebral circulation, are strong indicators of a proximal embolic source or a systemic cause [7, 8]. Our patient presented with scattered lesions, cortical-subcortical territorial lesions, and multiple acute infarcts.

Although the presence of hemorrhagic transformation is a strong indicator of embolic infarction, published data do not demonstrate an association between PFO and hemorrhagic infarcts [9].

The presence of one or more aberrant anatomic structures in association with a PFO can increase the probability of PDE. These abnormal structures include a Chiari network, an atrial septal aneurysm, and a persistent Eustachian valve. Cryptogenic stroke with an “embolic” pattern is more common when PFO and atrial septal aneurysm coexist [10], which was found in our patient by transesophageal echocardiography.

An atrial septal aneurysm is another important anatomic feature to consider when evaluating PFO. An atrial septal aneurysm is defined as a bulge that protrudes more than 15 mm beyond the plane of the atrial septum [11].

Atrial septal aneurysms are found in approximately 4.6 – 10% of cases by transesophageal

echocardiography. An atrial septal aneurysm associated with a PFO has a prevalence of 30 – 60% and is most likely associated with an increased rate of embolic events. Among patients with normal patency of the carotid arteries, which was the case in our patient, atrial septal aneurysm is more prevalent in those with cerebral ischemia (28%) than in those without cerebral ischemia (10%) [12, 13].

The PFO is implicated in the pathogenesis of many diseases [14, 15]. The precise incidence of PDE that complicates PFO is unknown. The PDE occurs in a minority of patients with venous thromboembolic disease who also have a PFO. In patients with a PFO, pulmonary embolism is thought to be associated with a small but definite risk for PDE [16].

Patients with a PFO and hemodynamically important pulmonary embolism are more likely to experience an ischemic stroke (13% vs 2.2%), peripheral arterial embolism (15% vs 0%), and arterial hypoxemia, possibly due to PDE [17, 18].

Although PDE is an uncommon cause of acute arterial occlusion, it can have catastrophic sequelae, and the possibility that it is present should be considered in all patients with an arterial embolus in the absence of a cardiac or proximal arterial source. It is

frequently associated with cryptogenic stroke and peripheral embolism [19]. Uncommon complications include brain abscess, decompression sickness in scuba divers, myocardial infarction, and mesenteric infarction [20–23]. On the seventh day of our patient's hospitalization, a CT of the abdomen and pelvis showed multiple infarcts of the liver, spleen and both kidneys, with the presence of partial thrombosis of the SMA, as well as thrombosis of both pulmonary arteries, with subsequent chronification or regression - the pulmonary arteries were completely recanalized, as well as SMA. The liver parenchyma was without signs of ischemia and the ischemic lesions of the spleen were in the chronification phase. Ischemic lesions persisted on the right kidney also in the chronic phase. On the left kidney, the ischemic zones subsided.

### Conclusion

Paradoxical embolism remains a pathology rarely mentioned by clinicians, although it may affect the functional and vital prognosis of the patient. Good cardiac evaluation and detection of persistent foramen ovale in every patient with embolic ischemia is important.

### References

1. Chakir M, El Jamili M, Boudhar Z, El Hattou M. Simultaneous acute myocardial infarction, bilateral pulmonary embolism, and acute ischaemic cerebral stroke, a delayed complication in a patient with COVID-19 infection: case report. *Eur Heart J Case Rep.* 2021;5(6):ytab218.
2. Xie XJ, Jiang JB, Jiang J, Wang JA. Concurrent pulmonary thrombosis with systemic embolism: a case report. *J Zhejiang Univ Sci B.* 2014;15(9):838-44.
3. Abdelghani M, El-Shedoudy SAO, Nassif M, Bouma BJ, de Winter RJ. Management of patients with patent foramen ovale and cryptogenic stroke: an update. *Cardiology.* 2019;143(1):62-72.
4. Anantha-Narayanan M, Anugula D, Das G. Patent foramen ovale closure reduces recurrent stroke risk in cryptogenic stroke: a systematic review and meta-analysis of randomized controlled trials. *World J Cardiol.* 2018;10(6):41-8.
5. Collado FMS, Poulin MF, Murphy JJ, Jneid H, Kavinsky CJ. Patent foramen ovale closure for stroke prevention and other disorders. *J Am Heart Assoc.* 2018;7(12):e007146.
6. Banana Y, Rezziki A, Kallel O, Rasras H, Bazid Z, El Ouafi N, et al. Multiple paradoxical embolisms revealing a patent foramen ovale in a patient with deep venous thrombosis: a case report. *Ann Med Surg (Lond).* 2021;66:102426.
7. Wessels T, Röttger C, Jauss M, Kaps M, Traupe H, Stolz E. Identification of embolic stroke patterns by diffusion-weighted MRI in clinically defined lacunar stroke syndromes. *Stroke.* 2005;36(4):757-61.
8. Kang DW, Chalela JA, Ezzeddine MA, Warach S. Association of ischemic lesion patterns on early diffusion-weighted imaging with TOAST stroke subtypes. *Arch Neurol.* 2003;60(12):1730-4.
9. Steiner MM, Di Tullio MR, Rundek T, Gan R, Chen X, Liguori C, et al. Patent foramen ovale size and embolic brain imaging findings among patients with ischemic stroke. *Stroke.* 1998;29(5):944-8.
10. Santamarina E, González-Alujas MT, Muñoz V, Rovira A, Rubiera M, Ribó M, et al. Stroke patients with cardiac atrial septal abnormalities: differential infarct patterns on DWI. *J Neuroimaging.* 2006;16(4):334-40.
11. Hanley PC, Tajik AJ, Hynes JK, Edwards WD, Reeder GS, Hagler DJ, et al. Diagnosis and classification of atrial septal aneurysm by two-dimensional echocardiography: report of 80 consecutive cases. *J Am Coll Cardiol.* 1985;6(6):1370-82.
12. Mattioli AV, Aquilina M, Oldani A, Longhini C, Mattioli G. Atrial septal aneurysm as a cardioembolic source in adult patients with stroke and normal carotid arteries. A multicentre study. *Eur Heart J.* 2001;22(3):261-8.
13. Mügge A, Daniel WG, Angermann C, Spes C, Khandheria BK, Kronzon I, et al. Atrial septal aneurysm in adult patients: a multicenter study using transthoracic and transesophageal echocardiography. *Circulation.* 1995;91(11):2785-92.
14. Gerriets T, Tetzlaff K, Hutzelmann A, Liceni T, Kopiske G, Struck N, et al. Association between right-to-left shunts and brain lesions in sport divers. *Aviat Space Environ Med.* 2003;74(10):1058-60.
15. De Castro S, Cartoni D, Fiorelli M, Rasura M, Anzini A, Zanette EM, et al. Morphological and functional characteristics of patent foramen ovale and their embolic implications. *Stroke.* 2000;31(10):2407-13.
16. Clergeau MR, Hamon M, Morello R, Saloux E, Viader F, Hamon M. Silent cerebral infarcts in patients with pulmonary embolism and a patent foramen ovale: a prospective diffusion-weighted MRI study. *Stroke.* 2009;40(12):3758-62.
17. Konstantinides S, Geibel A, Kasper W, Olschewski M, Blümel L, Just H. Patent foramen ovale is an important predictor of adverse outcome in patients with major pulmonary embolism. *Circulation.* 1998;97(19):194-51.
18. Kasper W, Geibel A, Tiede N, Just H. Patent foramen ovale in patients with haemodynamically significant pulmonary embolism. *Lancet.* 1992;340(8819):561-4.

19. Hausmann D, Mügge A, Becht I, Daniel WG. Diagnosis of patent foramen ovale by transesophageal echocardiography and association with cerebral and peripheral embolic events. *Am J Cardiol.* 1992;70(6):668-72.

20. Dethy S, Manto M, Kentos A, Konopnicki D, Pirotte B, Goldman S, et al. PET findings in a brain abscess associated with a silent atrial septal defect. *Clin Neurol Neurosurg.* 1995; 97(4):349-53.

21. Gerriets T, Tetzlaff K, Hutzelmann A, Liceni T, Kopsiske G, Struck N, et al. Association between right-to-left shunts and

Rad je primljen 24. XI 2022.

Recenziran 8. I 2023.

Prihvaćen za štampu 9. I 2023.

BIBLID.0025-8105:(2022):LXXV:7-8:254-258.

brain lesions in sport divers. *Aviat Space Environ Med.* 2003;74 (10):1058-60.

22. Adams HP Jr, Bendixen BH, Kappelle LJ, Biller J, Love BB, Gordon DL, et al. Classification of subtype of acute ischemic stroke. Definitions for use in a multicenter clinical trial. TOAST. Trial of Org 10172 in Acute Stroke Treatment. *Stroke.* 1993;24(1):35-41.

23. Loscalzo J. Paradoxical embolism: clinical presentation, diagnostic strategies, and therapeutic options. *Am Heart J.* 1986; 112(1):141-5.

University of Novi Sad, Faculty of Medicine Novi Sad,  
 Department of Histology and Embryology, Novi Sad<sup>1</sup>  
 Clinical Center of Vojvodina Novi Sad, Pathology and Histology Center<sup>2</sup>  
 Institute for Pulmonary Diseases of Vojvodina, Sremska Kamenica  
 Clinic of Granulomatous and Interstitial Lung Diseases<sup>3</sup>  
 Clinical Center of Vojvodina Novi Sad, Emergency Center, COVID Hospital<sup>4</sup>  
 Otorhinolaryngology and Head and Neck Surgery Clinic<sup>5</sup>  
 Clinic of Gynecology and Obstetrics<sup>6</sup>

Case report  
*Prikaz slučaja*  
 UDK 616.68-033.2-036.8  
 UDK 616-006.44-06  
<https://doi.org/10.2298/MPNS2208259I>

## BONE MARROW METASTASIS FROM TESTICULAR SEMINOMA IN A PATIENT WITH CONCOMITANT FOLLICULAR NON-HODGKIN LYMPHOMA – A CASE REPORT

*METASTAZA SEMINOMA U KOŠTANU SRŽ PACIJENTA SA KONKOMITANTNIM FOLIKULARNIM NON-HOČKIN LIMFOMOM – PRIKAZ SLUČAJA*

Jelena ILIĆ SABO<sup>1,2</sup>, Stefan IVIĆ<sup>2</sup>, Ana MILENKOVIĆ<sup>3</sup>, Milica TRKULJA<sup>4</sup>,  
 Vanja TOVILOVIĆ<sup>5</sup> and Borislav GOLIJAN<sup>6</sup>

### Summary

**Introduction.** Seminomas are the most common testicular tumors. Initial therapy includes orchiectomy with resection of local lymph nodes, followed by adjuvant radiotherapy. Testicular tumors usually metastasize to retroperitoneal and mediastinal lymph nodes, lungs, liver, spleen, gastrointestinal tract, and adrenal glands. Bone metastases from testicular tumors are very rare, while seminoma metastasis to the bone marrow is a curiosity, without any references in the scientific literature. **Case Report.** A 66-year-old patient, previously treated for follicular non-Hodgkin lymphoma, was admitted due to complaints of malaise, abdominal and back pain, and hepatosplenomegaly. After examination and radiologically verified enlarged retroperitoneal lymph nodes, the patient was referred to a hematologist. Based on the patient's medical history, a relapse of lymphoma was suspected, and bone marrow biopsy was performed. The hematoxylin-eosin staining of the biopsy sample showed diffuse large cell infiltrates with bright cytoplasm, polygonal nuclei and prominent nucleoli. By immunohistochemical staining, the cells showed positivity for cluster of differentiation 10, cluster of differentiation 117, octamer binding transcription factor 3/4, placental alkaline phosphatase, and cytokeratin 8/18, after which the diagnosis of seminoma metastasis to the bone marrow was made. Shortly after the histopathological diagnosis was made, the patient died. **Conclusion.** A seminoma is a testicular tumor with a favorable prognosis. Due to suppression of hematopoiesis, bone marrow metastases generally lead to the worst prognosis. The outcome of our patient highlights the importance of timely diagnosis and therapy, which would increase the chances of survival.

**Key words:** Bone Marrow; Neoplasm Metastasis; Testicular Neoplasms; Seminoma; Lymphoma, Non-Hodgkin; Biopsy; Immunohistochemistry

### Introduction

Seminomas are the most common testicular tumors. They usually occur in patients aged 40 to 50 years, presenting as painless testicular masses [1, 2].

### Sažetak

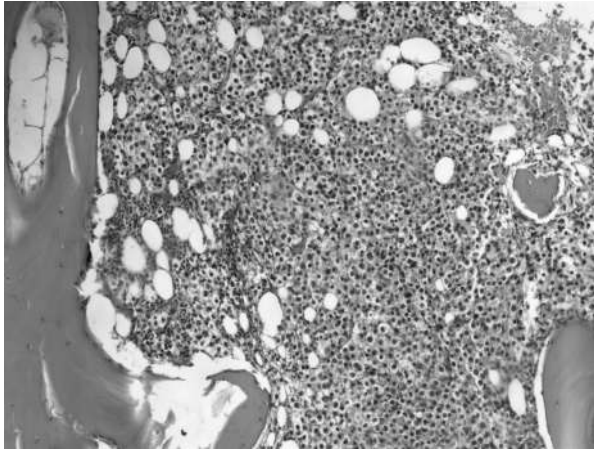
**Uvod.** Seminomi su najčešći tumori testisa. Primarnu terapiju predstavlja orhiektomija sa resekcijom lokalnih limfnih nodusa, nakon čega sledi adjuvantna radioterapija. Tumori testisa najčešće metastaziraju u retroperitonealne, medijastinalne limfne noduse, pluća, jetru, slezinu, gastrointestinalni trakt i nadbubrežne žlezde. Retki su slučajevi koštanih metastaza tumora testisa, dok metastaza seminoma u koštanu srž predstavlja kuriozitet bez postojećih navoda u literaturi. **Prikaz slučaja.** Pacijent starosti 66 godina, ranije lečen od folikularnog nehoćkinskog limfoma, javlja se na pregled zbog tegoba u vidu malaksalosti, bolova u stomaku i leđima i hepatosplenomegalije. Nakon pregleda i radiološki verifikovanih uvećanih retroperitonealnih limfnih čvorova, pacijent je upućen hematologu. Na osnovu anamnestičkih podataka, postavljena je sumnja na relaps limfoma, nakon čega je načinjena biopsija koštane srži. U biopičkom uzorku, bojenom hematoksilin-eozin metodom, uočena je difuzna ćelijska infiltracija krupnim ćelijama, svetle citoplazme, poligonalnih jedara sa prominentnim jedarcima. Imunohistohemijskim bojenjem ćelije su pokazale pozitivnost na CD10, CD117, OCT3/4, PLAP, CK8/18 nakon čega je postavljena dijagnoza metastaze seminoma u koštanoj srži. Ubrzo nakon postavljanja patohistološke dijagnoze, pacijent je preminuo. **Zaključak.** Seminom spada u prognostički povoljne tumore. Metastaze u koštanoj srži, zbog supresije hematopoeze, generalno dovode do lošije prognoze za pacijente. Ishod bolesti našeg prikazanog pacijenta upravo ukazuje na lošiju prognozu, kao i na važnost pravovremene dijagnostike i terapije, čime bi šanse za preživljavanjem bile veće.

**Glavne reči:** koštana srž; metastaze; neoplazme testisa; seminom; non-Hoćkinov limfom; biopsija; imunohistohemija

Macroscopically, seminomas are soft, well-demarcated, grayish-white tumors that bulge from the cut surface of the affected testis. Large tumors may contain foci of necrosis, usually without hemorrhage. They are composed of large, uniform cells with dis-

### Abbreviations

CD10	– cluster of differentiation 10
CD117	– cluster of differentiation 117
PLAP	– placental alkaline phosphatase
OCT3/4	– octamer binding transcription factor 3/4
CK8/18	– cytokeratin 8/18
HE	– hematoxylin and eosin



**Figure 1.** Bone marrow metastasis from a testicular seminoma (HE x 100); Diffuse large cell infiltrates with bright cytoplasm, polygonal nuclei and prominent nucleoli in the bone marrow

**Slika 1.** Metastaza seminoma u koštanoj srži, hematoxilin-eozin x 100 – Difuzna infiltracija koštane srži krupnim ćelijama, svetle citoplazme, poligonalnih jedara sa prominentnim jedarcima

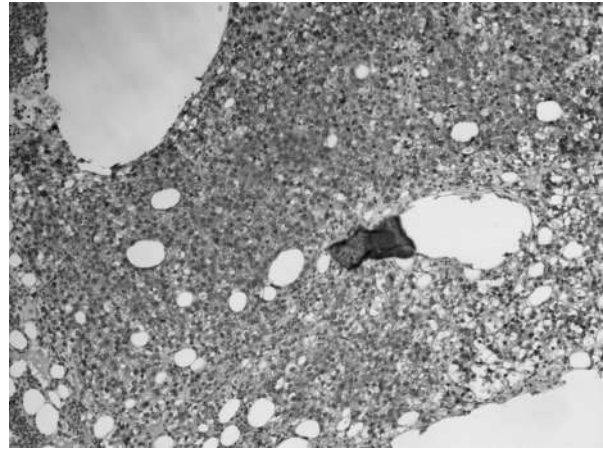
tinct cellular borders, clear, glycogen-rich cytoplasm, round nuclei with conspicuous nucleoli. The cells are often arranged in small lobules, separated by fibrous septa. Lymphocytic infiltrate is usually present and may overshadow the neoplastic cells [1, 2].

Initial therapy includes orchiectomy with resection of local lymph nodes, followed by adjuvant radiotherapy or chemotherapy [1, 2]. There are few techniques for fertility preservation, such as cryopreservation of gametes and embryos which proved to be efficient and safe, while there are also some experimental techniques like cryopreservation of gonadal tissue and cells that are not yet used in daily practice [3].

Testicular tumors most often metastasize to retroperitoneal and mediastinal lymph nodes, lungs, liver, spleen, gastrointestinal tract, and adrenal glands. Bone metastases from testicular tumors are very rare, while metastasis from seminoma to the bone marrow is a curiosity, not reported in scientific literature [4, 5].

### Case Report

A 66-year-old patient, previously treated for follicular non-Hodgkin lymphoma, was admitted due to complaints of malaise, abdominal and back pain, and hepatosplenomegaly. After the initial physical examination and radiologically verified enlarged retroperitoneal lymph nodes, the patient was re-

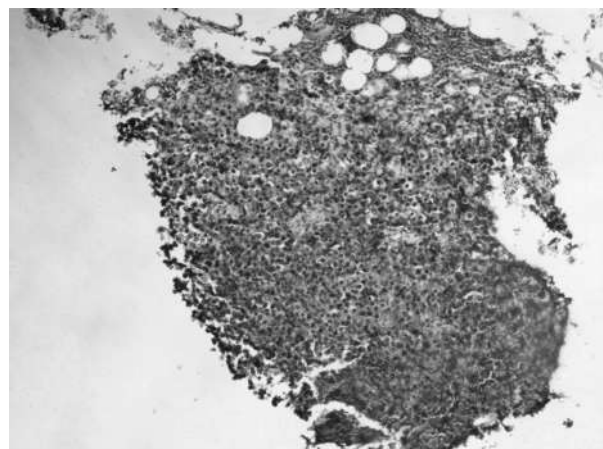


**Figure 2.** Seminoma tumor cells in the bone marrow express immunohistochemical positivity for CD 117 (HE x 100)

**Slika 2.** Tumorske ćelije seminoma u koštanoj srži pokazuju imunohistohemijsku pozitivnost na CD 117, hematoxilin-eozin x 100

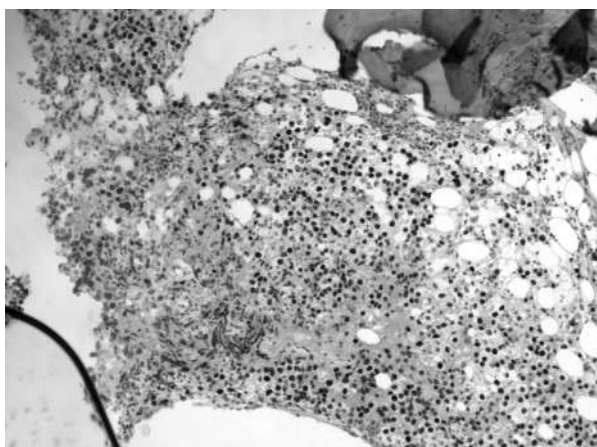
ferred to a hematologist. Based on the patient's medical history, a relapse of lymphoma was suspected, and trephine bone marrow biopsy was performed.

The hematoxylin-eosin (HE) staining of the biopsy sample showed diffuse large cell infiltrates with bright cytoplasm, polygonal nuclei and prominent nucleoli (**Figure 1**). The cells showed immunohistochemical positivity for cluster of differentiation 10 (CD10), cluster of differentiation 117 (CD117) (**Figure 2**), placental alkaline phosphatase (PLAP) (**Figure 3**), octamer binding transcription factor (OCT) 3/4 (**Figure 4**), and cytokeratin (CK) 8/18, after which the diagnosis of seminoma metastasis to the bone marrow was made. Shortly after the histopathological diagnosis was made, the patient unfortunately died.



**Figure 3.** Seminoma tumor cells in the bone marrow express immunohistochemical positivity for PLAP (HE x 100)

**Slika 3.** Tumorske ćelije seminoma u koštanoj srži pokazuju imunohistohemijsku pozitivnost na placentalnu alkalnu fosfatazu, hematoxilin-eozin x100



**Figure 4.** Seminoma tumor cells in the bone marrow express immunohistochemical positivity for OCT3/4 (HE x 100)

**Slika 4.** Tumorske ćelije seminoma u koštanoj srži pokazuju imunohistohemijsku pozitivnost na OCT3/4, hematoxilin-eozin x 100

### Discussion

As mentioned above, seminomas are the most common testicular tumors, followed by mixed germ cell tumors, often including seminomas. In the majority of cases the disease is diagnosed in the early stage [1, 2]. Even though, subclinical metastases in the retroperitoneum occur in about 15 – 20% of patients with stage I seminoma. Since the risk of disease recurrence is considerably high, the initial therapy includes radical orchiectomy followed by adjuvant radiotherapy, sometimes combined with chemotherapy [1, 2]. Germ cell testicular tumors have worse prognosis than seminomas, with recurrence and distant metastases being much more common [6].

The common sites of testicular tumors metastases are retroperitoneal and mediastinal lymph nodes, lungs, liver, spleen, and suprarenal glands [1, 2]. Individual,

retrospective studies of testicular tumors noted some unusual sites of metastasis such as: kidneys, inferior vena cava, muscles, pelvis, seminal vesicles, prostate and pericardial tissue [4].

The bone metastases from testicular tumors are very rare (3 – 9%). The majority are found in patients with mixed germ cell tumors (77%), while pure seminomas account only for 23% of cases [6, 7]. According to the study of 154 autopsies of patients with testicular tumors, bone metastases were found only in 40 patients (26% of cases), but none of the metastases were in the bone marrow [7]. An extremely extensive study dealing with the presence of solid tumor metastases in the bone marrow, showed that out of 73 cases, just one bone marrow metastasis was from a testicular tumor (1.4%) [8]. A study that specially focused on seminomas showed that there were no cases of bone marrow metastases [9]. A study which analyzed 2,550 patients with bone metastases of primary tumors showed that there were only 3 cases of seminoma metastases in the bones [10]. There were also a few cases of seminoma metastases detected in the spinal cord [11] and also concomitant metastases in the bones and central nervous system [12]. A rare case of a non-seminomatous germ cell testicular tumor with jaw metastasis was also reported [13].

After an extensive literature research, we found only one case of bone marrow infiltration with mixed germ cell testicular tumor [6], but still we did not find a single case of bone marrow metastasis from testicular seminoma.

### Conclusion

A seminoma is a testicular tumor with a favorable prognosis. Due to suppression of hematopoiesis, bone marrow metastases generally lead to the worst prognosis. The outcome of our patient highlights the importance of timely diagnosis and therapy, which would increase the chances of survival.

### References

1. Oldenburg J, Berney DM, Bokemeyer C, Climent MA, Daugaard G, Gietema JA, et al. Testicular seminoma and non-seminoma: ESMO-EURACAN Clinical Practice Guideline for diagnosis, treatment and follow-up. *Ann Oncol.* 2022;33(4):362-75.
2. Albers P, Albrecht W, Algaba F, Bokemeyer C, Cohn-Cedermark G, Fizazi K, et al. Guidelines on testicular cancer: 2015 update. *Eur Urol.* 2015;68(6):1054-68.
3. Nikoletić K, Mihailović J, Matovina E, Žeravica, R, Srbovan, D. Reliability of positron emission tomography-computed tomography in evaluation of testicular carcinoma patients. *Med Pregl.* 2015;68(3-4):109-15.
4. Degirmencioglu S, Degirmencioglu B. Isolated femoral muscle and bone metastases rarely encountered in testicular seminoma. *Case Rep Oncol Med.* 2013;2013:780493.
5. Kumar U, Ramteke P, Das P, Gogia A, Tanwar P. Isolated bone marrow metastasis of testicular tumor: a rare cause of thrombocytopenia. *Urol Ann.* 2017;9(1):96-8.
6. Oing C, Oechsle K, Necchi A, Loriot Y, De Giorgi U, Flechon A, et al. Impact of primary metastatic bone disease in germ cell tumors: results of an International Global Germ Cell Tumor Collaborative Group G3 Registry Study. *Ann Oncol.* 2017;28(3):576-82.
7. Bredael JJ, Vugrin D, Whitmore WF Jr. Autopsy findings in 154 patients with germ cell tumors of the testis. *Cancer.* 1982;50(3):548-51.
8. Kilickap S, Erman M, Dincer M, Aksoy S, Harputluoglu H, Yalcin S. Bone marrow metastasis of solid tumors: clinicopathological evaluation of 73 cases. *Turkish Journal of Cancer.* 2007;37(3):85-8.
9. Rick O, Siegert W, Schwella N, Dubiel M, Krusch A, Beyer J. Seminoma: high-dose chemotherapy as salvage treatment for seminoma. *Bone Marrow Transplant.* 2002;30(3):157-60.
10. Jamal-Hanjani M, Karpathakis A, Kwan A, Mazhar D, Ansell W, Shamash J, et al. Bone metastases in germ cell tumours: lessons learnt from a large retrospective study. *BJU Int.* 2013;112(2):176-81.
11. Fard-Esfahani A, Marzban M, Emami-Ardekani A, Hassanzadeh-Rad A, Fallahi B, Beiki D, et al. Spinal cord me-



tastasis from testicular seminoma detected by F-18 FDG PET/CT study prior to neurological symptoms: an unusual presentation. *Iranian Journal of Nuclear Medicine*. 2016;24(2):147-9.

12. Gómez FJ, Báñez IA, González RL, Jiménez-Granero P, Dorado IB. 18F-FDG PET/CT with unusual bone and CNS metastases from testicular seminoma. *Int Braz J Urol*. 2015;41(2):393-4.

Rad je primljen 17. XI 2022.

Recenziran 7. XII 2022.

Prihvaćen za štampu 7. XII 2022.

BIBLID.0025-8105:(2022):LXXV:7-8:259-262.

13. Siverino RO, Uccello A, Giunta ML, Uccello M, Amadio P, Petrillo G. Non-seminomatous germ cell tumor metastasis to the jaw: an imaging case report. *Iran J Radiol*. 2016;13(3):e27812.

University of Novi Sad, Faculty of Medicine Novi Sad<sup>1</sup>  
 Clinical Center of Vojvodina, Novi Sad, Clinic of Infectious Diseases<sup>2</sup>  
 Institute of Public Health of Vojvodina, Novi Sad<sup>3</sup>

Case report  
*Prikaz slučaja*  
 UDK 616.98:578.828]:616.36-002  
 UDK 578.27  
<https://doi.org/10.2298/MPNS2208263D>

## FIRST REPORTED CASES OF HEPATITIS A VIRUS AND HUMAN IMMUNODEFICIENCY VIRUS COINFECTION IN VOJVODINA, SERBIA – A CASE REPORT

*PRVI PRIJAVLJENI SLUČAJEVI VIRUSA HEPATITIS A I VIRUSA HUMANE IMUNODEFICIJENCIJE U AUTONOMNOJ POKRAJINI VOJVODINI, SRBIJA – PRIKAZ SLUČAJA*

**Maja DRLJAČA<sup>1,2</sup>, Maja RUŽIĆ<sup>1,2</sup>, Daniela MARIĆ<sup>1,2</sup>, Natalija RAJIĆ<sup>1,2</sup>,  
 Jelena ĐURICA<sup>1,2</sup> and Svetlana ILIĆ<sup>3</sup>**

### Summary

**Introduction.** Hepatitis A virus is the most common cause of acute viral hepatitis, and in people over 25 years of age the disease may have different degrees of severity. Even though hepatitis A virus infection was long believed to be transmitted strictly by fecal-oral route, now this virus is classified among sexually transmitted diseases. Homosexual population, especially those positive for human immunodeficiency virus, is at the greatest risk of hepatitis A virus infection. **Case 1.** A twenty-six-year-old male homosexual was admitted with clinical and laboratory findings of acute hepatitis. The patient tested positive for enzyme-linked immunosorbent assay immunoglobulin M antibodies to hepatitis A virus and human immunodeficiency virus antibodies, and later on human immunodeficiency virus infection was confirmed by polymerase chain reaction test. After the discharge, the antiretroviral therapy was initiated. **Case 2.** A twenty-seven-year-old male homosexual was transferred to our clinic from the Regional Hospital, where he was hospitalized due to acute hepatitis A virus infection, after a positive serological test for anti-human immunodeficiency virus antibodies. Human immunodeficiency virus infection was confirmed by polymerase chain reaction test, and upon discharge, antiretroviral therapy was initiated. **Conclusion.** In order to take the most effective preventive measures, it is very important to identify individuals and groups at high risk of coinfection with human immunodeficiency virus and hepatitis A virus. Timely vaccination against hepatitis A virus among people living with human immunodeficiency virus is recommended and therefore it is necessary to design effective strategies for education of groups at risk.

**Key words:** Hepatitis A virus; HIV; HIV Infections; Risk Factors; Vaccination; Hepatitis A Vaccines; Coinfection

### Introduction

Hepatitis A virus (HAV) is the most common cause of acute viral hepatitis. In children and young adults the infection is often asymptomatic, but in people older than 25 years the disease may have

### Sažetak

**Uvod.** Virus hepatitisa A je najčešći uzročnik akutnog virusnog hepatitisa i kod osoba starijih od 25 godina bolest može biti različitog stepena težine. Iako se dugo verovalo da se virusna infekcija hepatitisa A prenosi isključivo fekooralno; sada se ovaj virus klasifikuje među seksualno prenosive bolesti. Jedna od grupa koja je u najvećem riziku od virusa hepatitisa A je homoseksualna populacija, a naročito pojedinci pozitivni na virus humane imunodeficijencije. **Prvi slučaj.** Dvadesetšestogodišnji muškarac, koji pripada homoseksualnoj populaciji, hospitalizovan je pod kliničkom i laboratorijskom slikom akutnog hepatitisa. Testiran je enzimski povezanim imunosorbent testom kojim su potvrđena imunoglobulin M antitela na virus hepatitisa A i na antitela na virus humane imunodeficijencije, a retrovirusna infekcija potvrđena je testom polimeraza lančane reakcije. Nakon otpusta iz bolnice započeta je antiretrovirusna terapija. **Drugi slučaj.** Dvadesetsedmogodišnji muškarac, koji pripada homoseksualnoj populaciji, nakon pozitivnog serološkog testa na IgM antitela na retrovirus prebačen je iz regionalne bolnice u kojoj je bio hospitalizovan zbog akutne virusne infekcije hepatitisa A. Retrovirusna infekcija je takođe potvrđena testom polimeraza lančane reakcije, a po otpustu je ordinirana antiretrovirusna terapija. **Zaključak.** Da bi se preduzele najefikasnije mere prevencije veoma je bitno identifikovati pojedince i grupe koje su u visokom riziku od koinfekcije retrovirusom i virusom hepatitisa A. Pravovremena vakcinacija protiv virusa hepatitisa A među ljudima koji žive sa virusom humane imunodeficijencije je preporučena, stoga je potrebno osmisliti efektivnu strategiju za edukaciju rizičnih grupa.

**Ključne reči:** hepatitis A virus; virus humane imunodeficijencije; HIV infekcija; faktori rizika; vakcinacija; hepatitis A vakcine; koinfekcija

different degrees of severity [1]. It was long believed that HAV is transmitted strictly by fecal-oral route, but recent studies also classify it as a sexually transmitted disease (STD). The population of men who have sex with men (MSM) is considered to be at an increased risk of hepatitis A infection, since they

**Abbreviations**

HAV	– hepatitis A virus
STD	– sexually transmitted disease
MSM	– men who have sex with men
HIV	– human immunodeficiency virus
ELISA	– enzyme-linked immunosorbent assay
IgM	– immunoglobulin M
PCR	– polymerase chain reaction
RNA	– ribonucleic acid
HCV	– hepatitis C virus
HBsAg	– hepatitis B surface antigen
ART	– antiretroviral therapy
PLHIV	– people living with human immunodeficiency virus
HBV	– hepatitis B virus

practice oro-anal sex more commonly. A few research papers, such as the research of Mazick et al., report several outbreaks of acute hepatitis caused by HAV in homosexual population [2–4], and others emphasize the fact that in human immunodeficiency virus (HIV) positive patients HAV viremia is prolonged compared to immunocompetent patients, and thus the risk of transmission is higher [5]. The aim of this case presentation is to emphasize the changes in epidemiological characteristics of HAV infection, highlight the need for mandatory testing regarding the sexual transmission of the virus, and stress the importance of educating the public and most importantly the MSM group about positive effects of HAV vaccination.

**Material and Methods**

Data on the epidemiology of HAV infection in the Autonomous Province of Vojvodina in the period from 2017 to 2021 were obtained from the Institute of Public Health of Vojvodina by the courtesy of Prim. Dr. Svetlana Ilić. In this study, we present two cases of acute hepatitis A in HIV infected patients. Both of these patients were Caucasian males, and belonged to the MSM population. Both patients were hospitalized at the Clinic of Infectious Diseases, Clinical Center of Vojvodina,

during July and August of 2022. As a case definition of acute hepatitis we included signs and symptoms of acute hepatitis infection associated with elevated levels of serum alanine aminotransferase and aspartate aminotransferase above 1,000 IU/L. The HAV infection was confirmed using enzyme-linked immunosorbent assay (ELISA) for the detection of immunoglobulin M (IgM) antibodies to hepatitis A virus. Both patients tested positive to the 4th generation ELISA anti-HIV test confirmed by polymerase chain reaction (PCR) ribonucleic acid (RNA) HIV tests.

**Case 1**

A twenty-six-year-old male, belonging to the group of MSM, was admitted to the Clinic of Infectious Diseases on the second day of illness. Based on clinical signs and laboratory findings, acute viral hepatitis was suspected. On admission, the patient complained of nausea, vomiting, loss of appetite and general malaise, yellow discoloration of the skin and sclera, as well as dark urine and pale stools which he noticed on the previous day. Initial laboratory tests showed elevated levels of transaminase, hyperbilirubinemia and mild leukopenia, increased lactate dehydrogenase and creatine kinase, as well as prolonged prothrombin time (**Table 1**). Abdominal ultrasound showed a splenomegaly (approximate dimensions 14 cm X 7 cm) and thickening of the gallbladder wall. The patient was admitted to the hospital for further diagnosis and treatment. He tested positive for ELISA IgM anti-HAV antibodies as well as ELISA anti-HIV antibodies. The diagnosis of HIV infection was confirmed using PCR RNA HIV test. The cluster of differentiation 4 lymphocyte (CD4) count at that time was 399 cells/mm<sup>3</sup>. The patient tested negative for anti-hepatitis C virus (HCV), hepatitis B surface antigen (HBsAg), anti-antibody to hepatitis B core antigen (HBc) total, IgM anti-HBc antibodies.

The further course of the disease was favourable with the expected dynamics of decline in transaminase levels and the patient was discharged after 13

**Table 1.** Laboratory findings on admission  
*Tabela 1. Laboratorijski nalazi uzeti na prijemu*

	Patient 1/Pacijent 1	Patient 2/Pacijent 2
Leucocytes (10 <sup>9</sup> /L)/Leukociti (10 <sup>9</sup> /L)	3.74	4.15
Total bilirubin (μmol/L)/Ukupni bilirubin (μmol/L)	104.6	57
Direct bilirubin (μmol/L)/Direktni bilirubin (μmol/L)	91.5	39.3
Aspartate aminotransferase (IU/L)/Aspartat aminotransferaza (IU/L)	2830	225
Alanine aminotransferase (IU/L)/Alanin aminotransferaza (IU/L)	6016	631
Gamma-glutamyl transferase (IU/L)/Gama glutamil transferaza (IU/L)	163	259
Prothrombin time (R)/Protrombinsko vreme (R)	1.36	1.06
Creatine kinase (IU/L)/Kreatin kinaza (IU/L)	1550	-
Lactate dehydrogenase (IU/L)/Laktat dehidrogenaza (IU/L)	1100	166
CD4 count (cells/mm <sup>3</sup> )/Broj CD4 ćelija (ćelija/mm <sup>3</sup> )	399	691
PCR HIV RNA (copies/ml)/PCR HIV RNK (kopija/ml)	<40	626460

*Legenda: PCR – lančana reakcija polimeraze; HIV – virus humane imunodeficijencije; RNK – ribonukleinska kiselina*

**Table 2.** Epidemiological data of HAV infection in Autonomous Province of Vojvodina  
**Tabela 2.** Epidemiološki podaci o infekciji virusom hepatitisa A u Autonomnoj pokrajini Vojvodini

Year/Godina	Sex/Pol	Age/Starost									Total/Ukupno
		1-4	7-9	10-14	15-19	20-29	30-39	40-49	50-59	60	
2017	M	0	2	4	3	1	5	3	3	2	23
	F	0	2	0	3	3	5	0	4	1	18
2018	M	0	0	1	1	0	3	3	0	0	8
	F	0	0	0	0	1	1	0	1	0	3
2019	M	0	0	0	0	1	0	1	0	1	3
	F	1	1	0	1	0	1	0	1	0	5
2020	M	0	0	0	0	0	0	0	0	0	0
	F	0	0	0	0	0	0	0	0	0	0
2021	M	0	0	0	1	0	0	0	0	0	1
	F	0	0	0	1	0	0	0	0	0	1
Total/Ukupno	M	0	2	5	5	2	8	7	3	3	35
	F	1	3	0	5	4	7	0	6	1	27

days (**Table 2**). Antiretroviral therapy (ART) (tenofovir/emtricitabine/dolutegravir) was initiated 7 days after the discharge. One month after ART initiation, CD4 level was 622 cells/mm<sup>3</sup>. Up to now, the patient had no new complaints and tolerated ART well.

## Case 2

A twenty-seven-year-old male, belonging to the group of MSM, was transferred to the Clinical Center of Vojvodina, under suspicion of HIV infection. Initially, he was hospitalized in the Regional Hospital with clinical symptoms and laboratory tests pointing to acute hepatitis. He presented with jaundice, darker urine and general malaise. He tested positive for both anti-HAV IgM and anti-HIV antibodies. After he was transferred to our institution, initial elevated levels of bilirubin and aminotransferases were found (**Table 1**), PCR RNA HIV test was positive with viral load of 626460 IU/ml and CD4 count of 691 cells/mm<sup>3</sup>. The hepatitis B virus (HBV) and HCV infections were excluded by ELISA testing (anti-HCV, HBsAg, anti-HBc total, anti-IgM anti-HBc). The patient was hospitalized in our Clinic of Infectious Diseases for a total of six days and was discharged in good general condition and improved laboratory findings. Seven days after the discharge, the patients started receiving ART (emtricitabine/tenofovir/dolutegravir). The patient feels fine, without complains. Three months after the beginning of the therapy, the viral load was less than 40 IU/ml.

## Discussion

The epidemiological situation worldwide concerning hepatitis A virus infection has changed significantly in the last few years. The European Center for Disease Prevention and Control reported several outbreaks of hepatitis A virus infection, largest one being in one of our neighbouring countries - Hungary [6]. Observing the epidemiological data

gathered from 2017 to 2021 in the Province of Vojvodina, there has been an increase of hepatitis A cases in recent years. In the Region of Vojvodina, HAV is more prevalent in males than in females (66% male, 34% female), most common in the age group between 30 – 39 years (**Table 2**). In 2022, 10 patients had HAV, 6 of them were male, the mean age 36.1 years. Two of them who are presented in this paper stated that they had unprotected sex with other men.

Although HAV has long been considered fecal-oral infection, in this era of good hygienic living conditions, sexual route of infection has become one of the main ways of contracting the virus. The MSM population is at risk of HAV infection because sexual practices facilitate fecal-oral transmission. It is a well known fact that the main mode of HIV transmission is unprotected anal sex. Many studies such as the study of Grulich et al., point to increase in MSM HIV incidence in Europe and the world, but none of them claims if the increase is because of the greater number of infected people or it is because more people are tested [7, 8]. Our center manages the needs of around 460 persons living with HIV (PLHIV). About two thirds of PLHIV were diagnosed in the asymptomatic stage of HIV infection, mostly at voluntary counselling testing sites. Regarding hepatitis coinfections, hepatitis B is considered endemic in MSM population and the prevalence of hepatitis B coinfections in PLHIV is about 20 times higher than in general population [9]. It is presumed that 6 – 10% of MSM population have HIV with HBV coinfection. Many studies deal with the reciprocal effect of HIV and HBV or HIV and HCV infection observing the interacting effect of these viruses on patient's organism [10]. In terms of HCV and HIV coinfection, it was found that the odds of contracting HCV were six times higher in PLHIV than in general population [11].

A group of researchers from Slovenia performed sequence-based typing and epidemiological investigation in order to identify circulating strains of HAV [12].

They reported an outbreak of HAV in the recent years which was linked to MSM population. Unsafe sexual behaviors put certain groups, such as MSM, at risk of contracting STDs, and condom use has not proven effective in preventing transmission of certain STDs such as HAV [13].

In this era of pre-exposure prophylaxis (PrEP), we observed a significant increase in STDs, like gonorrhoea and syphilis, so further increase in the incidence of HAV coinfections may be expected. It is often stressed that anal sex is the main route of contracting HIV, but when it comes to HAV, different routes of inoculation are possible. Since the HAV viral particles can be found in saliva, it is reasonable to assume that exchange of saliva through kissing is a way to get infected, without sexual contact [14]. Less is known about the effects of HAV infection on HIV positive patients. Study of Gallego et al. examined the effects of acute hepatitis A infection on HIV viral load in patients who were already on ART and proved that HIV viral load in patients infected with HAV is significantly higher, so transient detectable viremia can be expected in these patients [15]. This study also focused on severity of hepatitis, but observed no difference in clinical presentation in HIV positive compared to HIV negative patients. As previously shown, in our patients the course of HAV infection was uncomplicated and self-limiting.

Today, it is important to detect individuals and groups who are at high risk of contracting HIV and HAV, so frequent screening tests should be performed.

Farangel et al. stressed out the importance of designing good preventive and surveillance measures, health education of groups at risk, as well as the benefits of routine vaccination [12]. Men who have sex with men should be immunized against HAV, especially those who are HIV positive [16]. Two doses of inactivated HAV vaccine are recommended to increase the titre of protective antibodies to a sufficient level, but it was shown that three-dose schedule induces higher seroconversion rate and higher and longer lasting antibody titers [17]. This vaccine is safe for HIV positive patients, so strategy of preventive vaccination should be included in medical practice of physicians working with patients who belong to high-risk groups. Although there is not much data available on reciprocal effects of ART and HAV vaccine, it was shown that shorter duration of ART leads to lower titre of protective IgG antibodies, so the question of another dose of vaccine leaves much to be answered [18].

## Conclusion

As it was previously pointed out, the most important thing is to identify individuals and groups who are at high risk of getting human immunodeficiency virus and hepatitis A virus coinfection, so that most effective preventive measures can be taken. Timely vaccination against hepatitis A virus of people living with human immunodeficiency virus is recommended, and therefore it is necessary to design effective strategies for education of risk groups.

## References

1. Kumar S. Hepatitis A [Internet]. 2022 [modified 2022 Sep; cited 2023 Jan 16]. Available from: <https://www.msmanuals.com/home/liver-and-gallbladder-disorders/hepatitis/hepatitis-a>
2. Bell A, Ncube F, Hansell A, Davison KL, Young Y, Gilson R, et al. An outbreak of hepatitis A among young men associated with having sex in public venues. *Commun Dis Public Health*. 2001;4(3):163-70.
3. Mazick A, Howitz M, Rex S, Jensen IP, Weis N, Katzenstein TL, et al. Hepatitis A outbreak among MSM linked to casual sex and gay saunas in Copenhagen, Denmark. *Euro Surveill*. 2005;10(5):111-4.
4. Tortajada C, De Olalla PG, Pinto RM, Bosch A, Cayla J. Outbreak of hepatitis A among men who have sex with men in Barcelona, Spain, September 2008-March 2009. *Euro Surveill*. 2009;14(15).
5. Costa-Mattioli M, Allavena C, Poirier AS, Billaudel S, Raffi F, Ferre' V. Prolonged hepatitis A infection in an HIV-1 seropositive infected patient. *J Med Virol*. 2002;68(1):7-11.
6. European Centre for Disease Prevention and Control. Spread of hepatitis A virus strains of genotype 1B in several EU countries and the United Kingdom [Internet]. 2022 [cited 2023 Jan 12]. Available from: <https://www.ecdc.europa.eu/en/news-events/spread-hepatitis-virus-strains-genotype-1b-several-eu-countries-and-united-kingdom>
7. Grulich AE, Kaldor JM. Trends in HIV incidence in homosexual men in developed countries. *Sex Health*. 2008;5(2):113-8.
8. European Centre for Disease Prevention and Control; World Health Organization. HIV/AIDS surveillance in Europe 2007. Stockholm: European Centre for Disease Prevention and Control; WHO Regional Office for Europe; 2008.
9. Duric P, Rajcevic S, Ilic S, Milosevic V, Hintringer K, Fabri M, et al. Hepatitis B outbreak among men who have sex with men in the Autonomous Province of Vojvodina, Serbia. *LGBT Health*. 2018;5(1):91-3.
10. Park JS, Saraf N, Dieterich DT. HBV plus HCV, HCV plus HIV, HBV plus HIV. *Curr Gastroenterol Rep*. 2006;8(1):67-74.
11. Platt L, Easterbrook P, Gower E, McDonald B, Sabin K, McGowan C, et al. Prevalence and burden of HCV co-infection in people living with HIV: a global systematic review and meta-analysis. *Lancet Infect Dis*. 2016;16(7):797-808.
12. Fafangel M, Grilc E, Poljak M, Lunar MM, Trop-Skaza A, Kopilović B, et al. Hepatitis A virus transmission among men who have sex with men (MSM), Slovenia, May 2017-March 2018. *Eur J Public Health*. 2018;28(Suppl 4):367-8.
13. Neville S, Adams J. Condom use in men who have sex with men: a literature review. *Contemp Nurse*. 2009;33(2):130-9.
14. Mackiewicz V, Dussaix E, Petitcorps MF, Roque-Afonso AM. Detection of hepatitis A virus RNA in saliva. *J Clin Microbiol*. 2004;42(9):4329-31.
15. Gallego M, Robles M, Palacios R, Ruiz J, Nuno E, Marquez M, et al. Impact of acute hepatitis A virus (HAV) infection on HIV viral load in HIV-infected patients and influence of HIV infection on acute HAV infection. *J Int Assoc Physicians AIDS Care (Chic)*. 2011;10(1):40-2.
16. EACS. EACS guidelines [Internet]. 2022 [cited 2023Jan16]. Available from: <https://www.eacsociety.org/guidelines/eacs-guidelines/>

17. Launay O, Grabar S, Gordien E, Desaint C, Jegou D, Abad S, et al. Immunological efficacy of a three-dose schedule of hepatitis A vaccine in HIV-infected adults: HEPAVAC study. *J Acquir Immune Defic Syndr.* 2008;49(3):272-5.

Rad je primljen 8. II 2023.

Recenziran 2. III 2023.

Prihvaćen za štampu 6. III 2023.

BIBLID.0025-8105:(2022):LXXV:7-8:263-267.

18. Koga M, Senkoji T, Kubota M, Ishizaka A, Mizutani T, Sedohara A, et al. Predictors associated with a better response to the Japanese aluminum-free hepatitis A vaccine, Aimmugen®, for people living with HIV. *Hepatol Res.* 2022;52(3):227-34.



## IN MEMORIAM

### *IN MEMORIAM*

---



### **Prim. dr DEJAN KAFKA (1961–2022)**

Posle kratke i teške bolesti 30. septembra 2022. godine preselio se u večnost primarijus dr Dejan Kafka, specijalista dečje hirurgije.

Dejan Kafka je rođen 29. maja 1961. godine u Sarajevu. U rodnom gradu završio je osnovnu i srednju školu. Medicinski fakultet je završio u Sarajevu 30. januara 1985. godine. Dvanaestog februara 1987. godine zaposlio se, na neodređeno vreme, u Kliničkom centru Univerziteta u Sarajevu. Ljubav prema dečjoj hirurgiji nasledio je od oca, profesora dr Ivana Kafke, osnivača dečje hirurgije u Sarajevu i Bosni i Hercegovini. Specijalizirao je dečju hirurgiju na Klinici za dečju hirurgiju u Sarajevu. Specijalistički ispit iz Dečje hirurgije položio je 3. februara 1992. godine. Kao specijalista dečje hirurgije radio je sve do 2. januara 1994. godine na Klinici za dečju hirurgiju u Sarajevu kada je, pošto se izjašnjavao kao Srbin, zajedno sa grupom lekara i medicinskih sestara bio je uhapšen i zarobljen u kasarni „Viktor Bubanj”. Po izlasku iz zarobljeništva, zaposlio se kao specijalista dečje hirurgije, na neodređeno vreme, u Kliničkom centru Istočno Sarajevo – bolnica Kasindo. U Kasindolu je radio od 1. jula 1994. godine do 22. jula 1996. godine. Iz Kasindola prelazi u Beograd gde se zapošljava, na neodređeno vreme, u Institutu „Dr Vukan Čupić”. Kao specijalista dečje hirurgije radio je u Institutu od 23. jula 1996. godine do 20. novembra 2011. godine, a potom je otišao u Banjaluku i zaposlio se u Kliničkom centru Banjaluka na neodređeno vreme. U Banjaluci je radio sve do 31. decembra 2012. godine, kada prelazi u Novi Sad. Od 1. januara 2013. godine započinje da radi u Institutu za zdravstvenu zaštitu dece i omladine Vojvodine na radnom mestu lekara specijaliste dečje hirurgije. U Institutu za

zdravstvenu zaštitu dece i omladine postaje 4. januara 2014. godine šef Kabineta za endoskopsku dijagnostiku i terapiju u Odeljenju operacionih sala i endoskopske dijagnostike i terapije Poliklinike za dečju hirurgiju. Od prvog marta 2016. godine postavljen je za načelnika Odeljenja dnevnih bolnica u Službi za prijem i zbrinjavanje bolesnika Poliklinike Klinike za dečju hirurgiju. Šef odseka dnevne bolnice u Stacionaru Klinike za dečju hirurgiju postao je 1. januara 2019. godine i tu je dužnost vršio sve do svoje prerane smrti.

Zvanje primarijusa dodelilo mu je Ministarstvo zdravlja Republike Srbije 22. septembra 2011. godine.

Za vreme dok je bio zaposlen u Institutu za majku i dete u Beogradu pomagao je brojnim roditeljima iz BiH koji su tražili pomoć za svoju decu, a kao konsultant u bolnici u Kasindolu pomagao je i deci iz Sarajeva. Kao gostujući lekar dolazio je punih 25 godina u Bolnicu „Srbija” u Istočnom Sarajevu, gde je obavljao preglede, a i operisao više od 1.000 pacijenata.

Doktor Kafka bio je član Srpskog lekarskog društva, Lekarskog društva BiH, Sekcije za dečju hirurgiju, Udruženja pedijatrijskih hematooonkologa Srbije, Udruženja endoskopskih hirurga Srbije, EUPSA (*European Pediatric Surgical Association*) i APSA (*American Pediatric Surgical Association*). Govorio je engleski.

Za vreme svog dugogodišnjeg rada držao je predavanja o hirurgiji jednaka u dečjem uzrastu. Napisao je poglavlje *Bol u truhu i povraćanje* u Priručniku za lekare zdravstvene zaštite *Urgentna medicina u vanbolničkim uslovima*, 2001. godine.

Primarijus dr Dejan Kafka bio je čestit čovek, bio je vredan i radan, i nikad se nije žalio na teškoće koje



mu je vreme nametnulo, kao i na poteškoće koje svi neminovno imaju. Imao je veliko znanje iz dečje hirurgije i hirurško iskustvo s kojima je ozbiljno pristupao svakom poslovnom zadatku. Bio je posvećen svakom pacijentu ponaosob. Mali pacijenti su ga voleli, a njihovi roditelji poštovali. Pamtiće ga po prijatnom i strpljivom nastupu, kao i uvek lepim i umirujućim rečima. Mladim kolegama bio je oslonac u radu i razmišljanju, a starijim kolegama visokopro-

fesionalan sagovornik. Bila je privilegija saradivati sa čovekom i lekarom koga su krasile osobine velikog čoveka – i humaniste i stručnjaka.

Primarijus dr Dejan Kafka je preminuo u Novom Sadu i sahranjen je na Uspenskom groblju. Večna mu slava!

*Radmila Gudović  
Vladimir Sakač*



## UPUTSTVO ZA AUTORE

Časopis *Medicinski pregled* objavljuje radove koji prethodno nisu objavljeni niti poslani u drugi časopis. U Časopisu mogu biti objavljeni radovi iz različitih oblasti biomedicine, koji su namenjeni lekarima različitih specijalnosti.

Od 1. januara 2013. godine *Medicinski pregled* je počeo da koristi usluge *e-Ur* – Elektronskog uređivanja časopisa. Svi korisnici sistema – autori, recenzenti i urednici, moraju biti registrovani korisnici sa jednom elektronskom adresom.

Korisnici časopisa treba da se registruju na adresi:  
<http://aseestant.ceon.rs/index.php/medpreg/user/register>  
Prijava rada treba da se učini na adresi:  
<http://aseestant.ceon.rs/index.php/medpreg/>

U postupku prijave neophodno je da se pošalje saglasnost i izjava autora i svih koautora da rad nije delimično ili u celini objavljen ili prihvaćen za štampu u drugom časopisu.

Elektronsko uređivanje časopisa obezbeđuje korišćenje sistema *CrossCheck*, koji prijavljene radove automatski proverava na plagijarizam i autoplagijarizam. Autori ne bi smeli da pošalju isti rad u više časopisa istovremeno. Ukoliko se to desi, glavni urednik časopisa *Medicinski pregled* ima pravo da rad vrati autorima bez prethodnog slanja rada na recenziju; da odbije štampanje rada; da se obrati urednicima drugih časopisa u koje je rad poslat ili da se obrati direktoru ustanove u kojoj su autori rada zaposleni.

Primaju se samo radovi koji su napisani na engleskom jeziku, uz sažetak rada i naslov rada koji treba da budu napisani na engleskom i srpskom jeziku.

Radove koji su pristigli u časopis *Medicinski pregled* pregleda jedan ili više članova Uređivačkog odbora Časopisa. Oni radovi koji su napisani prema pravilima Časopisa šalju se na anonimnu recenziju kod najmanje dva recenzenta, stručnjaka iz odgovarajuće oblasti biomedicine. Načinjene recenzije radova pregleda glavni urednik ili članovi Uređivačkog odbora i one nisu garancija da će rad biti prihvaćen za štampu. Materijal koji je pristigao u časopis ostaje poverljiv dok se rad nalazi na recenziji, a identitet autora i recenzentata su zaštićeni, osim u slučaju ako oni odluče drugačije.

U časopisu *Medicinski pregled* objavljuju se: uvodnici, originalni članci, prethodna ili kratka saopštenja, pregledni članci, stručni članci, prikazi slučajeva, članci iz istorije medicine i drugi članci.

**1. Uvodnici** – do 5 strana. Sadrže mišljenja ili diskusiju o posebno značajnoj temi za Časopis, kao i o podacima koji su štampani u ovom ili nekom drugom časopisu. Obično ih piše jedan autor po pozivu.

**2. Originalni članci** – do 12 strana. Predstavljaju rezultate istraživanja autora rada i njihovo tumačenje. Istraživanje treba da bude obrađeno i izloženo na način da se može ponoviti, a analiza rezultata i zaključci jasni da bi se mogli proveriti.

**3. Pregledni članci** – do 10 strana. Predstavljaju sistematsko, sveobuhvatno i kritičko izlaganje problema na osnovu analiziranih i diskutovanih podataka iz literature, a koji oslikavaju postojeću situaciju u određenom području istraživanja. Literatura koja se koristi u radu mora da sadrži najmanje 5 radova autora članka iz uže naučne oblasti koja je opisana u radu.

**4. Prethodna ili kratka saopštenja** – do 4 strane. Sadrže izuzetno važne naučne rezultate koje bi trebalo objaviti u što kraćem vremenu. Ne moraju da sadrže detaljan opis metodologije rada i rezultata, ali moraju da imaju sva poglavlja kao originalni članci u sažetoj formi.

**5. Stručni članci** – do 10 strana. Odnose se na proveru ili prikaz prethodnog istraživanja i predstavljaju koristan izvor za širenje znanja i prilagođavanja originalnog istraživanja potrebama postojeće nauke i prakse.

**6. Prikazi slučajeva** – do 6 strana. Opisuju retke slučajeve iz prakse. Slični su stručnim člancima. U ovim radovima pri-

kazuju se neobičajeni oblici i tokovi oboljenja, neočekivane reakcije na primenjenu terapiju, primene novih dijagnostičkih procedura ili retke i nove bolesti.

**7. Članci iz istorije medicine** – do 10 strana. Ovi članci opisuju događaje iz prošlosti sa ciljem da omoguće očuvanje medicinske i zdravstvene kulture. Imaju karakter stručnih članaka.

**8. Ostali članci** – U časopisu *Medicinski pregled* objavljuju se feljtoni, prikazi knjiga, izvodi iz strane literature, izveštaji sa kongresa i stručnih sastanaka, saopštenja o radu pojedinih zdravstvenih organizacija, podružnica i sekcija, saopštenja Uredništva, pisma Uredništvu, novosti u medicini, pitanja i odgovori, stručne i staleške vesti i članci napisani u znak sećanja (*In memoriam*).

### Priprema rukopisa

Kompletan rukopis, uključujući tekst rada, sve priloge i propratno pismo, treba poslati na elektronsku adresu koja je prethodno navedena.

Propratno pismo:

– mora da sadrži izjavu svih autora da se radi o originalnom radu koji prethodno nije objavljen niti prihvaćen za štampu u drugim časopisima;

– autori svojim potpisom preuzimaju odgovornost da rad ispunjava sve postavljene uslove i da ne postoji sukob interesa i

– autor mora navesti kategoriju članka (originalni rad, pregledni rad, prethodno saopštenje, stručni rad, prikaz slučaja, rad iz istorije medicine, itd.).

### Rukopis

#### Opšta uputstva

Tekst rada treba da bude napisan u programu *Microsoft Word* za *Windows*, na A4 formatu stranice (sve četiri margine 2,5 cm), proreda 1,5 (isto važi i za tabele), fontom *Times New Roman*, veličinom slova 12 pt. Neophodno je koristiti međunarodni sistem mernih jedinica (*SI*), uz izuzetak temperature ( $^{\circ}C$ ) i krvnog pritiska (*mmHg*).

Rukopis treba da sadrži sledeće elemente:

#### 1. Naslovna strana

Naslovna strana treba da sadrži: kratak i sažet naslov rada, bez skraćenica, skraćeni naslov rada (do 40 karaktera), imena i prezimena autora (ne više od 6) i afilijacije svih autora. Na dnu strane treba da piše ime, prezime i titula autora zaduženog za korespondenciju, njena/njegova adresa, elektronska adresa, broj telefona i faksa.

#### 2. Sažetak

Sažetak ne može da sadrži više od 250 reči niti skraćenice. Treba da bude strukturisan, kratak i sažet, sa jasnim pregledom problema istraživanja, ciljevima, metodama, značajnim rezultatima i zaključcima.

Sažetak originalnih i stručnih članaka treba da sadrži uvod (sa ciljevima istraživanja), materijale i metode, rezultate i zaključak.

Sažetak prikaza slučaja treba da sadrži uvod, prikaz slučaja i zaključak.

Sažetak preglednih članaka treba da sadrži Uvod, podnaslove koji odgovaraju istima u tekstu i Zaključak.

Naveći do 10 ključnih reči ispod sažetka. One su pomoć prilikom indeksiranja, ali autorove ključne reči mogu biti izmenjene u skladu sa odgovarajućim deskriptorima, odnosno terminima iz *Medical Subject Headings, MeSH*.

Sažetak treba da bude napisan na srpskom i engleskom jeziku. Sažetak na srpskom jeziku trebalo bi da predstavlja prevod sažetka na engleskom, što podrazumeva da sadrži jednake delove.

#### 3. Tekst članka

Originalni rad treba da sadrži sledeća poglavlja: Uvod (sa jasno definisanim ciljevima istraživanja), Materijal i metode, Rezultati, Diskusija, Zaključak, spisak skraćenica (ukoliko su

korišćene u tekstu). Nije neophodno da se u posebnom poglavlju rada napiše zahvalnica onima koji su pomogli da se istraživanje uradi, kao i da se rad napiše.

Prikaz slučaja treba da sadrži sledeća poglavlja: Uvod (sa jasno definisanim ciljevima), Prikaz slučaja, Diskusija i Zaključak.

#### Uvod

U poglavlju Uvod potrebno je jasno definisati predmet istraživanja (prirodu i značaj istraživanja), navesti značajne navode literature i jasno definisati ciljeve istraživanja i hipoteze.

#### Materijal i metode

Materijal i metode rada treba da sadrže podatke o vrsti studije (prospektivna/retrospektivna, uslove za uključivanje i ograničenja studije, trajanje istraživanja, demografske podatke, period praćenja). Detaljno treba opisati statističke metode da bi čitaoci rada mogli da provere iznesene rezultate.

#### Rezultati

Rezultati predstavljaju detaljan prikaz podataka koji su dobijeni istraživanjem. Sve tabele, grafikoni, sheme i slike moraju biti citirani u tekstu rada i označeni brojevima po redosledu njihovog navođenja.

#### Diskusija

Diskusija treba da bude koncizna, jasna i da predstavlja tumačenje i poređenje rezultata studije sa relevantnim studijama koje su objavljene u domaćoj i međunarodnoj literaturi. U poglavlju Diskusija potrebno je naglasiti da li su postavljene hipoteze potvrđene ili nisu, kao i istaknuti značaj i nedostatke istraživanja.

#### Zaključak

Zaključci moraju proisteći isključivo iz rezultata istraživanja rada; treba izbegavati uopštene i nepotrebne zaključke. Zaključci koji su navedeni u tekstu rada moraju biti u saglasnosti sa zaključcima iz Sažetka.

#### 4. Literatura

Potrebno je da se literatura numeriče arapskim brojevima redosledom kojim je u tekstu navedena u parentezama; izbegavati nepotrebno velik broj navoda literature. Časopise bi trebalo navoditi u skraćenom obliku koji se koristi u *Index Medicus* (<http://www.nlm.nih.gov/tsd/serials/lji.html>). Pri citiranju literature koristiti Vankuverski sistem. Potrebno je da se navedu svi autori rada, osim ukoliko je broj autora veći od šest. U tom slučaju napisati imena prvih šest autora praćeno sa *et al.*

Primeri pravilnog navođenja literature nalaze se u nastavku.

#### Radovi u časopisima

\* Standardni rad

Ginsberg JS, Bates SM. Management of venous thromboembolism during pregnancy. *J Thromb Haemost* 2003;1:1435-42.

\* Organizacija kao autor

Diabetes Prevention Program Research Group. Hypertension, insulin, and proinsulin in participants with impaired glucose tolerance. *Hypertension* 2002;40(5):679-86.

\* Bez autora

21st century heart solution may have a sting in the tail. *BMJ*. 2002;325(7357):184.

\* Volumen sa suplementom

Magni F, Rossoni G, Berti F. BN-52021 protects guinea pig from heart anaphylaxis. *Pharmacol Res Commun* 1988;20 Suppl 5:75-8.

\* Sveska sa suplementom

Gardos G, Cole JO, Haskell D, Marby D, Pame SS, Moore P. The natural history of tardive dyskinesia. *J Clin Psychopharmacol* 1988;8(4 Suppl):31S-37S.

\* Sažetak u časopisu

Fuhrman SA, Joiner KA. Binding of the third component of complement C3 by *Toxoplasma gondii* [abstract]. *Clin Res* 1987;35:475A.

#### Knjige i druge monografije

\* Jedan ili više autora

Murray PR, Rosenthal KS, Kobayashi GS, Pfaller MA. *Medical microbiology*. 4th ed. St. Louis: Mosby; 2002.

\* Urednik (urednici) kao autor (autori)

Danset J, Colombani J, eds. *Histocompatibility testing* 1972. Copenhagen: Munksgaard, 1973:12-8.

\* Poglavlje u knjizi

Weinstein L, Shwartz MN. Pathologic properties of invading microorganisms. In: Soderman WA Jr, Soderman WA, eds. *Pathologic physiology: mechanisms of disease*. Philadelphia: Saunders; 1974. p. 457-72.

\* Zbornik radova sa kongresa

Christensen S, Oppacher F. An analysis of Koza's computational effort statistic for genetic programming. In: Foster JA, Lutton E, Miller J, Ryan C, Tettamanzi AG, editors. *Genetic programming. EuroGP 2002: Proceedings of the 5th European Conference on Genetic Programming*; 2002 Apr 3-5; Kinsdale, Ireland. Berlin: Springer; 2002. p. 182-91.

\* Disertacija

Borkowski MM. *Infant sleep and feeding: a telephone survey of Hispanic Americans* [dissertation]. Mount Pleasant (MI): Central Michigan University; 2002.

#### Elektronski materijal

\* Članak iz časopisa u elektronskom formatu

Aboud S. Quality improvement initiative in nursing homes: the ANA acts in an advisory role. *Am J Nurs* [Internet]. 2002 Jun [cited 2002 Aug 12];102(6):[about 1 p.]. Available from: <http://www.nursingworld.org/AJN/2002/june/Wawatch.htmArticle>

\* Monografija u elektronskom formatu

CDI, clinical dermatology illustrated [monograph on CD-ROM]. Reeves JRT, Maibach H. CMEA Multimedia Group, producers. 2nd ed. Version 2.0. San Diego:CMEA;1995.

\* Kompjuterska datoteka

Hemodynamics III: the ups and downs of hemodynamics [computer program]. Version 2.2. Orlando (FL): Computerized Educational Systems; 1993.

#### 5. Prilozi (tabele, grafikoni, sheme i slike)

BROJ PRILOGA NE SME BITI VEĆI OD ŠEST!

Tabele, grafikoni, sheme i slike se postavljaju kao posebni dokumenti.

– Tabele i grafikone bi trebalo pripremiti u formatu koji je kompatibilan programu u kojem je napisan tekst rada. Slike bi trebalo poslati u jednom od sledećih oblika: *JPG, GIF, TIFF, EPS*.

– Svaki prilog mora biti obeležen arapskim brojem prema redosledu po kojem se navodi u tekstu rada.

– Naslovi, tekst u tabelama, grafikonima, shemama i legende slika bi trebalo da budu napisani na srpskom i engleskom jeziku.

– Nestandardne priloge označiti u fusnoti uz korišćenje sledećih simbola: \*, †, ‡, §, ||, ¶, \*\*, † †, ‡ ‡.

– U legendi slika trebalo bi napisati korišćeno uveličanje okulara i objektivna mikroskopa. Svaka fotografija treba da ima vidljivu skalu.

– Ako su tabele, grafikoni, sheme ili slike već objavljene, navesti originalni izvor i priložiti pisano odobrenje autora za njihovo korišćenje.

– Svi prilozi će biti štampani kao crno-bele slike. Ukoliko autori žele da se prilozi štampaju u boji, obavezno treba da plate dodatne troškove.

#### 6. Dodatne obaveze

AUTORI I SVI KOAUTORI RADA OBAVEZNO TREBA DA PLATE GODIŠNJU PRETPLATU ZA ČASOPIS *MEDICINSKI PREGLED*. U PROTIVNOM, RAD NEĆE BITI ŠTAMPAN U ČASOPISU.

## INFORMATION FOR AUTHORS

**Medical Review** publishes papers (previously neither published in nor submitted to any other journals) from various fields of biomedicine intended for broad circles of doctors.

Since January 1<sup>st</sup>, 2013 the Medical Review has been using the service e-Ur: Electronic Journal Editing. All users of the Registration system, i.e. authors, reviewers, and editors have to be registered users with only one e-mail address. Registration should be made on the web address:

<http://aseestant.ceon.rs/index.php/medpreg/user/register>.

Manuscript submission should be made on the web address:

<http://aseestant.ceon.rs/index.php/medpreg/>

A SUPPLEMENTARY FILE, WITH THE STATEMENT THAT THE PAPER HAS NOT BEEN SUBMITTED OR ACCEPTED FOR PUBLICATION ELSEWHERE AND A CONSENT SIGNED BY ALL AUTHORS, HAVE TO BE ENCLOSED WITH THE MANUSCRIPT.

Authors may not send the same manuscript to more than one journal concurrently. If this occurs, the Editor may return the paper without reviewing it, reject the paper, contact the Editor of the other journal(s) in question and/or contact the author's employers.

Papers should be written in English language, with an abstract and title page in English, as well as in Serbian language.

All papers submitted to **Medical Review** are seen by one or more members of the Editorial Board. Suitable articles are sent to at least two experts to be reviewed, their reports are returned to the assigned member of the Editorial Board and the Editor. Revision of an article gives no guarantee of acceptance and in some cases revised articles are rejected if the improvements are not sufficient or new issues have arisen. Material submitted to *the Journal* remains confidential while being reviewed and peer-reviewers' identities are protected unless they elect to lose anonymity.

**Medical Review** publishes the following types of articles: editorials, original studies, preliminary reports, review articles, professional articles, case reports, articles from history of medicine and other types of publications.

**1. Editorials** – up to 5 pages – convey opinions or discussions on a subject relevant for the Journal. Editorials are commonly written by one author by invitation.

**2. Original studies** – up to 12 pages – present the authors' own investigations and their interpretations. They should contain data which could be the basis to check the obtained results and reproduce the investigative procedure.

**3. Review articles** – up to 10 pages – provide a condensed, comprehensive and critical review of a problem on the basis of the published material being analyzed and discussed, reflecting the current situation in one area of research. Papers of this type will be accepted for publication provided that the authors confirm their expertise in the relevant area by citing at least 5 self-citations.

**4. Preliminary reports** – up to 4 pages – contain scientific results of significant importance requiring urgent publishing; however, it need not provide detailed description for repeating the obtained results. It presents new scientific data without a detailed explanation of methods and results. It contains all parts of an original study in an abridged form.

**5. Professional articles** – up to 10 pages – examine or reproduce previous investigation and represent a valuable source of knowledge and adaption of original investigations for the needs of current science and practice.

**6. Case reports** – up to 6 pages – deal with rare casuistry from practice important for doctors in direct charge of patients and are similar to professional articles. They emphasize unusual characteristics and course of a disease, unexpected reactions to a therapy, application of new diagnostic procedures and describe a rare or new disease.

**7. History of medicine** – up to 10 pages – deals with history with the aim of providing continuity of medical and health care culture. They have the character of professional articles.

**8. Other types of publications** – The journal also publishes feuilletons, book reviews, extracts from foreign literature, reports from congresses and professional meetings, communications on activities of certain medical institutions, branches and sections, announcements of the Editorial Board, letters to the Editorial Board, novelties in medicine, questions and answers, professional and vocational news and In memoriam.

### Preparation of the manuscript

The complete manuscript, including the text, all supplementary material and covering letter, is to be sent to the web address above.

### The covering letter:

– It must contain the proof given by the author that the paper represents an original work that it has neither been previously published in other journals nor is under consideration to be published in other journals.

– It must confirm that all the authors meet criteria set for the authorship of the paper, that they agree completely with the text and that there is no conflict of interest.

– It must state the type of the paper submitted (an original study, a review article, a preliminary report, a professional article, a case report, history of medicine).

### The manuscript:

#### General instructions.

Use Microsoft Word for Windows to type the text. The text must be typed in font *Times New Roman*, page format A4, space 1.5 (for tables as well), margins set to 2.5 cm and font size 12pt. All measurements should be reported in the metric system of the International System of Units – SI. Temperature should be expressed in Celsius degrees (°C) and pressure in mmHg.

The manuscript should contain the following elements:

#### 1. The title page.

The title page should contain a concise and clear title of the paper, without abbreviations, then a short title (up to 40 characters), full names and surnames of the authors (not more than 6) indexed by numbers corresponding to those given in the heading along with the full name and place of the institutions they work for. Contact information including the academic degree(s), full address, e-mail and number of phone or fax of the corresponding author (the author responsible for correspondence) are to be given at the bottom of this page.

#### 2. Summary.

The summary should contain up to 250 words, without abbreviations, with the precise review of problems, objectives, methods, important results and conclusions. It should be structured into the paragraphs as follows:

– Original and professional papers should have the introduction (with the objective of the paper), materials and methods, results and conclusion

– Case reports should have the introduction, case report and conclusion

– Review papers should have the introduction, subtitles corresponding to those in the paper and conclusion.

The authors should provide up to 10 keywords below the summary. These keywords will assist indexers in cross-indexing the article and will be published with the summary, but the authors' keywords could be changed in accordance with the list of Medical Subject Headings, MeSH of the American National Medical Library.

The summary should be written in both languages, English as well as Serbian. The summary in Serbian language should be the translation of the summary in English; therefore, it has to contain the same paragraphs.

### 3. The text of the paper.

The text of original studies must contain the following: introduction (with the clearly defined objective of the study), materials and methods, results, discussion, conclusion, list of abbreviations (if used in the text) and not necessarily, the acknowledgment mentioning those who have helped in the investigation and preparation of the paper.

The text of a case report should contain the following: introduction (with clearly defined objective of the study), case report, discussion and conclusion.

**Introduction** contains clearly defined problem dealt with in the study (its nature and importance), with the relevant references and clearly defined objective of the investigation and hypothesis.

**Materials and methods** should contain data on design of the study (prospective/retrospective, eligibility and exclusion criteria, duration, demographic data, follow-up period). Statistical methods applied should be clear and described in details.

**Results** give a detailed review of data obtained during the study. All tables, graphs, schemes and figures must be cited in the text and numbered consecutively in the order of their first citation in the text.

**Discussion** should be concise and clear, interpreting the basic findings of the study in comparison with the results of relevant studies published in international and national literature. It should be stated whether the hypothesis has been confirmed or denied. Merits and demerits of the study should be mentioned.

**Conclusion** must deny or confirm the attitude towards the Obased solely on the author's own results, corroborating them. Avoid generalized and unnecessary conclusions. Conclusions in the text must be in accordance with those given in the summary.

**4. References** are to be given in the text under Arabic numerals in parentheses consecutively in the order of their first citation. Avoid a large number of citations in the text. The title of journals should be abbreviated according to the style used in Index Medicus (<http://www.nlm.nih.gov/tsd/serials/lji.html>). Apply Vancouver Group's Criteria, which define the order of data and punctuation marks separating them. Examples of correct forms of references are given below. List all authors, but if the number exceeds six, give the names of six authors followed by 'et al'.

#### Articles in journals

##### *\* A standard article*

Ginsberg JS, Bates SM. Management of venous thromboembolism during pregnancy. *J Thromb Haemost* 2003;1:1435-42.

##### *\* An organization as the author*

Diabetes Prevention Program Research Group. Hypertension, insulin, and proinsulin in participants with impaired glucose tolerance. *Hypertension* 2002;40(5):679-86.

##### *\* No author given*

21st century heart solution may have a sting in the tail. *BMJ*. 2002;325(7357):184.

##### *\* A volume with supplement*

Magni F, Rossoni G, Berti F. BN-52021 protects guinea pig from heart anaphylaxis. *Pharmacol Res Commun* 1988;20 Suppl 5:75-8.

##### *\* An issue with supplement*

Gardos G, Cole JO, Haskell D, Marby D, Pame SS, Moore P. The natural history of tardive dyskinesia. *J Clin Psychopharmacol* 1988;8(4 Suppl):31S-37S.

##### *\* A summary in a journal*

Fuhrman SA, Joiner KA. Binding of the third component of complement C3 by *Toxoplasma gondii* [abstract]. *Clin Res* 1987;35:475A.

#### Books and other monographs

##### *\* One or more authors*

Murray PR, Rosenthal KS, Kobayashi GS, Pfaller MA. *Medical microbiology*. 4th ed. St. Louis: Mosby; 2002.

##### *\* Editor(s) as author(s)*

Danset J, Colombani J, eds. *Histocompatibility testing 1972*. Copenhagen: Munksgaard, 1973:12-8.

##### *\* A chapter in a book*

Weinstein L, Shwartz MN. Pathologic properties of invading microorganisms. In: Soderman WA Jr, Soderman WA, eds. *Pathologic physiology: mechanisms of disease*. Philadelphia: Saunders; 1974. p. 457-72.

##### *\* A conference paper*

Christensen S, Oppacher F. An analysis of Koza's computational effort statistic for genetic programming. In: Foster JA, Lutton E, Miller J, Ryan C, Tettamanzi AG, editors. *Genetic programming. EuroGP 2002: Proceedings of the 5th European Conference on Genetic Programming*; 2002 Apr 3-5; Kinsdale, Ireland. Berlin: Springer; 2002. p. 182-91.

##### *\* A dissertation and theses*

Borkowski MM. *Infant sleep and feeding: a telephone survey of Hispanic Americans [dissertation]*. Mount Pleasant (MI): Central Michigan University; 2002.

#### Electronic material

##### *\* A journal article in electronic format*

Abood S. Quality improvement initiative in nursing homes: the ANA acts in an advisory role. *Am J Nurs* [Internet]. 2002 Jun [cited 2002 Aug 12];102(6):[about 1 p.]. Available from: <http://www.nursingworld.org/AJN/2002/june/Wawatch.htmArticle>

##### *\* Monographs in electronic format*

CDI, clinical dermatology illustrated [monograph on CD-ROM]. Reeves JRT, Maibach H. CMEA Multimedia Group, producers. 2nd ed. Version 2.0. San Diego:CMEA;1995.

##### *\* A computer file*

Hemodynamics III: the ups and downs of hemodynamics [computer program]. Version 2.2. Orlando (FL): Computerized Educational Systems; 1993.

### 5. Attachments (tables, graphs, schemes and photographs).

THE MAXIMUM NUMBER OF ATTACHMENTS ALLOWED IS SIX!

– Tables, graphs, schemes and photographs are to be submitted as separate documents, on separate pages.

– Tables and graphs are to be prepared in the format compatible with Microsoft Word for Windows programme. Photographs are to be prepared in JPG, GIF, TIFF, EPS or similar format.

– Each attachment must be numbered by Arabic numerals consecutively in the order of their appearance in the text

– The title, text in tables, graphs, schemes and legends must be given in both Serbian and English languages.

– Explain all non-standard abbreviations in footnotes using the following symbols \*, †, ‡, §, ||, ¶, \*\*, † †, ‡ ‡.

– State the type of color used and microscope magnification in the legends of photomicrographs. Photomicrographs should have internal scale markers.

– If a table, graph, scheme or figure has been previously published, acknowledge the original source and submit written permission from the copyright holder to reproduce it.

– All attachments will be printed in black and white. If the authors wish to have the attachments in color, they will have to pay additional cost.

### 6. Additional requirements

SHOULD THE AUTHOR AND ALL CO-AUTHORS FAIL TO PAY THE SUBSCRIPTION FOR MEDICAL REVIEW, THEIR PAPER WILL NOT BE PUBLISHED.