

University of Novi Sad, Faculty of Medicine Novi Sad¹
 University Clinical Center of Vojvodina, Novi Sad
 Clinic of Gynecology and Obstetrics²

Case report
Prikaz slučaja
 UDK 616.98:578.834]-06:616.151.5 055.26
<https://doi.org/10.2298/MPNS2302052K>

DISSEMINATED INTRAVASCULAR COAGULATION IN A PREGNANT WOMAN WITH CORONAVIRUS DISEASE 2019 INFECTION – A CASE REPORT

DISEMINOVANA INTRAVASKULARNA KOAGULACIJA KOD TRUDNICE OBOLELE OD KOVID 19 INFEKCIJE – PRIKAZ SLUČAJA

Anita KRSMAN^{1,2}, Marija KUPREŠANIN², Branislava BATURAN^{1,2}, Sanja BULATOVIĆ², Đorđe PETROVIĆ^{1,2} and Đorđe ILIĆ^{1,2}

Summary

Introduction. Coronavirus infection may cause numerous complications in pregnant women, as well as an increased risk for the fetus. Disseminated intravascular coagulation and other coagulopathies can be caused by coronavirus disease 2019 infection.

Case Report. A 22-year-old primigravida presented with a nine-day history of dry cough, myalgia, nausea and fever. A nasopharyngeal swab for severe acute respiratory syndrome coronavirus 2 infection was positive. The patient's condition rapidly deteriorated, resulting in severe liver damage and disseminated intravascular coagulation. Fetal cardiotocography showed a silent curve with late decelerations, while the umbilical artery Doppler showed end-diastolic block, indicating a fetal distress. Emergency cesarean section was performed at 28+5 weeks of gestation. After the cesarean section, the patient was treated with blood derivatives, thromboprophylaxis and supportive therapy and recovered quickly. Unfortunately, the premature infant died three hours after birth.

Conclusion. It is very important to simultaneously monitor the parameters of the mother's coagulation system, as well as the condition of the fetus, because there is a possibility of developing coagulopathies, including disseminated intravascular coagulation.

Key words: Disseminated Intravascular Coagulation; COVID-19; Pregnant Women; Pregnancy; Treatment Outcome; Pregnancy Outcome; Blood Coagulation Factors; Fetus

Sažetak

Uvod. Infekcija virusom korone može dovesti do opasnih komplikacija kod trudnica, kao i povećanog rizika za fetus. Diseminovana intravaskularna koagulacija, kao i druge koagulopatije, mogu biti uzrokovane COVID-19 infekcijom. **Prikaz slučaja.** Dvadesetdvogodišnja trudnica (prvorotka) javlja se devet dana nakon početka simptoma u vidu kašlja, bolova u mišićima, mučnine i povišene telesne temperature. Nazofaringealni bris na teški akutni respiratorni sindrom korona virusa 2 bio je pozitivan. Stanje pacijentkinje se promptno pogoršalo u pravcu razvoja lezije jetre i diseminovane intravaskularne koagulacije. Kardiotokografski zapis pokazao je silentnu krivu sa kasnim deceleracijama, dok je dopler umbilikalne arterije pokazao enddiastolni blok, što je ukazivalo na fetalni distress. Trudnoća je završena hitnim carskim rezom u 28+5 gestacijskoj nedelji. Postoperativno pacijentkinja je lečena krvnim derivatima, tromboprofilaksom i suportivnom terapijom što je dovelo do brzog oporavka pacijentkinje, dok je kod nedonoščeta zabeležen smrtni ishod. **Zaključak.** Veoma je važno istovremeno pratiti parametre koagulacionog sistema majke, kao i stanje fetusa jer postoji mogućnost razvoja koagulopatija, uključujući diseminovanu intravaskularnu koagulaciju.

KLjučne reči: diseminovana intravaskularna koagulacija; COVID-19; trudnica; trudnoća; ishod lečenja; ishod trudnoće; faktori koagulacije krvi; fetus

Introduction

Caused by a novel type of virus, severe acute respiratory syndrome coronavirus 2 (SARS-CoV-2), coronavirus disease 2019 (COVID-19) has exposed vulnerable populations and healthcare systems to a global public health crisis. Pregnant women are at a higher risk of morbidity and even mortality due to the susceptibility to pathogens and particularly immunologic status [1]. Pregnant women with COVID 19 infection are at an increased risk of adverse maternal and neonatal outcomes. Premature rupture of membranes, preterm labor, fetal growth restriction, intrauterine fetal demise and neonatal death are more frequently observed in pregnant patients with SARS-

CoV-2 infection [2]. Although most pregnant women infected with COVID-19 have good outcomes, a recent systematic analysis showed that up to 3% of pregnancies were associated with severe maternal morbidity [3]. High mortality and its relationship with thromboembolic diseases in COVID-19 have attracted increased attention [4, 5]. The COVID-19 appears to cause a hypercoagulable state through unique mechanisms linking thrombosis and inflammation [6]. Disseminated intravascular coagulation (DIC) syndrome has the highest morbidity and mortality rate of all the complex obstetric coagulopathies [7, 8].

We present a rare case of DIC induced by COVID-19 infection. It is unusual that the patient developed a potentially fatal complication in the third trimester

Abbreviations

COVID-19	– coronavirus disease 2019
SARS-CoV-2	– severe acute respiratory syndrome coronavirus 2
DIC	– disseminated intravascular coagulation
APTT	– activated partial thromboplastin time
CPR	– cardiopulmonary resuscitation
ISTH	– International Society on Thrombosis and Haemostasis
HELLP	– hemolysis elevated liver enzymes, and low platelet
TXA	– tranexamic acid

of pregnancy, although she had mild clinical symptoms of COVID-19, absence of inflammatory signs on chest X-ray, and absence of the signs of hemorrhagic syndrome. The purpose of the study was to present our first experience with such a rare pathology and to point to the challenges in diagnosing and treating pregnant women with COVID-19 infection.

Case Report

A 22-year-old primigravida, in the 28th week of gestation, was admitted to the Department of Obstetrics and Perinatology of the Clinical Center of Vojvodina in Novi Sad. She presented with a nine-day history of runny nose, anosmia, dry cough, myalgia, and fever. The nasopharyngeal swab for SARS-CoV-2 infection was positive nine days before admission. Other than that, the course of the pregnancy was uneventful. On admission, physical, ultrasound, laboratory and microbiological examinations were performed. The patient did not receive any dose of the COVID-19 vaccine. On admission, the patient showed cardiovascular and respiratory stability: blood pressure 90/60 mmHg, heart

rate 92 bpm, respiratory rate 17 breaths/minute, body temperature 36.5 °C, oxygen saturation of 99% on ambient air. The initial vaginal examination showed that the vaginal part of the cervix was slightly shortened, directed posteriorly and closed (Bishop Score of 1). The uterine muscle tension was normal, without contractions, and there was no active vaginal bleeding or leakage of amniotic fluid during the examination. The ultrasound examination revealed a vital pregnancy with the fetus in the cephalic presentation. The placenta with calcifications was located on the anterior wall of the uterine cavity without signs of ablation or retroplacental hematoma. The fetal Doppler flow was normal on admission: umbilical artery pulsation index was 1.02, and amniotic fluid index was 12.8 cm. The cardiocography was normal, revealing normal cardiac activity and reactive variability. A chest X-ray was performed and it was normal, without signs of inflammation and pathological changes in the lung parenchyma. The initial laboratory tests showed a high D-dimer, a decreased platelet level, prolonged activated partial thromboplastin time (aPTT), elevated liver enzymes, and normal fibrinogen levels (**Table 1**). The patient was prescribed a prophylactic dose of low-molecular-weight heparin and a prophylactic antibiotic therapy with third-generation cephalosporin, because of symptoms of the upper respiratory tract infection and elevated values of inflammatory parameters. As there was a risk of preterm labor, the patient received corticosteroid therapy (dexamethasone) to aid the fetal lung maturity. However, the control laboratory test showed a disturbingly high concentration of D-dimer, a decreased platelet level, and low fibrinogen levels (**Table 1**). A multidisciplinary team with a hemostatology specialist believed that differential diagnosis

Table 1. Laboratory test results**Tabela 1.** Laboratorijski rezultati

	On admission/ <i>Na prijemu</i>	6h from admission/ <i>6č nakon prijema</i>	12h from admission/ <i>12č nakon prijema</i>
WBC	3.72 x 10 ⁶ /l	3.65 x 10 ⁶ /l	3.16 x 10 ⁶ /l
RBC	4.18 x 10 ¹² /l	3.95 x 10 ¹² /l	3.78 x 10 ¹² /l
HGB	127 g/l	123 g/l	114 g/l
HCT	0.36	0.35	0.31
PLT	98 x 10 ⁹ /l	80 x 10 ⁹ /l	68 x 10 ⁹ /l
PT	0.99	1.09	1.88
APTT	1.30	1.49	1.55
Fibrinogen	3.0 g/l	2.1 g/l	1.0 g/l
D-dimer	46.24 mg/l FEU	67.68 mg/l FEU	102.40 mg/l FEU
AST	95 u/l	/	125 u/l
ALT	37 u/l	/	56.5 u/l
LDH	472 u/l	/	645 u/l
CRP	71.12 mg/l	60.9 mg/l	53.94 mg/l
PCT	0.26 ng/ml	0.33 ng/ml	0.28 ng/ml

Legend: WBC - white blood cells; RBC - red blood cells; HGB - hemoglobin; HCT - hematocrit; PLT - platelet count; PT - prothrombin time; APTT - activated partial thromboplastin time; AST - aspartate aminotransferaze; ALT - alanine aminotransferaze; LDH - lactate dehydrogenase; CRP - C-reactive protein; PCT - procalcitonin

Legenda: WBC – leukociti; RBC – eritrociti; HGB – hemoglobin; HCT – hematokrit; PLT – trombociti; PT – protrombinsko vreme; APTT – aktivirano parcijalno tromboplastinsko vreme; AST – aspartat aminotransferaza; ALT – alanin aminotransferaza; LDH – laktat dehidrogenaza; CRP – C-reaktivni protein; PCT – prokalcitonin

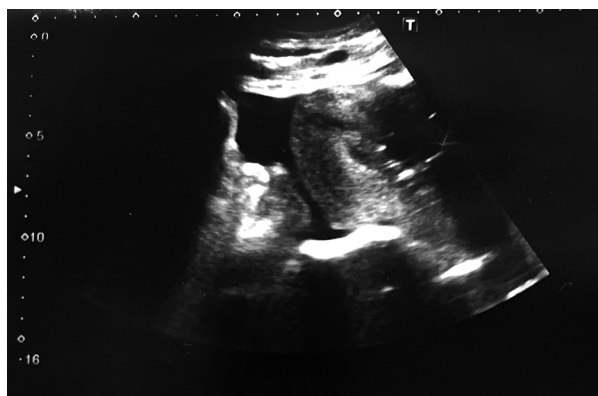


Figure 1. Umbilical artery Doppler (end-diastolic block)
Slika 1. Dopler umbilikalne arterije (end-dijastolni blok)

should include the onset of DIC. In the meantime, the fetal cardiotocography showed a silent curve with late decelerations, and the umbilical artery Doppler ultrasound showed an end-diastolic block (**Figure 1**), suggesting impending fetal distress.

Given the deterioration of the mother's laboratory findings, the development of DIC, and fetal hypoxia, an emergency cesarean section was performed at 28+5 weeks of gestation. The anesthesiologist used general anesthesia because of the coagulation disturbances and emergency of the procedure. During the operation, the patient received 2 units of fresh-frozen plasma. Uncomplicated operation was completed within 40 minutes, and the total blood loss was 300 ml. Pelvic drainage was performed to control possible bleeding into the abdominal cavity in the early postoperative period. The patient received broad-spectrum antibiotic therapy (ceftriaxone, metronidazole). The local hospital guidelines were followed to prevent the spread of COVID-19 [9]. The Apgar score of the newborn at 1 and 5 minutes was 0, and 1 at 10 minutes. Immediately after birth, the baby (960 g/39 cm) was in an extremely poor condition, without heart activity, hypotonic, unresponsive and cyanotic. Following European Resuscitation Council guidelines, cardiopulmonary resuscitation (CPR) was started. After 10 min of CPR, the first fetal heartbeats were obtained. The premature baby was intubated and on mechanical ventilation with all the support measures, but unfortunately with lethal outcome 3 hours after birth.

During the following days of hospitalization, the mother's general condition was stable. She was treated with blood derivatives, thromboprophylaxis, antibiotics, uterotonics, and supportive therapy. Postoperatively, the patient received a total of 3 units of resuspended red cells and 1 unit of fresh frozen plasma. The ultrasound showed a collection of minimal free intraperitoneal fluid (**Figure 2**). Pelvic drainage comprised 10 - 100 mL of serous blood daily and was removed on the fifth postoperative day. The microbiological smear of the uterine cavity taken during cesarean section, and hemoculture and urine culture came back negative. The histopathology examination of the placenta showed small foci of inflammatory

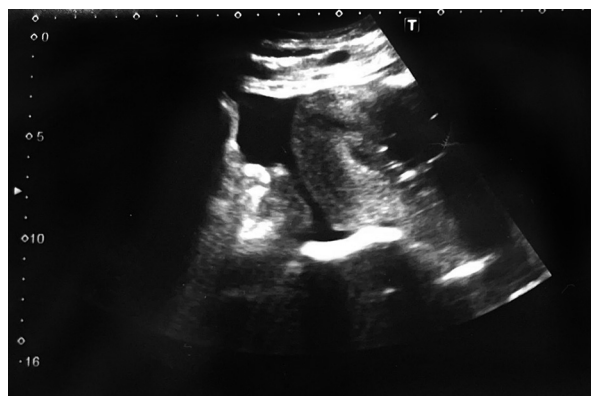

Figure 2. Postoperative ultrasound image of minimal free intraperitoneal fluid collection
Slika 2. Ultrazvučni prikaz kolekcije minimalne slobodne intraperitonealne tečnosti postoperativno

infiltrates composed of neutrophils in the villi of the placenta. Since the patient was recovering rapidly, she was discharged in good general condition on the 10th day of hospitalization.

A written consent to publish this case report was obtained from the patient. The review was approved by the Clinical Center of Vojvodina Ethics Committee.

Discussion

The course of SARS-CoV-2 infection in most pregnant women is usually mildly symptomatic. However, it has been proven that both COVID-19 and pregnancy increase the prothrombotic potential [10]. Even in healthy women, pregnancy triggers many changes in the hemostatic system. The COVID-19 infection appears to cause a hypercoagulable state through unique mechanisms linking thrombosis and inflammation [11]. An inflammatory process of the endothelium damages its cells and disrupts the anticoagulation process. This results with a high level of von Willebrand factor [12]. The interaction between activated response mechanisms, neutrophils, monocytes, cytokines that they release, the coagulation system, and the complement system, triggers a process similar to immune thrombosis resulting in the formation of blood clots in large and small vessels [13]. Several studies describe pregnant patients affected by COVID-19-induced coagulopathies, and very few resulted in adverse outcomes for both the mother and the baby [14–16]. In 2021, Servante et al. presented a literature review on thromboembolic complications in pregnant patients with SARS-CoV-2 infection, which included 1,063 patients. Maternal mortality due to coagulopathies was 0.01%, with two deaths caused by the development of DIC. The condition of 132 (0.12%) patients was serious and required admission to the Intensive Care Unit [17]. In our case, monitoring the laboratory findings over time helped to establish an early diagnosis. Such an approach allows for detecting abnormalities in the

Table 2. Disseminated intravascular coagulation score using the International Society on Thrombosis and Hemostasis
Tabela 2. Skor diseminovane intravaskularne koagulacije (DIK) Međunarodnog društva za trombozu i hemostazu

	185 = 0 point
Platelet count (x10 ⁹ /l) <i>Broj trombocita</i>	100 - 185 = 1 point
	50 - 100 = 2 points
	< 50 = 1 point
	< 0.5 = 0 point
Prothrombin time <i>Protrombinsko vreme</i>	0.5 - 1.0 = 5 points
	1.0 - 1.5 = 12 points
	> 1.5 = 25 points
	< 3.0 = 25 points
Fibrinogen (g/l) <i>Fibrinogen</i>	3.0 - 4.0 = 6 points
	4.0 - 4.5 = 1 point
	> 4.5 = 0 point
Total points/ <i>Ukupno</i>	≥ 26 points = high probability of DIC/ <i>Velika verovatnoća za DIK</i>

coagulation system and planning treatment in advance. A modified DIC risk assessment scale for pregnant women was developed - the International Society on Thrombosis and Haemostasis (ISTH) DIC score (**Table 2**) [18]. A score of > 26 suggests a high probability of DIC. The scale is characterized by a high percentage of sensitivity (81%) and specificity (96%) for the diagnosis of intravascular coagulation during pregnancy [19]. Our patient scored 52, but the scale was used retrospectively. In our opinion, adaptation and use of the scale in daily clinical practice would be helpful. According to the ISTH guidelines, besides routine laboratory analysis, D-dimer levels, platelet count, and prothrombin time should be measured in all individuals having symptoms of COVID-19 [20].

Endothelial damage results in thrombotic microangiopathy, which accompanies other severe pregnancy complications such as hemolysis, elevated liver enzymes and low platelet (HELLP) syndrome, thrombotic thrombocytopenic purpura, pregnancy-related hemolytic-uremic syndrome and systemic lupus erythematosus. Furthermore, abnormalities in laboratory test results in these syndromes make it difficult to make a diagnosis, which is not always possible due to the overlap of symptoms [19]. For example, the atypical presentation of HELLP cannot be ruled out. Therefore, a multidisciplinary team is critical in treating and managing severe COVID-19 during pregnancy. The use of tranexamic acid (TXA), an antifibrinolytic agent, during a pregnancy complicated by intravascular coagulation, is still controversial. It acts by stabilizing clot formation, which is often reduced by systemic fibrinolysis. The WOMAN trial shows that TXA significantly reduces the risk of postpartum bleeding and maternal mortality. However, it must be used with extreme caution. The use of TXA may be indicated in DIC with enhanced fibrinolysis and severe hemorrhage [21]. As there were no signs of a hemorrhagic syndrome, and in consultation with the hemostaseology specialist, a decision was made not to apply TXA. Our patient was also at high risk because of the ges-

tational age. Studies have shown that SARS-CoV-2 infection in the 2nd or 3rd trimester of pregnancy may increase the risk of death due to cardiopulmonary complications [22, 23]. In this case, after giving birth, there was a quick, complete recovery and withdrawal of symptoms. Unfortunately, the neonatal outcome was unfavorable, which can be attributed to extreme prematurity. At this time, there is a lack of evidence on the adverse effects of maternal SARS-CoV-2 infection on the fetus [24], to be limited and associated with some adverse consequences such as stillbirth and miscarriage [25]. It is important that fetuses have poor toleration for acidosis and hypoxemia due to COVID-19 infection, which leads to complications such as preterm labor [26].

Despite all the efforts, data on pregnancy outcomes in women with COVID-19 are limited. It is currently known that pregnant women are a vulnerable population at risk of severe infections. The infected pregnant women need intensive care unit admission five times and mechanical ventilation four times more than non-pregnant women with a similar death rate [27]. The results of a multi-central adjudicated case series performed in Iran demonstrated that out of 9 pregnant women with severe infection, 1 recovered after a long hospitalization, 1 remained ventilator-dependent with severe illness, and 7 died [28]. Several authors researched the effects of the virus on the placenta. The pathohistological findings of the placenta in our case correlate with those in the literature. The placenta's pathological landmarks in most viral infections are lymphoplasmacytic villitis with the corresponding thickening of villi and intervillous hemosiderin deposition [29]. Only two case reports established pathological placental findings during the second-trimester miscarriages in women suffering from COVID-19 infection [30]. A case-report study from China reported placental findings in three patients suffering from COVID-19 [31]. The perivillous fibrin diffusion, presence of thrombi in the fetal vessels and induced vascular malperfusion, maternal vascular malperfusion, decidual arterio-

pathy choriohemangioma, and multi-focal infarctions were described for placenta from mother with SARS-CoV-2 infection [29, 32, 33].

The COVID-19 infection during pregnancy raises major concerns as its numerous aspects are still to be discovered. Firstly, we still do not know all the possible complications and adverse pregnancy outcomes. Secondly, the vertical transmission of the virus from the mother to the child needs further investigation. Thirdly, the treatment of pregnant women infected with the virus is still a matter of debate among experts. They believe that clinical recommendations for treating COVID-19 in pregnancy should be based on findings of the current epidemic, while case reports of rare complications of COVID-19 infection in pregnant women are particularly important [22].

There are some limitations of our report. We did not evaluate the presence of SARS-CoV-2 in amniotic fluid, cord blood, or placental tissue, which could further clarify the possibility of vertical transmission. On the other hand, the complete diagnostic

protocol for the mother, including antinuclear, anticardiolipin and anti-beta-2-glycoprotein antibody tests, which came back negative, can be considered an advantage of our study.

Conclusion

In summary, we described a case of maternal coronavirus disease 2019 infection during the third trimester of pregnancy, which led to liver and coagulation impairment and preterm delivery. We believe that these findings have significant public implications because of the severity of the disease progression, which endangers not one but two patients, and that is why we presented the diagnostic and treatment protocol for such a rare pathology. As there is a possibility of developing a disseminated intravascular complication, a dangerous condition that negatively affects both the maternal and neonatal outcomes, the recommendation is to pay attention to coagulation status in the treatment of pregnant women suffering from coronavirus disease 2019.

References

- Muyayalo KP, Huang DH, Zhao SJ, Xie T, Mor G, Liao AH. COVID-19 and Treg/Th17 imbalance: potential relationship to pregnancy outcomes. *Am J Reprod Immunol*. 2020;84(5):e13304.
- Fan S, Yan S, Liu X, Liu P, Huang L, Wang S. Human coronavirus infections and pregnancy. *Matern Fetal Med*. 2020;3(1):53-65.
- Zaigham M, Andersson O. Maternal and perinatal outcomes with COVID-19: a systematic review of 108 pregnancies. *Acta Obstet Gynecol Scand*. 2020;99(7):823-9.
- Wu Z, McGoogan JM. Characteristics of and important lessons from the coronavirus disease 2019 (COVID-19) outbreak in China: summary of a report of 72 314 cases from the Chinese Center for Disease Control and Prevention. *JAMA*. 2020;323(13):1239-42.
- Levi M, Thachil J, Iba T, Levy JH. Coagulation abnormalities and thrombosis in patients with COVID-19. *Lancet Haematol*. 2020;7(6):e438-40.
- Bourgonje AR, Abdulle AE, Timens W, Hillebrands JL, Navis GJ, Gordijn SJ, et al. Angiotensin-converting enzyme 2 (ACE2), SARS-CoV-2 and the pathophysiology of coronavirus disease 2019 (COVID-19). *J Pathol*. 2020;251(3):228-48.
- Levi M. Disseminated intravascular coagulation (DIC) in pregnancy and the peri-partum period. *Thromb Res*. 2009;123(Suppl 2):S63-4.
- Lester EP, Roth DG. Disseminated intravascular coagulation in pregnancy. *J Reprod Med*. 1977;19(4):223-32.
- Royal College of Obstetrics and Gynaecologists. Coronavirus (COVID-19) infection in pregnancy: information for healthcare professionals. Version 7 [Internet] 2020 [cited 2020 May 2]. Available from: <https://www.rcog.org.uk/globalassets/documents/guidelines/2020-04-09-coronavirus-covid-19-infection-in-pregnancy.pdf>
- Windyga J. COVID-19 a zaburzenia hemostazy. *Med Prakt*. 2020;(7-8):59-68.
- Brenner B. Haemostatic changes in pregnancy. *Thromb Res*. 2004;114(5-6):409-14.
- Ward SE, Curley GF, Lavin M, Fogarty H, Karampini E, McEvoy NL, et al. Von Willebrand factor propeptide in severe coronavirus disease 2019 (COVID-19): evidence of acute and sustained endothelial cell activation. *Br J Haematol*. 2021;192(4):714-9.
- Verdecchia P, Cavallini C, Spanevello A, Angeli F. The pivotal link between ACE2 deficiency and SARS-CoV-2 infection. *Eur J Intern Med*. 2020;76:14-20.
- Skalska-Świstek M, Huras H, Jaworowski AP, Świstek R, Kołak M. COVID-19 infection complicated by disseminated intravascular coagulation during pregnancy: two cases report. *Diagnostics (Basel)*. 2022;12(3):655.
- Vlachodimitropoulou Koumoutsea E, Vivanti AJ, Shehata N, Benachi A, Le Gouez A, Desconclois C, et al. COVID-19 and acute coagulopathy in pregnancy. *J Thromb Haemost*. 2020;18(7):1648-52.
- Mongula JE, Frenken MWE, van Lijnschoten G, Arents NLA, de Wit-Zuurendonk LD, Schimmel-de Kok APA, et al. COVID-19 during pregnancy: non-reassuring fetal heart rate, placental pathology and coagulopathy. *Ultrasound Obstet Gynecol*. 2020;56(5):773-6.
- Servante J, Swallow G, Thornton JG, Myers B, Munireddy S, Malinowski AK, et al. Haemostatic and thrombo-embolic complications in pregnant women with COVID-19: a systematic review and critical analysis. *BMC Pregnancy Childbirth*. 2021;21(1):108.
- Erez O, Novack L, Beer-Weisel R, Dukler D, Press F, Zlotnik A, et al. DIC score in pregnant women - a population-based modification of the International Society on Thrombosis and Hemostasis score. *PLoS One*. 2014;9(4):e93240.
- Sibai BM. Imitators of severe preeclampsia. *Obstet Gynecol*. 2007;109(4):956-66.
- Schulman S, Sholzberg M, Spyropoulos AC, et al. ISTH guidelines for antithrombotic treatment in COVID-19. *J Thromb Haemost*. 2022;20(10):2214-25..
- Liang H, Acharya G. Novel corona virus disease (COVID-19) in pregnancy: what clinical recommendations to follow? *Acta Obstet Gynecol Scand*. 2020;99(4):439-42.
- Hantoushzadeh S, Shamshirsaz AA, Aleyasin A, Seferovic MD, Aski SK, Arian SE, et al. Maternal death due to COVID-19. *Am J Obstet Gynecol*. 2020;223(1):109.e1-16.

23. Zhao X, Jiang Y, Zhao Y, Xi H, Liu C, Qu F, et al. Analysis of the susceptibility to COVID-19 in pregnancy and recommendations on potential drug screening. *Eur J Clin Microbiol Infect Dis*. 2020;39(7):1209-20.

24. Omo-Aghoja L. Maternal and fetal acid-base chemistry: a major determinant of perinatal outcome. *Ann Med Health Sci Res*. 2014;4(1):8-17.

25. Collin J, Byström E, Carnahan A, Ahrne M. Public Health Agency of Sweden's Brief Report: pregnant and post-partum women with SARS-CoV-2 infection in intensive care in Sweden. *Acta Obstet Gynecol Scand*. 2020;99(7):819-22.

26. Karimi-Zarchi M, Neamatzadeh H, Dastgheib SA, Ab-basi H, Mirjalili SR, Behforouz A, et al. Vertical transmission of coronavirus disease 19 (COVID-19) from infected pregnant mothers to neonates: a review. *Fetal Pediatr Pathol*. 2020;39(3):246-50.

27. Alfaraj SH, Al-Tawfiq JA, Memish ZA. Middle East Respiratory Syndrome Coronavirus (MERS-CoV) infection during
Rad je primljen 13. IX 2022.

Recenziran 17. IV 2023.

Prihvaćen za štampu 18. IV 2023.

BIBLID.0025-8105:(2023):LXXVI:1-2:52-57.

pregnancy: report of two cases and review of the literature. *J Microbiol Immunol Infect*. 2019;52(3):501-3.

28. Shanes ED, Mithal LB, Otero S, Azad HA, Miller ES, Goldstein JA. Placental pathology in COVID-19. *Am J Clin Pathol*. 2020;154(1):23-32.

29. Zhang C, Shi L, Wang FS. Liver injury in COVID-19: management and challenges. *Lancet Gastroenterol Hepatol*. 2020;5(5): 428-30.

30. Garcia AG, Fonseca EF, Marques RL, Lobato YY. Placental morphology in cytomegalovirus infection. *Placenta*. 1989; 10(1):1-18.

31. Hosier H, Farhadian SF, Morotti RA, Deshmukh U, Luculligan A, Campbell KH, et al. SARS-CoV-2 infection of the placenta. *J Clin Invest*. 2020;130(9):4947-53.

32. Mulvey JJ, Magro CM, Ma LX, Nuovo GJ, Baergen RN. Analysis of complement deposition and viral RNA in placentas of COVID-19 patients. *Ann Diagn Pathol*. 2020;46:151530.