

University Clinical Center of Vojvodina, Department of Urology, Novi Sad¹
 University of Novi Sad, Faculty of Medicine Novi Sad²
 University Clinical Center of Vojvodina, Department of Pathology, Novi Sad³

Case report
Prikaz slučaja
 UDK 616.61-006-091.8
<https://doi.org/10.2298/MPNS2310292G>

RENAL LEIOMYOMA – CASE REPORT AND LITERATURE REVIEW

LEJOMIOM BUBREGA – PRIKAZ SLUČAJA I PREGLED LITERATURE

Dragan GRBIĆ¹, Đorđe FILIPOVIĆ¹, Saša VOJINOV^{1,2}, Filip DOŽIĆ¹,
 Tanja LAKIĆ^{2,3} and Željka PANIĆ^{2,3}

Summary

Introduction. Leiomyoma is a mesenchymal benign tumor that seldom manifests in the kidney. Typically, these tumors are small, asymptomatic, and often detected accidentally. Differentiating leiomyomas radiologically from other renal neoplasms, particularly renal cell carcinomas, poses a considerable challenge before surgical intervention. Moreover, the conclusive diagnosis of leiomyomas can only be established through histopathological and immunohistochemical evaluation following surgical intervention. **Case Report.** We present a case of a 44-year-old woman who was diagnosed with right kidney leiomyoma accidentally during a computed tomography examination following exploratory curettage by a gynecologist. An enhanced computed tomography scan revealed a 10 mm tumor located on the upper pole of the right kidney, extending beyond its boundaries. The imaging differential diagnosis was renal cell carcinoma of the right kidney. A laparoscopic partial nephrectomy was performed. Macroscopically, the tumor appeared subcapsular, well-defined, with a firm consistency and a tan-white whorled cut surface. The histological characteristics and the supporting immunohistochemical profile confirmed the diagnosis of renal leiomyoma. The postoperative course was uneventful, and the patient was discharged on the 3rd postoperative day. **Conclusion.** Leiomyomas are rare kidney tumors. A conclusive diagnosis is established through histopathological findings. The pre-operative differentiation of leiomyomas radiologically from other renal neoplasms, particularly renal cell carcinomas, poses a considerable challenge in radiological assessment.

Key words: Leiomyoma; Kidney Neoplasms; Diagnosis, Differential; Tomography, X-Ray Computed; Nephrectomy; Morphological and Microscopic Findings

Introduction

Leiomyomas are benign mesenchymal tumors that seldom manifest in the kidney. Typically, these tumors are asymptomatic, tiny, and often detected by accident. Large renal leiomyomas are uncommon but may manifest as abdominal mass or pain. Differentiating leiomyomas radiologically from other renal neoplasms, particularly renal cell carcinomas, prior to surgery is challenging. Unenhanced computed tomography (CT) scans may show common imaging characteristics such

Sažetak

Uvod. Lejomiom je benigni tumor mezenhimalnog porekla koji se retko javlja u bubregu. Ovi tumori su generalno mali, asimptomatski i najčešće se otkrivaju akcidentalno. Veliki je izazov radiološki razlikovati lejomiome od drugih bubrežnih neoplazmi pre operacije, posebno karcinoma bubrežnih ćelija. Konačna dijagnoza lejomioma može se postići samo histopatološkom i imunohistohemijskom evaluacijom nakon hirurške intervencije. **Prikaz slučaja.** Prikazan je slučaj pacijentkinje stare 44 godine, kod koje je kompjuterizovanom tomografijom rađenom nakon ginekološke intervencije, akcidentalno otkriven lejomiom desnog bubrega. Na kompjuterizovanoj tomografiji opisana je tumorska masa veličine 10 mm na gornjem polu izvan kontura desnog bubrega. Diferencijalna dijagnoza je bila karcinom bubrežnih ćelija. Urađena je laparoskopjska parcijalna nefrektomija. Makroskopski, tumor je bio supkapsularan, dobro ograničen i čvrste konzistencije. Dijagnoza lejomioma desnog bubrega postavljena je na osnovu histoloških karakteristika i pratećeg imunohistohemijskog profila. Postoperativni tok je protekao bez komplikacija, a bolesnica je otpuštena trećeg postoperativnog dana. **Zaključak.** Lejomiomi predstavljaju retke tumore bubrega. Definitivna dijagnoza postavlja se isključivo patohistološkim nalazom. Veoma je teško radiološki razlikovati lejomiom od drugih tipova tumora preoperativno, naročito od karcinoma bubrežnih ćelija.

KLjučne reči: lejomiom; neoplazme bubrega; diferencijalna dijagnoza; CT; nefrektomija; morfološki i mikroskopski nalazi

as hyperattenuation, peripheral placement, and well-defined margins. The definitive confirmation of leiomyoma diagnosis is only possible through histopathological and immunohistochemical evaluation following surgical intervention [1, 2].

Case Report

In our case, the patient was an asymptomatic 44-year-old woman who was accidentally diagnosed with a solid renal mass during the follow-up CT scan

Abbreviations

CT – computed tomography
SMA – smooth muscle actin

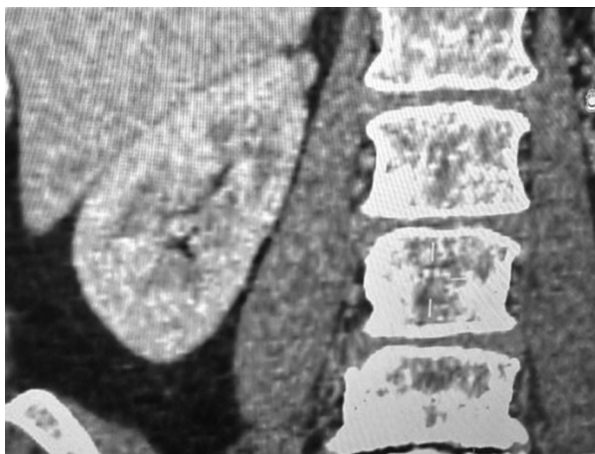

Figure 1. Renal mass on the upper pole, contrast-enhanced CT scan

Slika 1. Bubrežna masa na gornjem polu, kompjuterizovana tomografija sa kontrastom

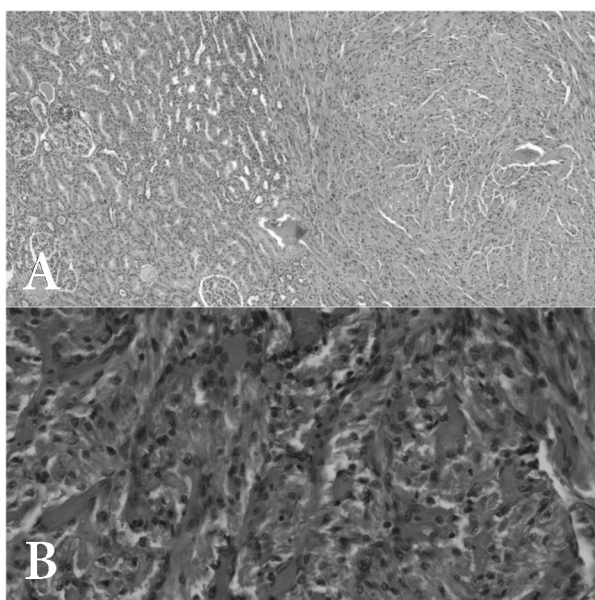


Figure 2. Hematoxylin eosin, 5x (A), Hematoxylin eosin, 20x (B)

Slika 2. Hematoksilin-eozin, 5 x (A), Hematoksilin-eozin, 20 x (B)

after exploratory curettage by a gynecologist. The enhanced CT scan revealed a 10 mm tumor on the upper pole of the right kidney that extended beyond its boundaries (**Figure 1**). The imaging differential diagnosis indicated that the patient had renal cell carcinoma of the right kidney. Subsequently, a laparoscopic partial nephrectomy was performed.

Macroscopically, the tumor appeared subcapsular and well-defined, with a firm consistency and a tan-white whorled cut surface. No cystic defects, hemorrhaging, or necrosis were identified. Micro-

scopically, the tumor nodule was surrounded by the renal capsule and compressed renal parenchyma (**Figure 2A**). It was composed of spindle cells arranged in intersecting fascicles and whorls, displaying minimal pleomorphism, elongated blunt-ended nuclei, inconspicuous nucleoli, and tapering eosinophilic cytoplasm, with the presence of moderately abundant collagenized and partly hyalinized stroma (**Figure 2B**). Mitoses and necrosis were not observed. The entire tumor was removed. The cells stained positive for Caldesmon and smooth muscle actin (SMA) (**Figure 3**) and negative for Pancytokeratin, Desmin, MelanA, HMB-45, CD34, and PAX8. The Ki-67 staining demonstrated a very low proliferation rate (<1%). The diagnosis of renal leiomyoma was established based on the histological characteristics and the accompanying immunohistochemical profile.

The patient recovered after surgery without any complications, and she was discharged on the 3rd postoperative day.

Discussion

Leiomyomas are benign mesenchymal tumors that typically originate in smooth muscle-lined hollow organs, usually in the uterus and the gastrointestinal tract. Although uncommon, renal leiomyoma accounts for 4.2% to 5.2% autopsic cases. A 10-year study by the J. B. Brady Urological Institute (Baltimore, MD) involving 1030 nephrectomies revealed that renal leiomyomas constituted 1.5% of benign renal tumors and 0.3% of all treated tumors [2–4]. In a 2015 study analyzing around 4000 renal neoplasms over a 22 years, only four renal leiomyomas were identified, resulting in an incidence of 0.001% [5]. With a 2:1 female predilection, these tumors are usually incidentally discovered in adults, with the mean onset age of 47 years. Limited cases involving pediatric age have been documented [6, 7].

Renal leiomyomas originate from smooth muscle cells in the renal capsule, renal pelvis, or the tunica media layer of renal cortical vascular structures. These tumors manifest as subcapsular, capsular, or subpelvic types. The lower pole of the kidney is the most common site for tumor detection (74%), with an equal incidence in both kidneys [1, 7]. In contrast to previous reports, our patient's mass lesion was located on the upper pole of the kidney.

Renal leiomyomas usually remain asymptomatic until they produce a mass effect. Symptomatic cases are presented with a palpable mass (57%), abdominal/flank pain (53%), and microscopic or gross hematuria in 20% of cases. The average lesion size reported in the literature is 12.3 cm [7, 8]. The current largest renal leiomyoma measures 57.5 cm in diameter and weighs 37.2 kg [9].

The differential diagnosis of renal leiomyoma includes smooth muscle predominant angiomyolipoma, fibroma, oncocytoma, renal cell carcinoma, and leiomyosarcoma [6, 7, 10].

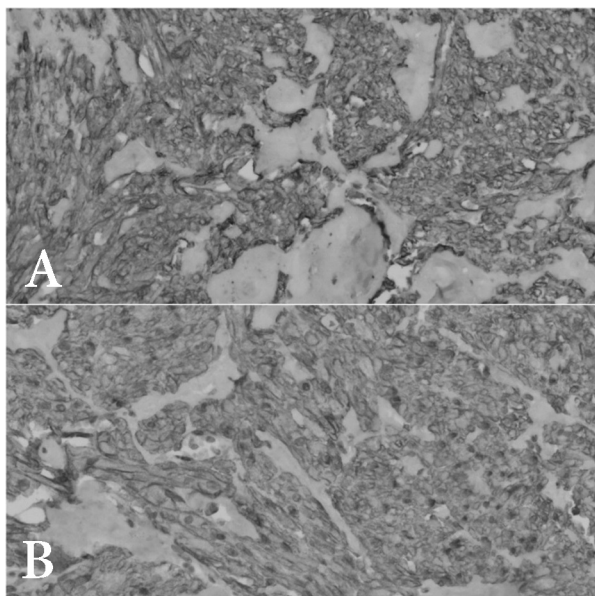


Figure 3. Caldesmon, 20x (A), SMA 20x (B).
Slika 3. Caldesmon, 20x (A), aktin glatkih mišića (SMA) 20x (B)

Renal leiomyomas often appear as solid masses with well-defined boundaries situated in the periphery on CT and magnetic resonance imaging. Large tumors may contain hemorrhagic or cystic degenerative regions, posing an increased risk of malignancy [11]. While radiographic examination does not reveal spe-

cific features for renal leiomyomas, some typical imaging features include clear edges, position on the edge, absence of invasion into nearby tissues, and increased signal intensity unenhanced CT images. A key feature of CT scans aiding in differential diagnosis is density. Before contrast, all studied leiomyomas appeared hyperdense compared to the kidney, with a density similar to that of muscles. After contrast medium injection, the lesions showed less enhancement than the surrounding renal parenchyma [12–14].

The final diagnosis of kidney leiomyomas depends on histopathology, which is usually performed after surgical removal of the tumor. Histologically, renal leiomyomas appear to be made of fusocellular elements, with absence of mitotic figures, pleomorphism, hyperchromatism, and perilesional invasivity. The presence of these conditions is characteristic of leiomyosarcoma [12, 13].

In the majority of documented cases, patients diagnosed with kidney leiomyoma were initially presumed to have renal cell carcinoma and were treated with partial nephrectomy, which is currently considered the gold standard [14].

Conclusion

We presented the case of a 44-year-old woman with renal leiomyoma, which tumor was diagnosed accidentally. As a result of the radiological differential diagnosis of renal cell carcinoma, the tumor was surgically excised. Histopathology of the surgically resected mass confirmed this rare renal tumor – leiomyoma.

References

- Sidhu H, Kamal A. Giant renal leiomyoma: a case report. *Radiol Case Rep.* 2020;15(5):515-8.
- Kamiński P, Nogalski A, Lewkowicz D, Ciecchan J. Leiomyoma as a case of renal tumor. *Urol Case Rep.* 2021;39:101792.
- Andreoiu M, Drachenberg D, Macmahon R. Giant renal leiomyoma: a case report and brief review of the literature. *Can Urol Assoc J.* 2009;3(5):E58-60.
- Aldughiman AW, Alzahrani A, Alzahrani T. Renal leiomyoma: case report and literature review. *J Endourol Case Rep.* 2019;5(4):181-3
- Patil PA, McKenney JK, Trpkov K, Hes O, Montironi R, Scarpelli M, et al. Renal leiomyoma: a contemporary multi-institution study of an infrequent and frequently misclassified neoplasm. *Am J Surg Pathol.* 2015;39(3):349-56.
- Ma W, Jiang H, Zhang Y, Zhang J, Jiang H. Acute abdominal pain induced by renal leiomyoma in a young patient: a case report. *J Int Med Res.* 2021;49(7):3000605211032802.
- Karabulut D, Alkan A, Ozgur C, Gunay B, Burgazdere G, Oz Puyan F. Renal leiomyoma: an uncommon differential diagnosis of renal masses in pediatric age. *Urol Case Rep.* 2021;36:101567.
- Dhawan K, Bansal N, Gupta NM, Dhawan S. Clinical progression of renal vein leiomyoma: a case report. *Int J Surg Case Rep.* 2019;65:249-54.
- Karayil RV, Bhaskarashenoy M, Sukumaran G. Leiomyoma of kidney. *J Kidney Cancer VHL.* 2023;10(2):29-32.
- Hayasaka K, Amoh K, Hashimoto H, Yachiku S. Evaluation of renal and perirenal leiomyoma on US, CT and angiography. *Radiat Med.* 1993;11(3):81-5.
- Katabathina VS, Vikram R, Nagar AM, Tamboli P, Menias CO, Prasad SR. Mesenchymal neoplasms of the kidney in adults: imaging spectrum with radiologic-pathologic correlation. *Radiographics.* 2010;30(6):1525-40.
- Nicolau C, Antunes N, Paño B, Sebastia C. Imaging characterization of renal masses. *Medicina (Kaunas).* 2021;57(1):51.
- Chaniotakis S, Yang Y, Patel T, Banks J. Large renal leiomyoma: a multidisciplinary approach to diagnosis. *J Radiol Case Rep.* 2021;15(8):18-26.
- Brunocilla E, Pultrone CV, Schiavina R, Vagnoni V, Caprara G, Martorana G. Renal leiomyoma: case report and literature review. *Can Urol Assoc J.* 2012;6(2):E87-90.

Rad je primljen 8. I 2024.

Recenziran 14. II 2024.

Prihvaćen za štampu 5. III 2024.

BIBLID.0025-8105:(2023):LXXVI:9-10:292-294.